

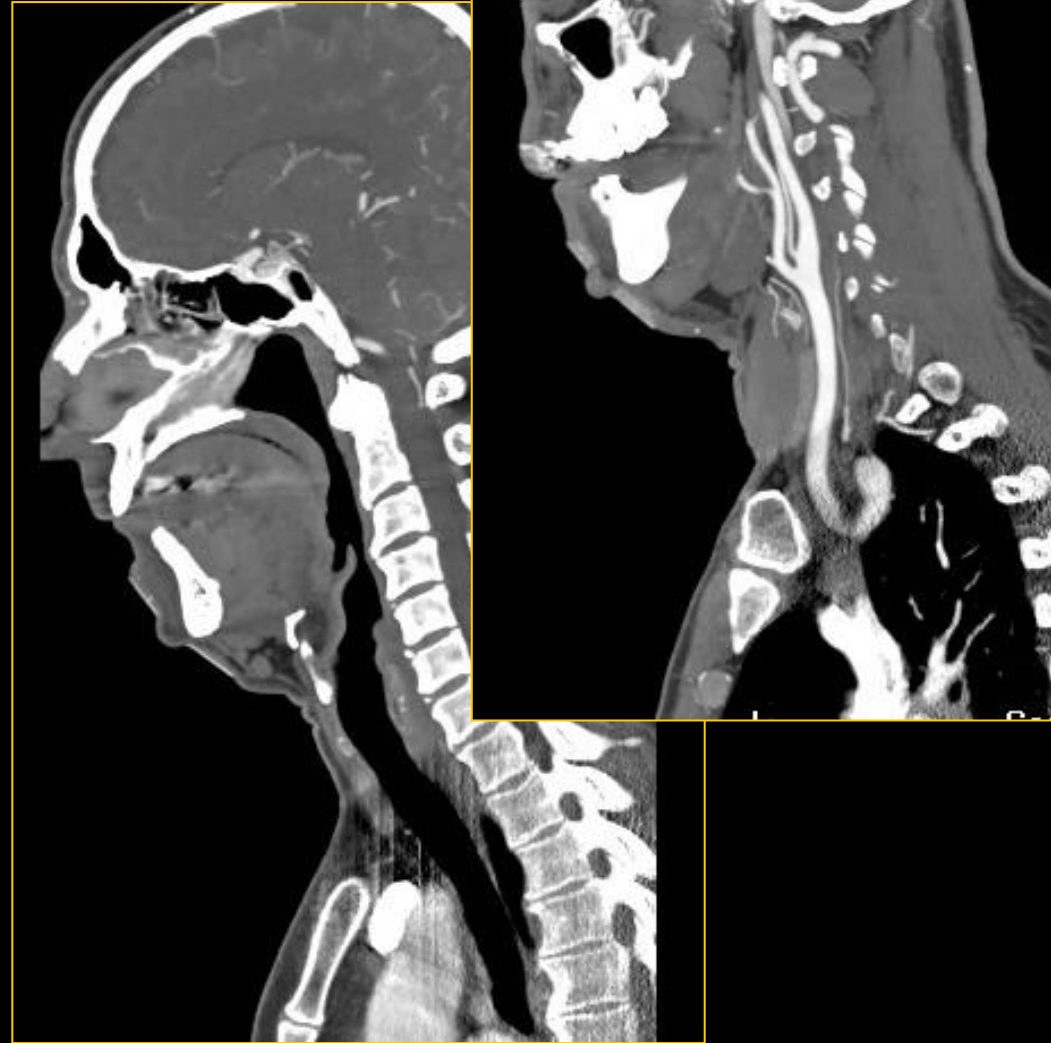# Baş-Boyun BT/MRG kesitsel anatomisi

Prof. Dr. Kamil Karaali  
Akdeniz Üniversitesi  
Tıp Fakültesi  
Radyoloji Ana Bilim Dalı

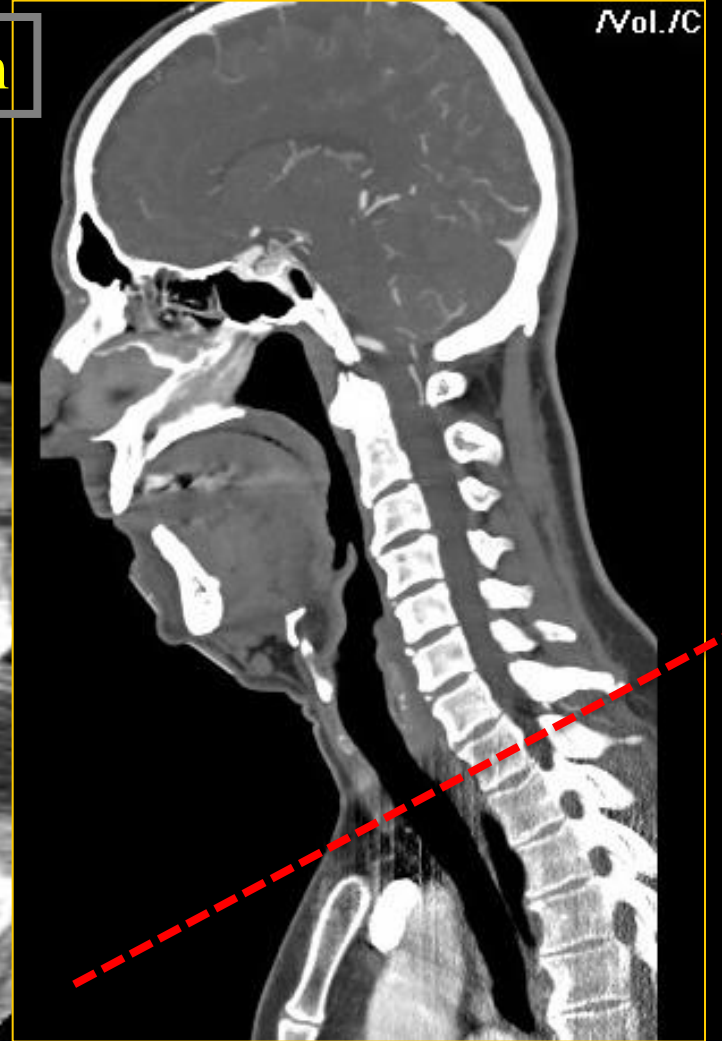
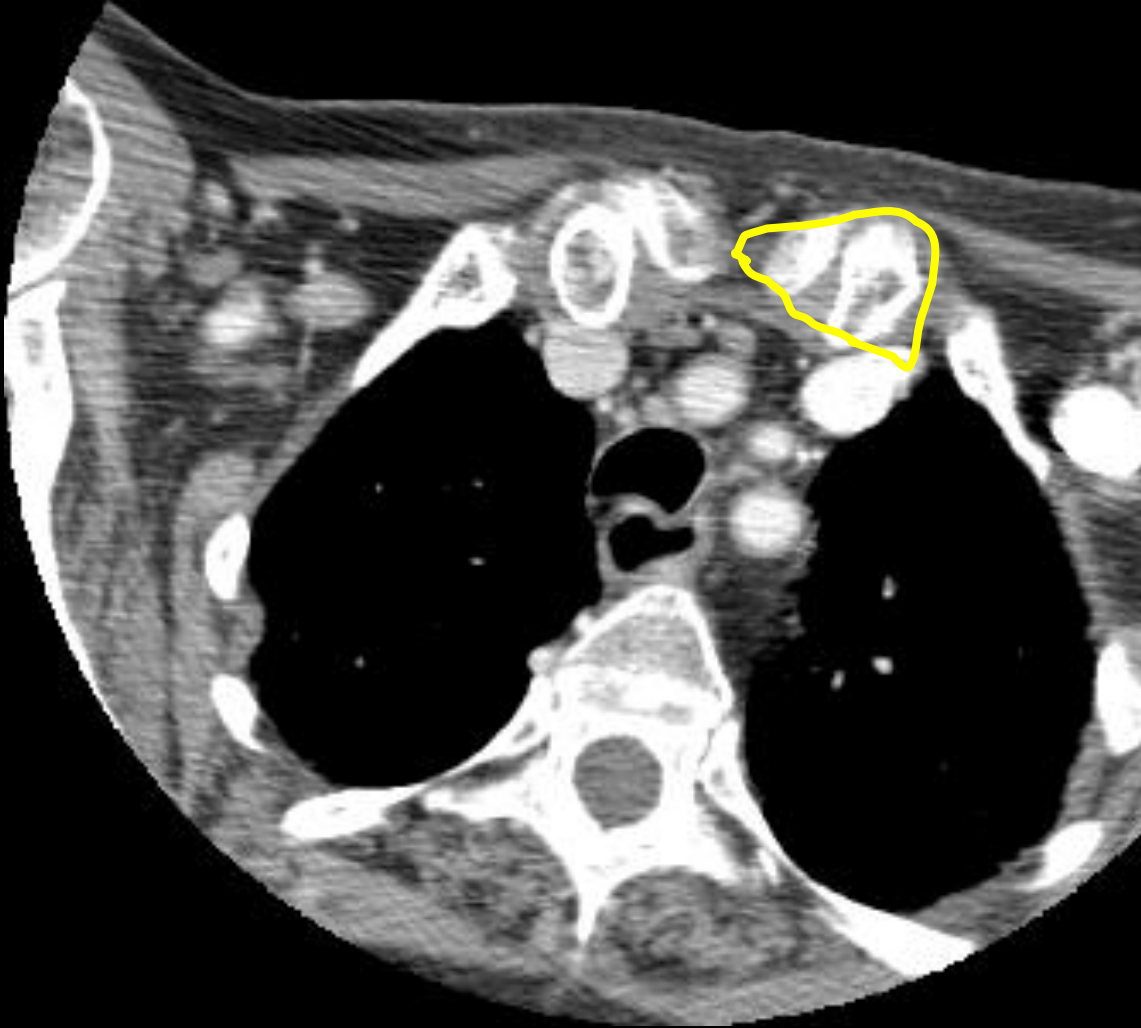- **Boyun**

## Plan

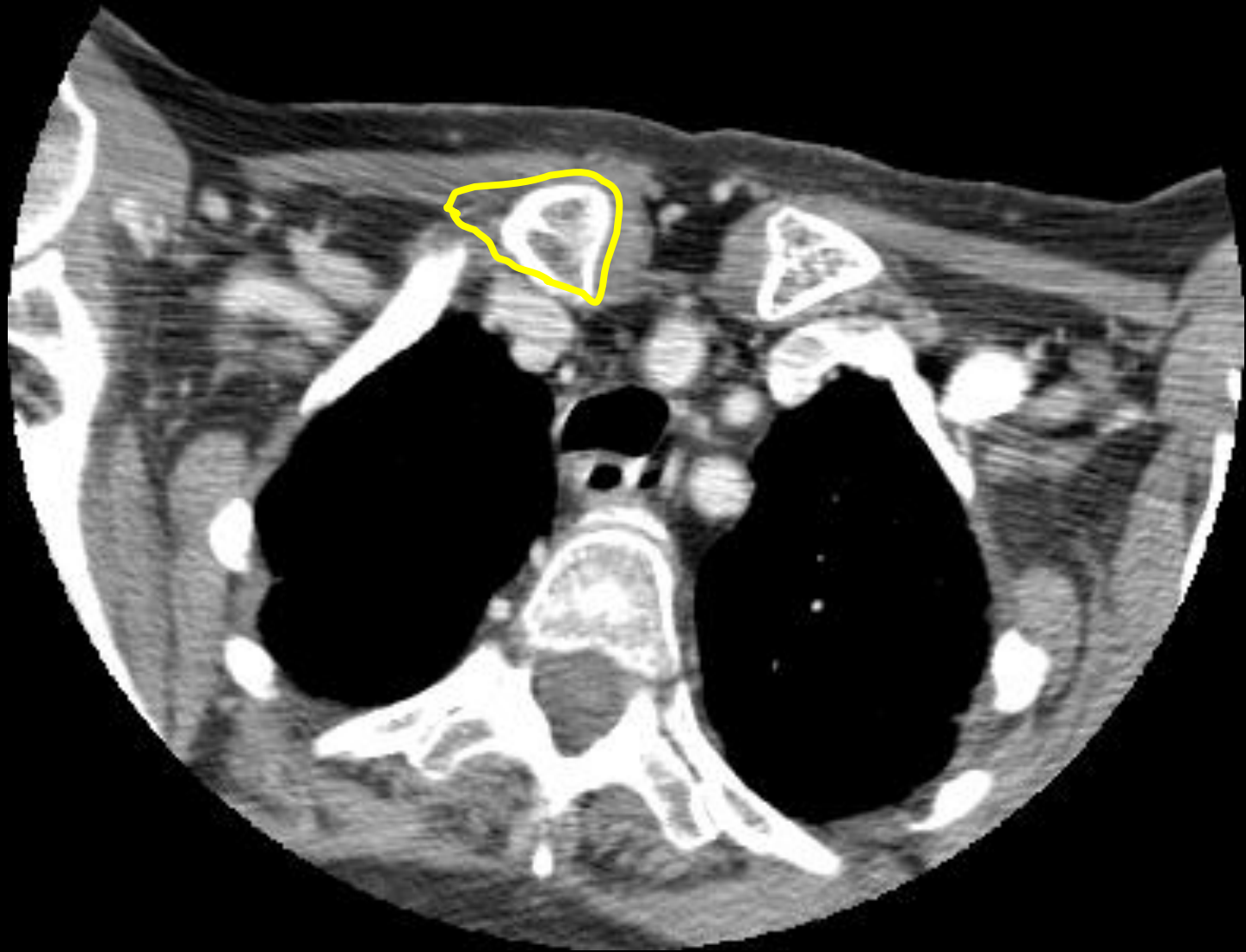
- Vasküler yapılar
- Kaslar
- Bezler
- Larinks
- Orofarinks
- Nazofarinks
- Orbita
- Lenf nodu seviyeleri



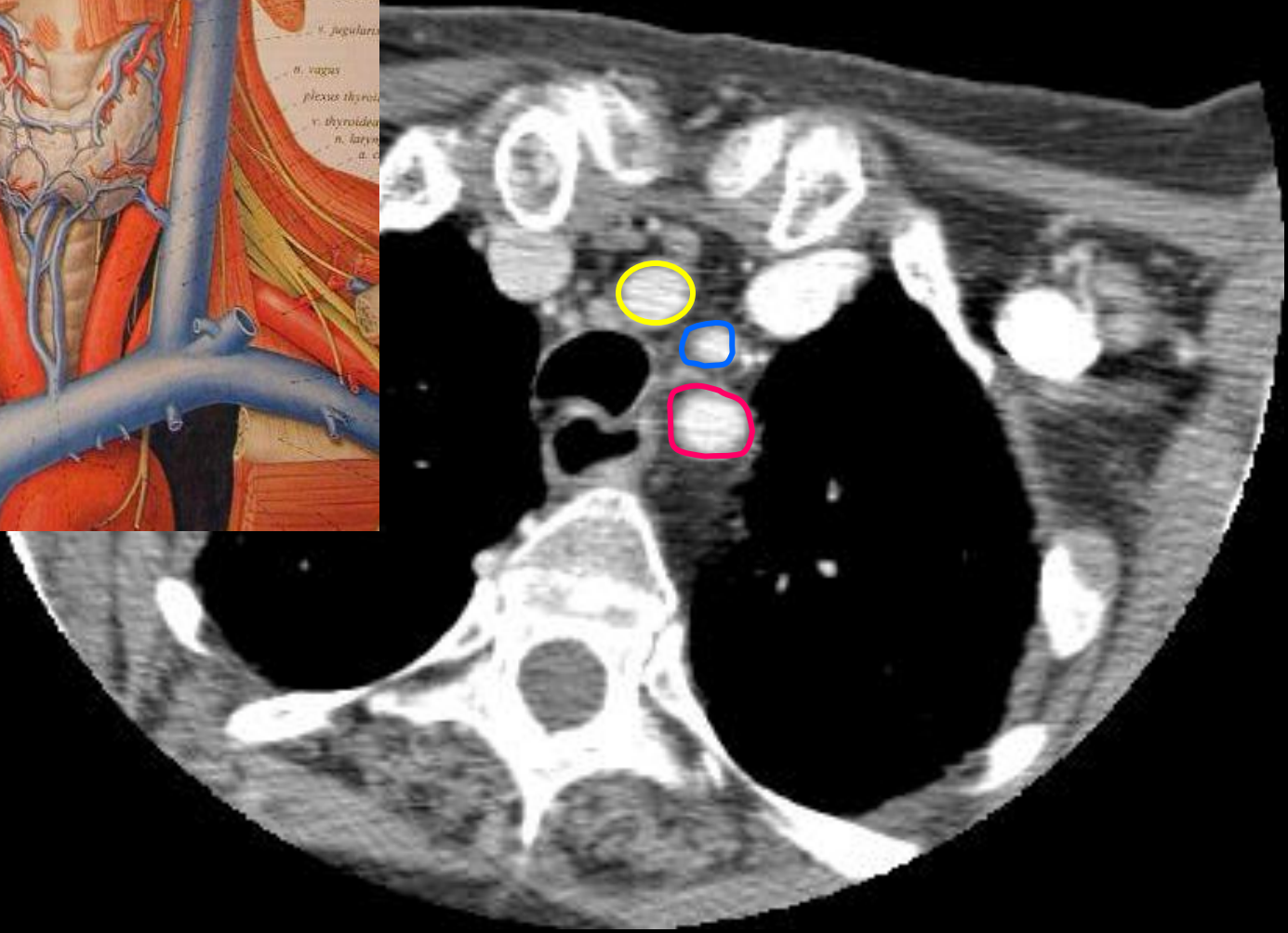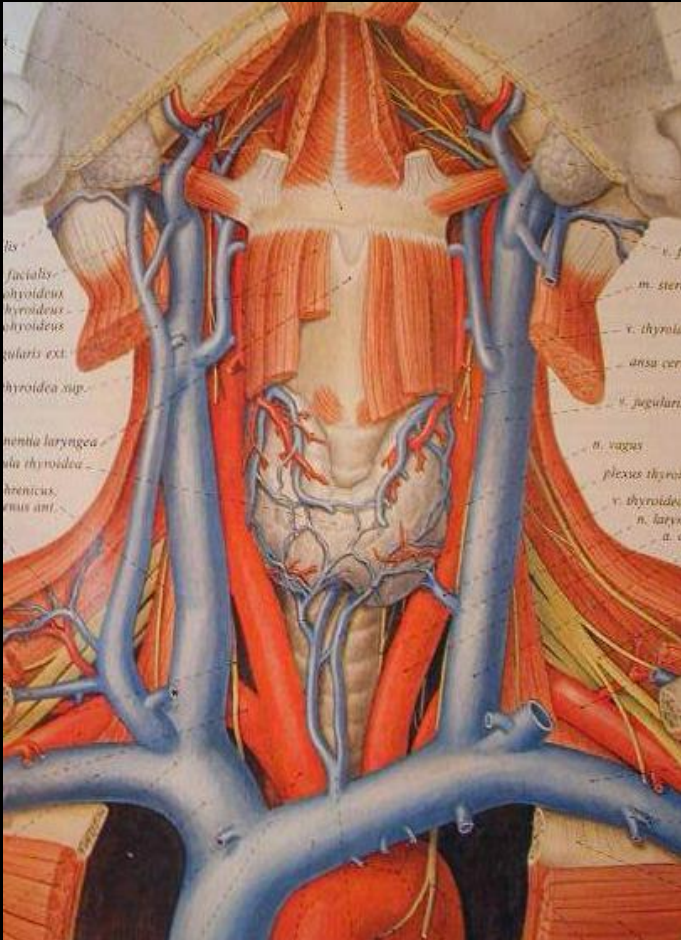
**Klavikula başı / Sternoklaviküler eklem**



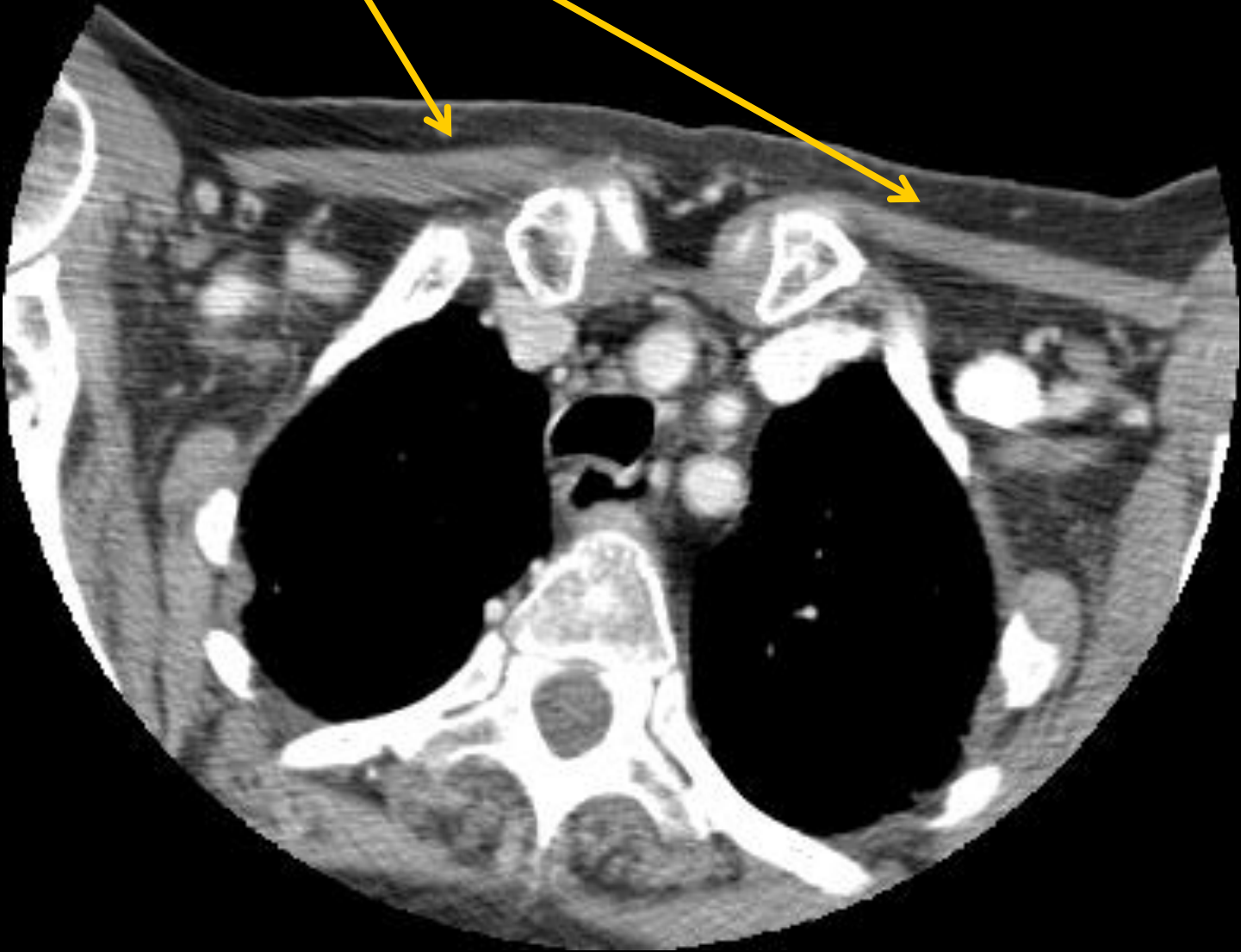
Klavikula başı

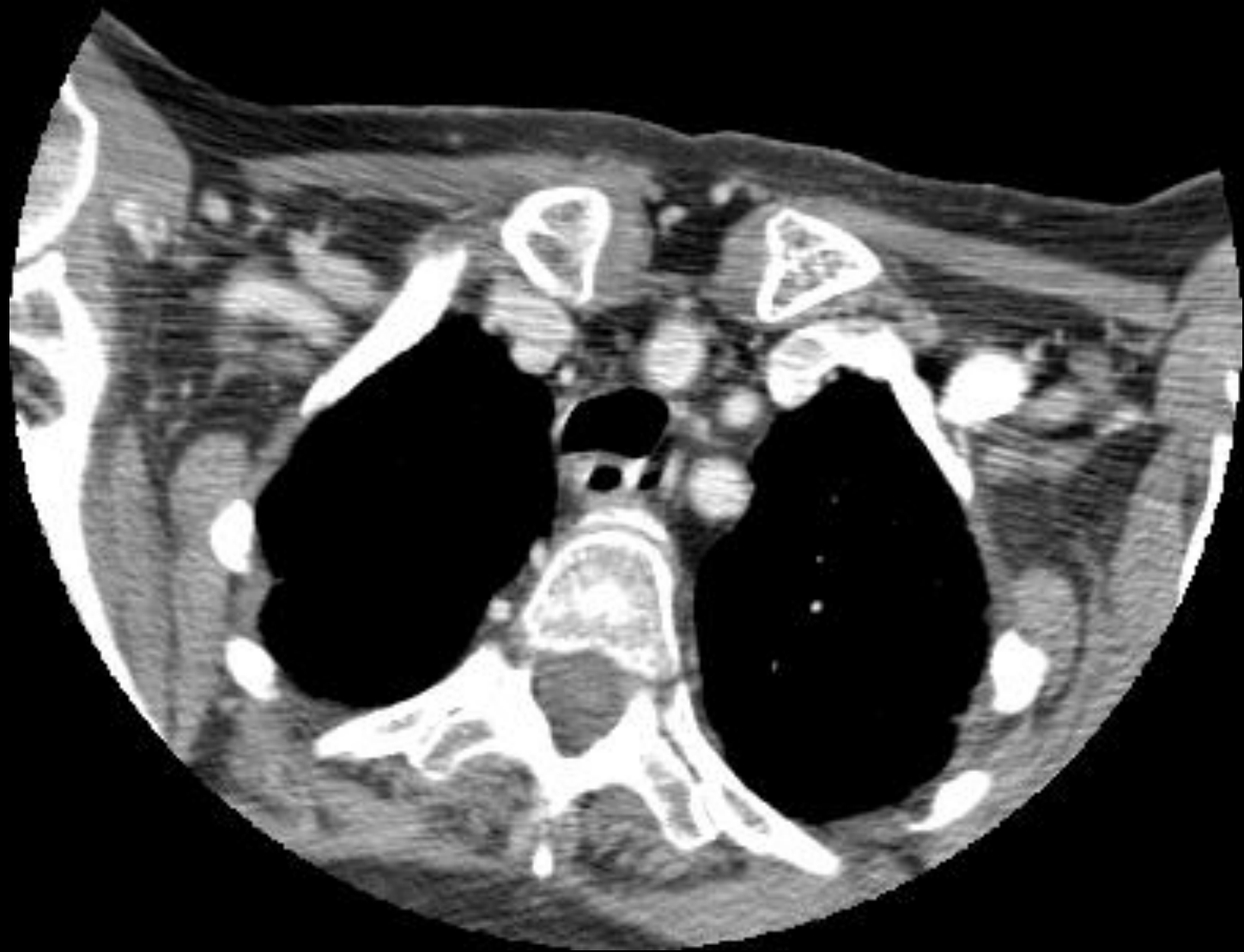

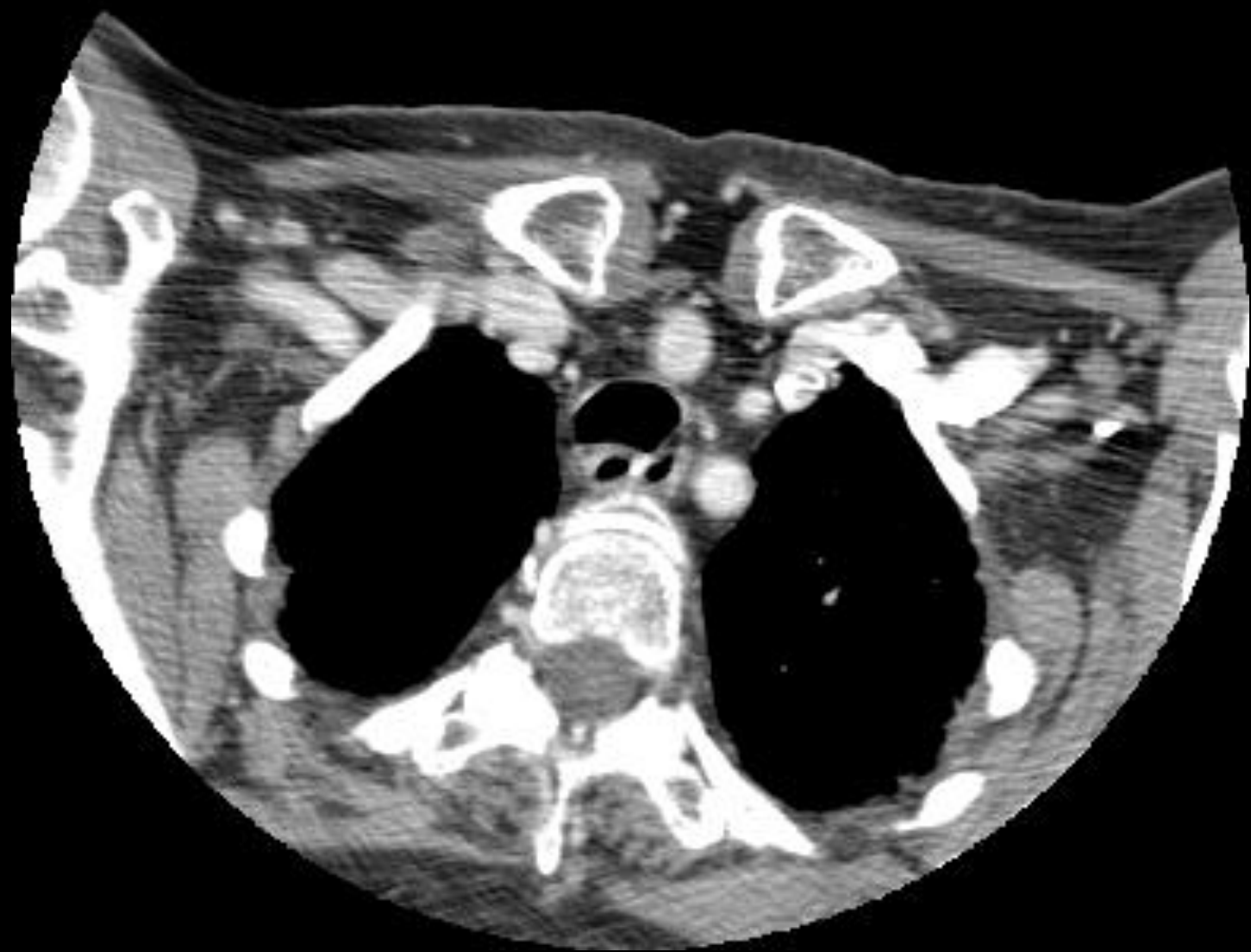**İnnominat arter**  
sol ana karotid arter  
sol subklavyan arter



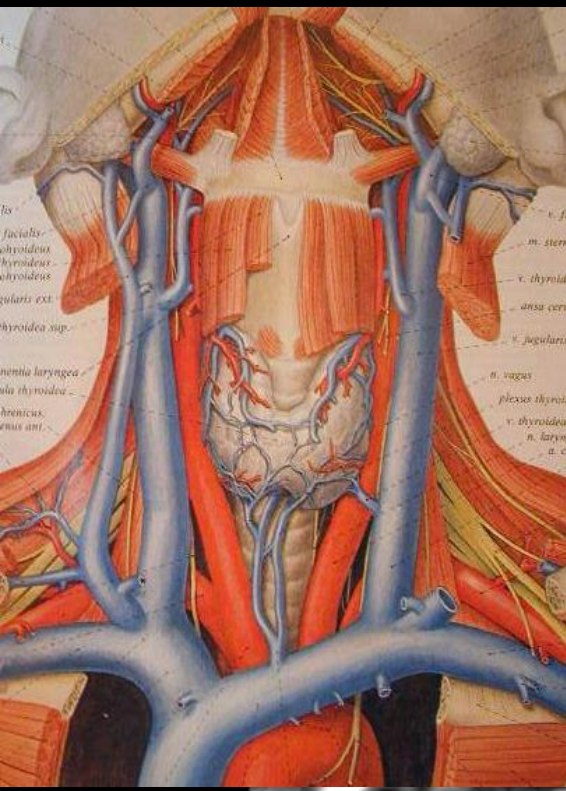
Pectoralis major kası



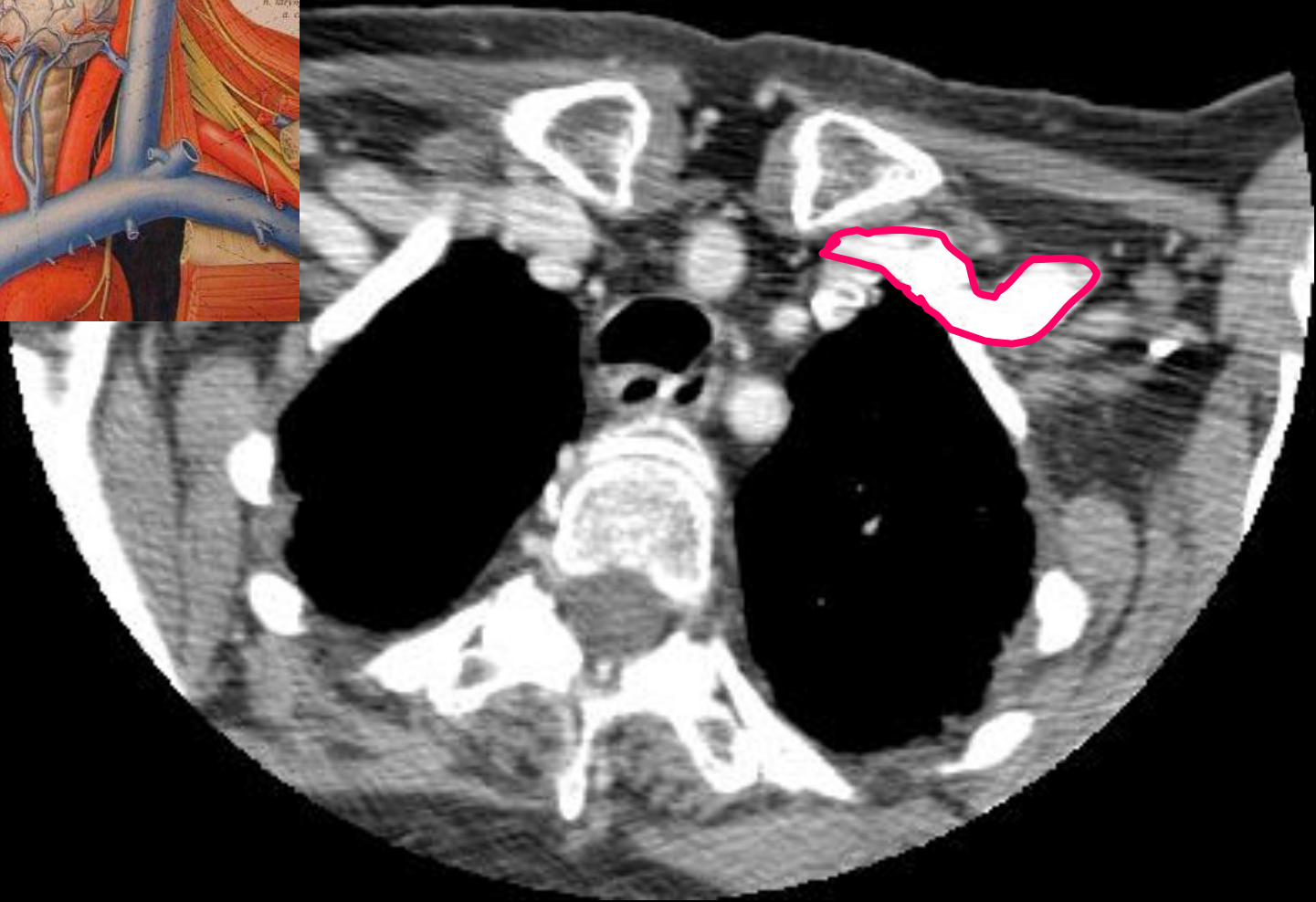




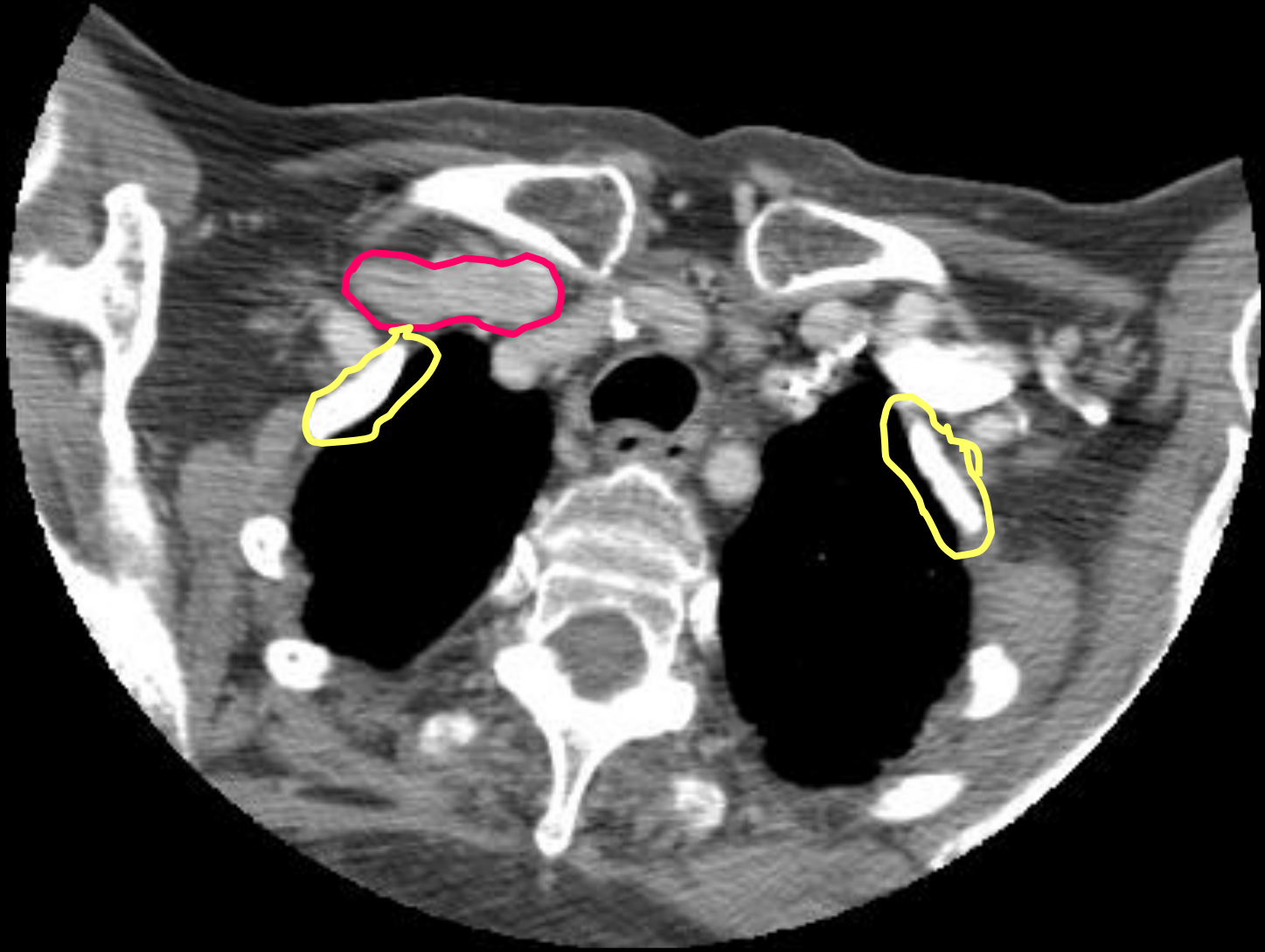



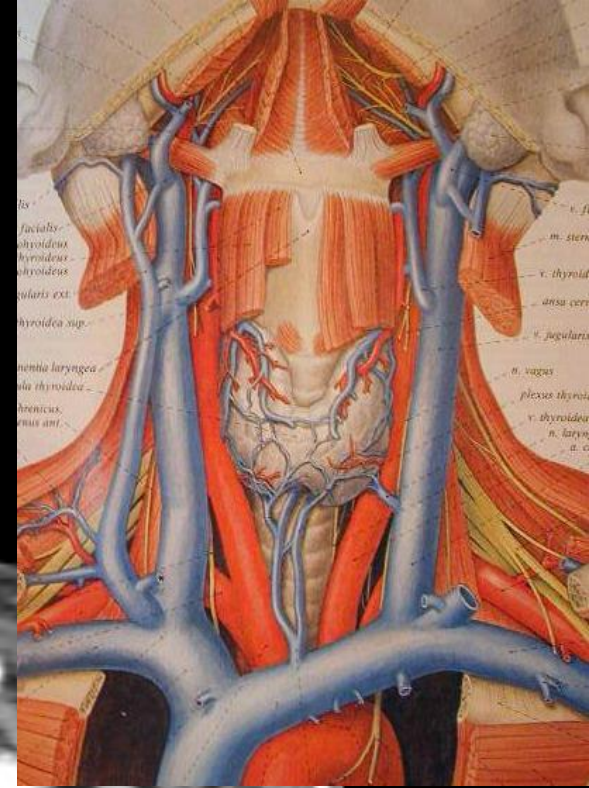
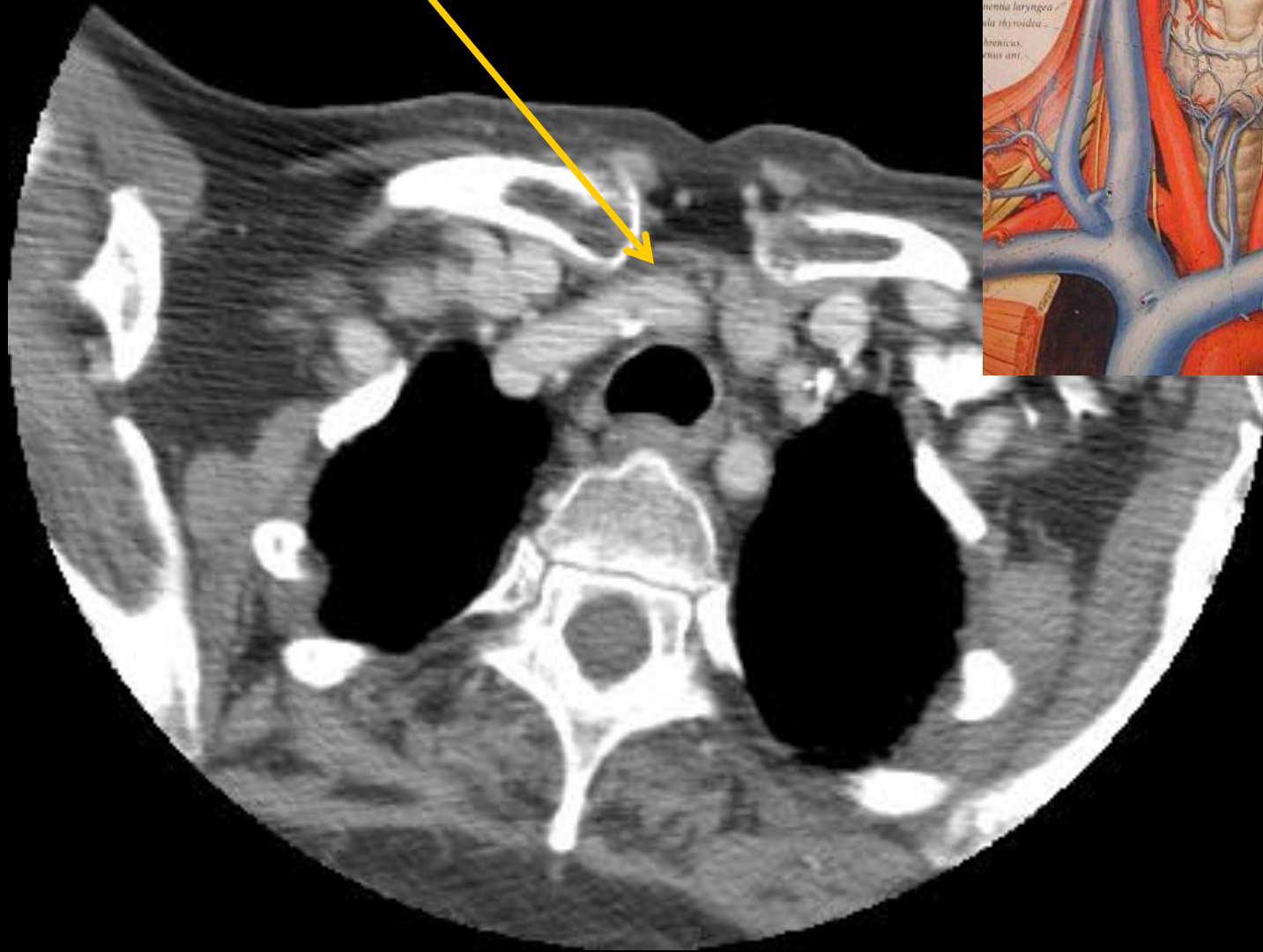
## Sol subklavyan ven (kontrast enjeksiyonu)



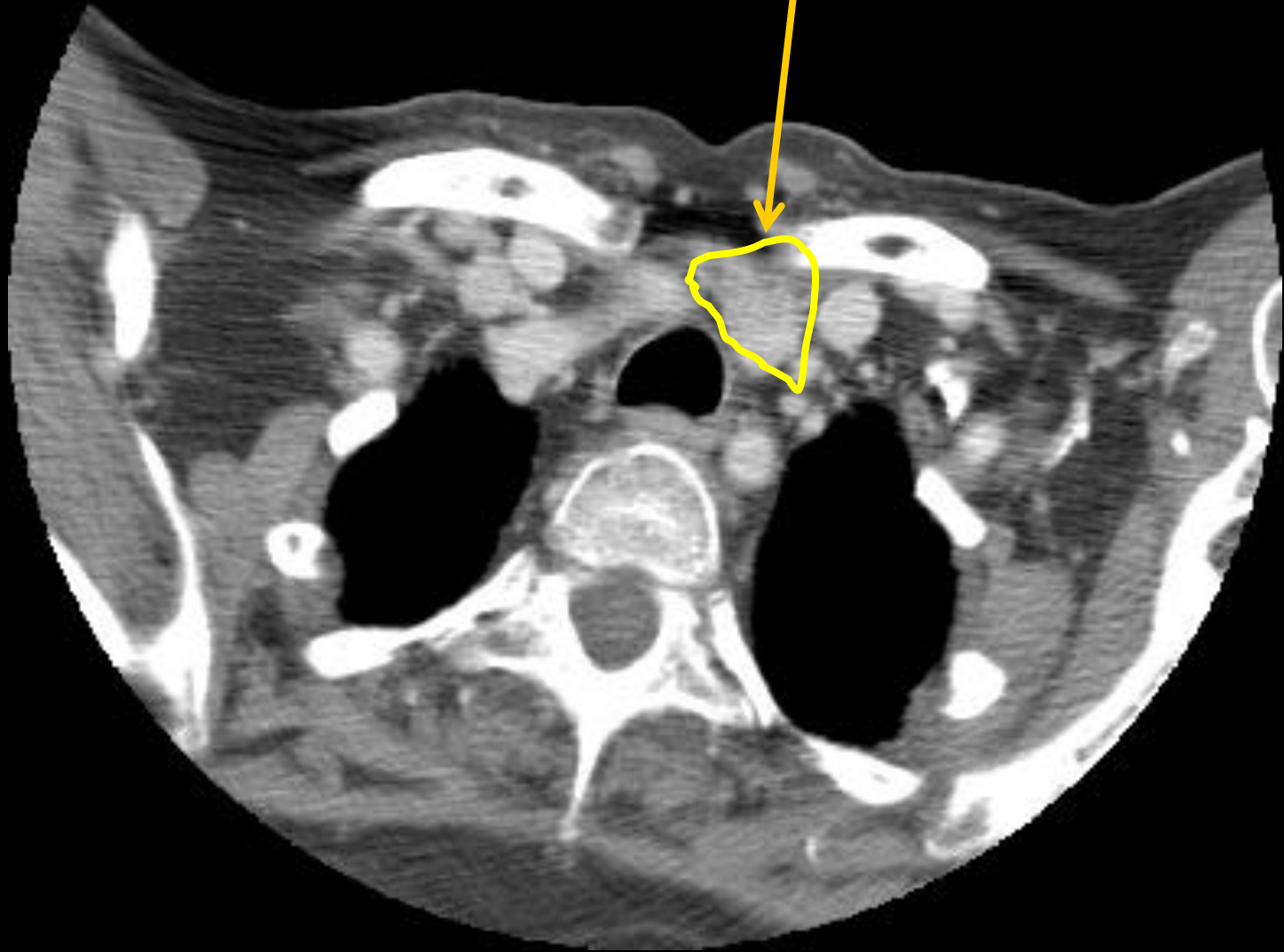
Sağ subklavyan ven  
Kostalar



# İnnominat arter bifurkasyonu

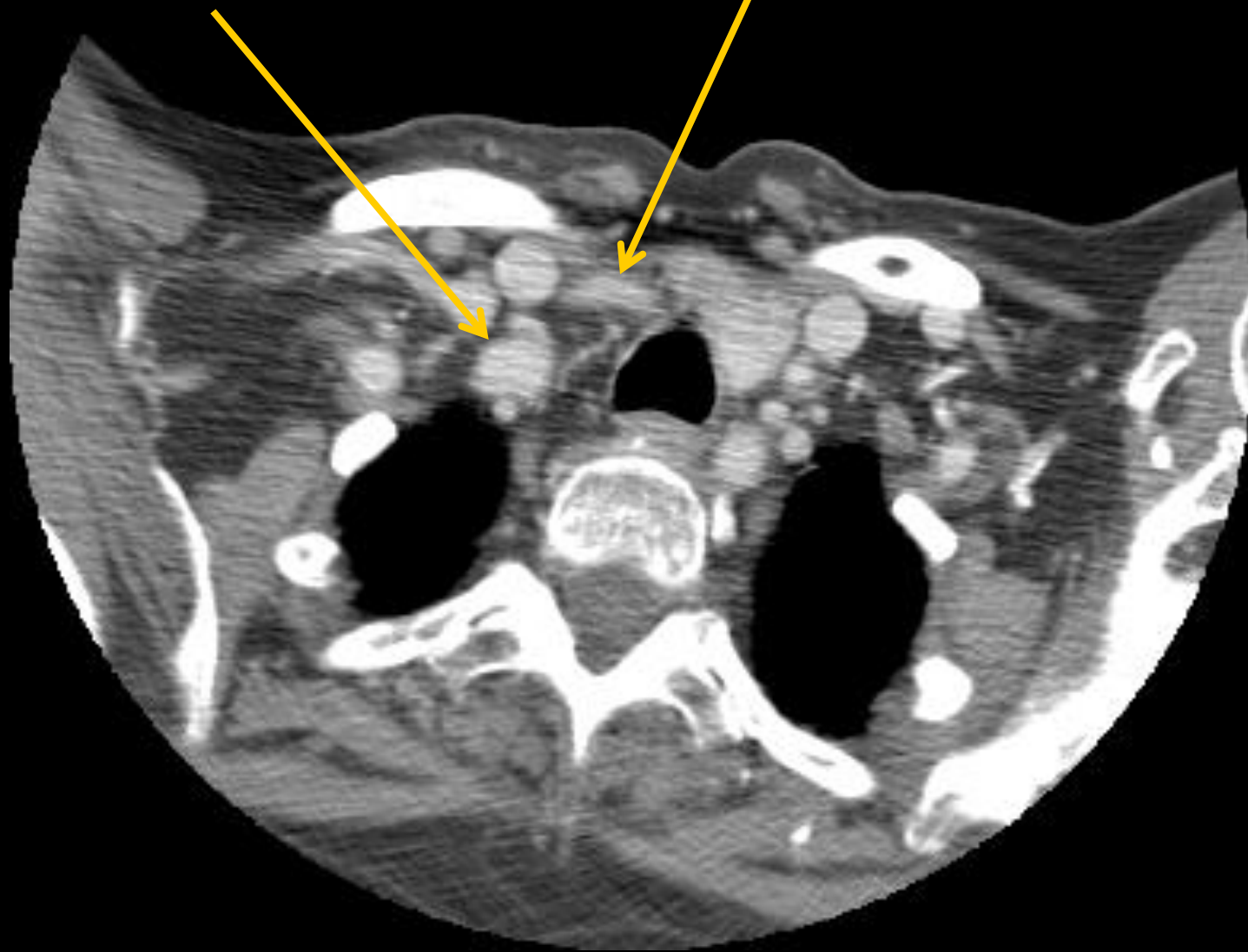


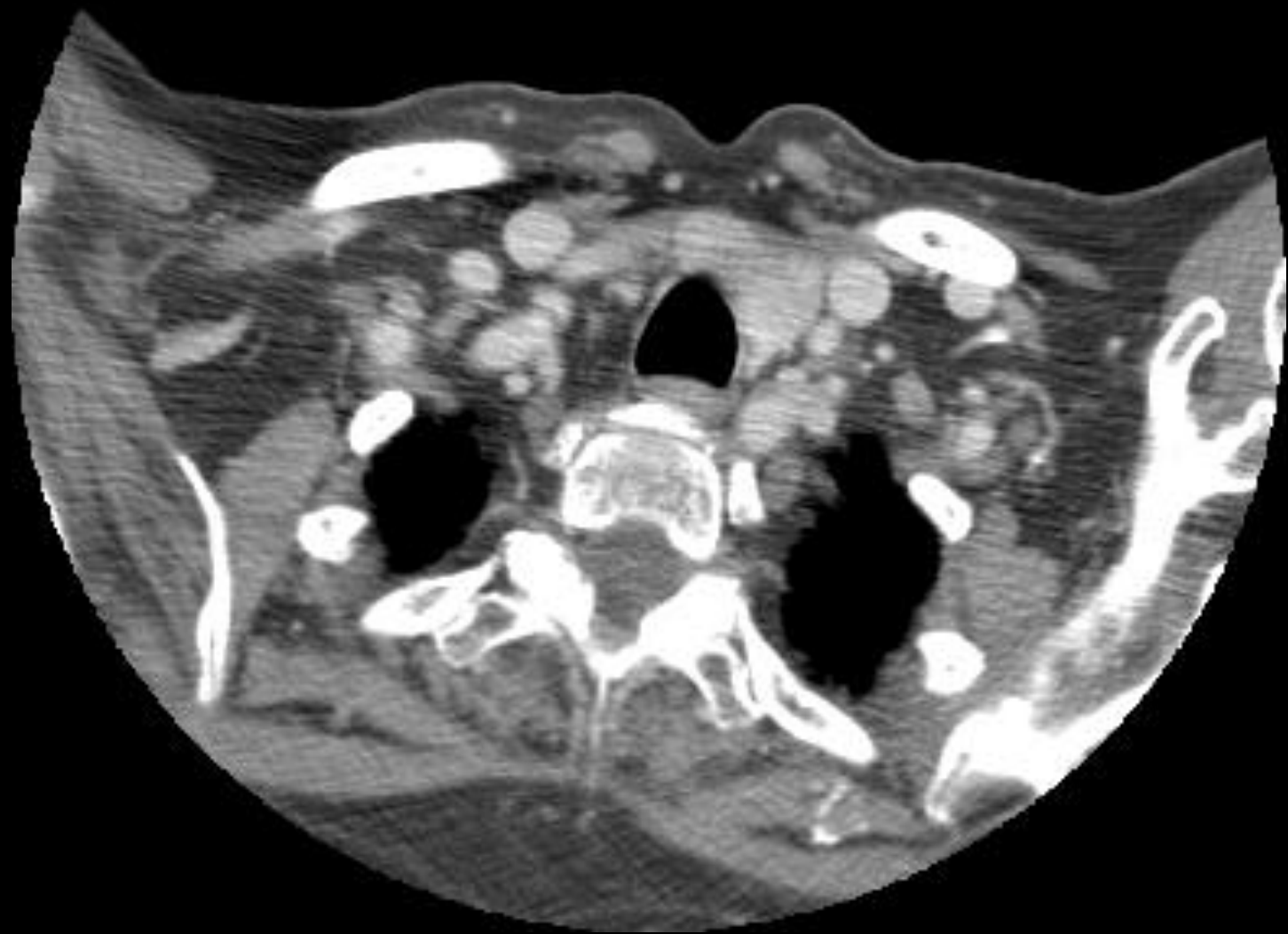
Tiroid sol lobu

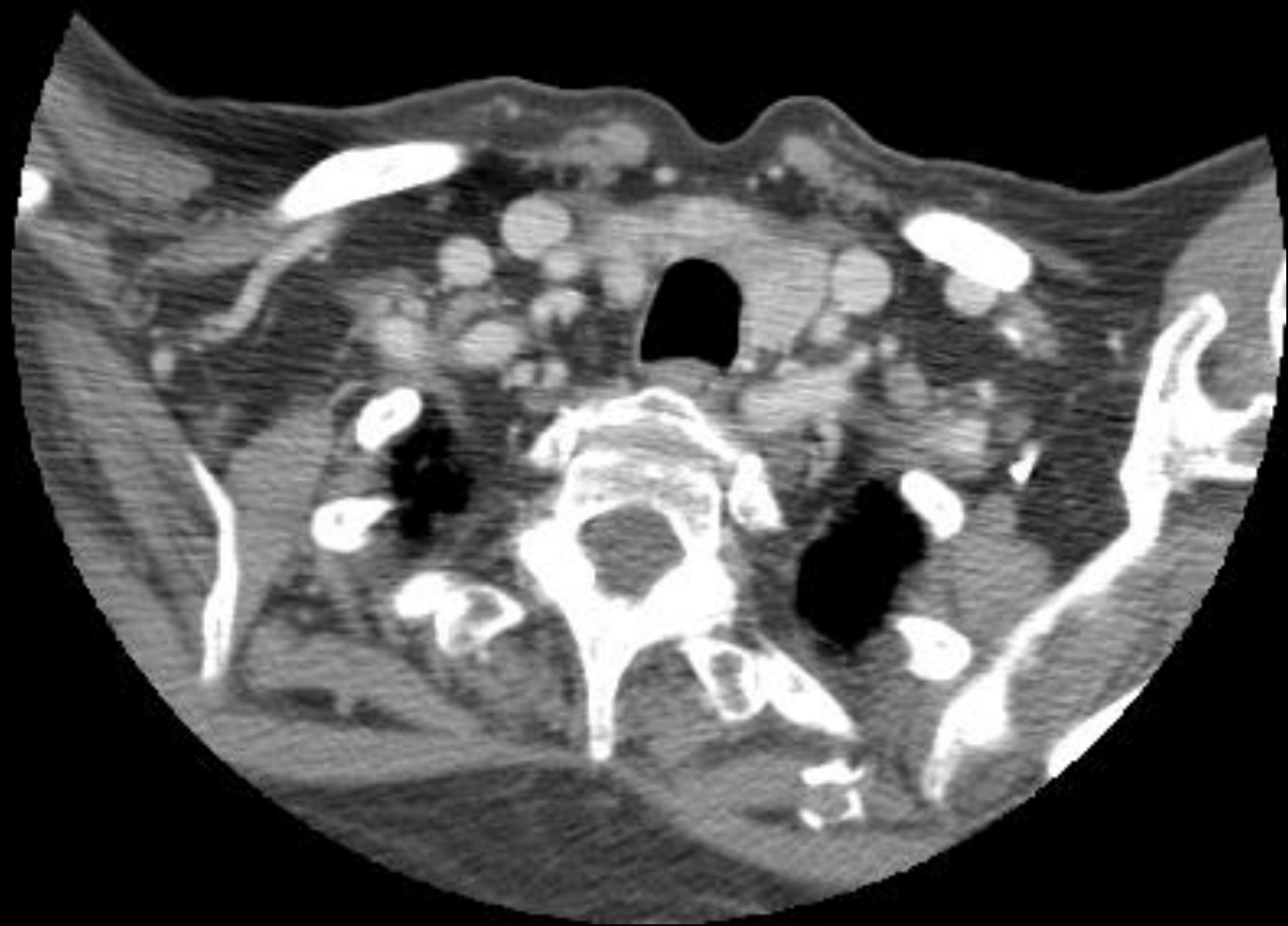


Sağ ana karotid arter

Sağ sublavyan arter

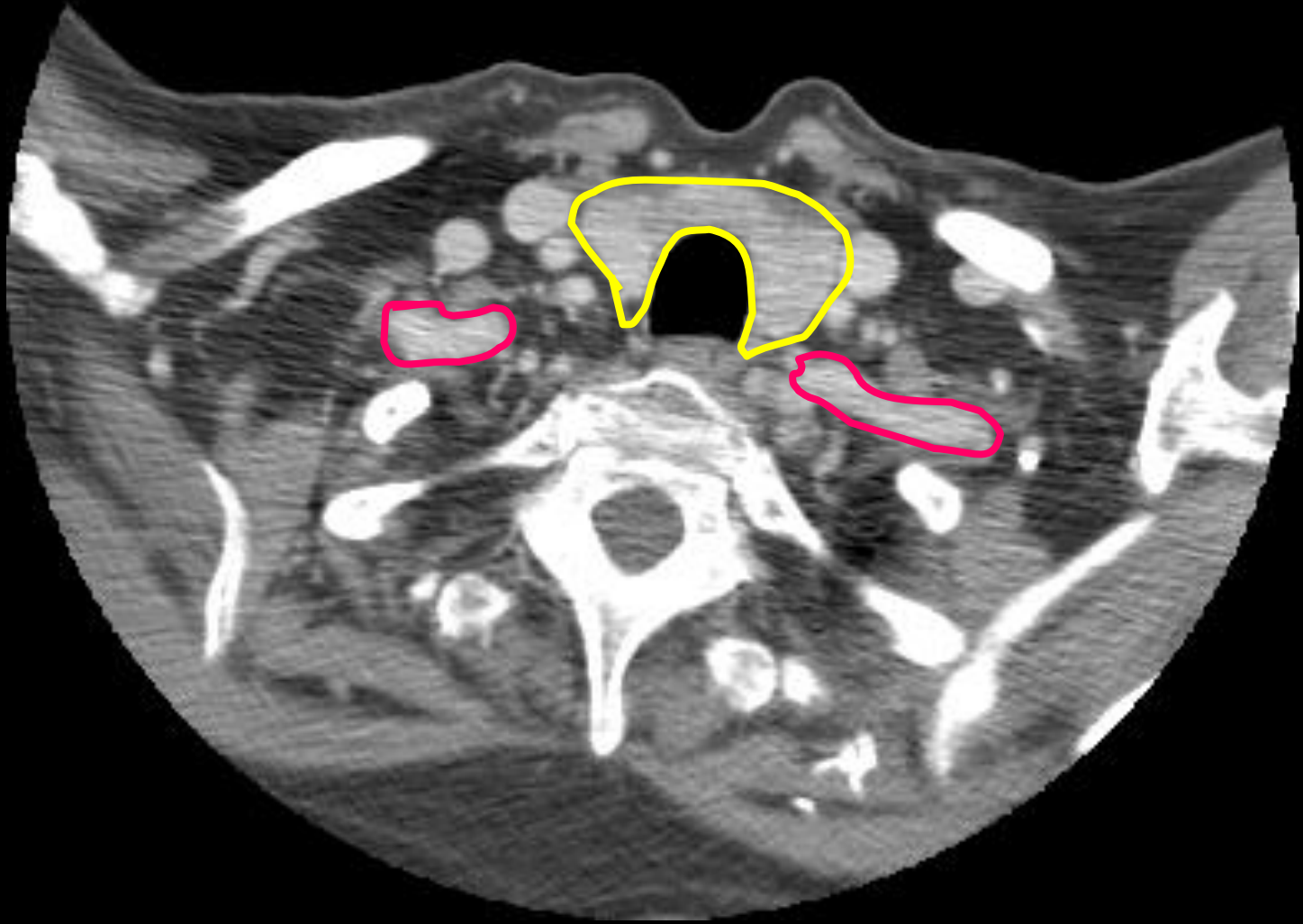





Tiroid bezi

Subklavyan arterler

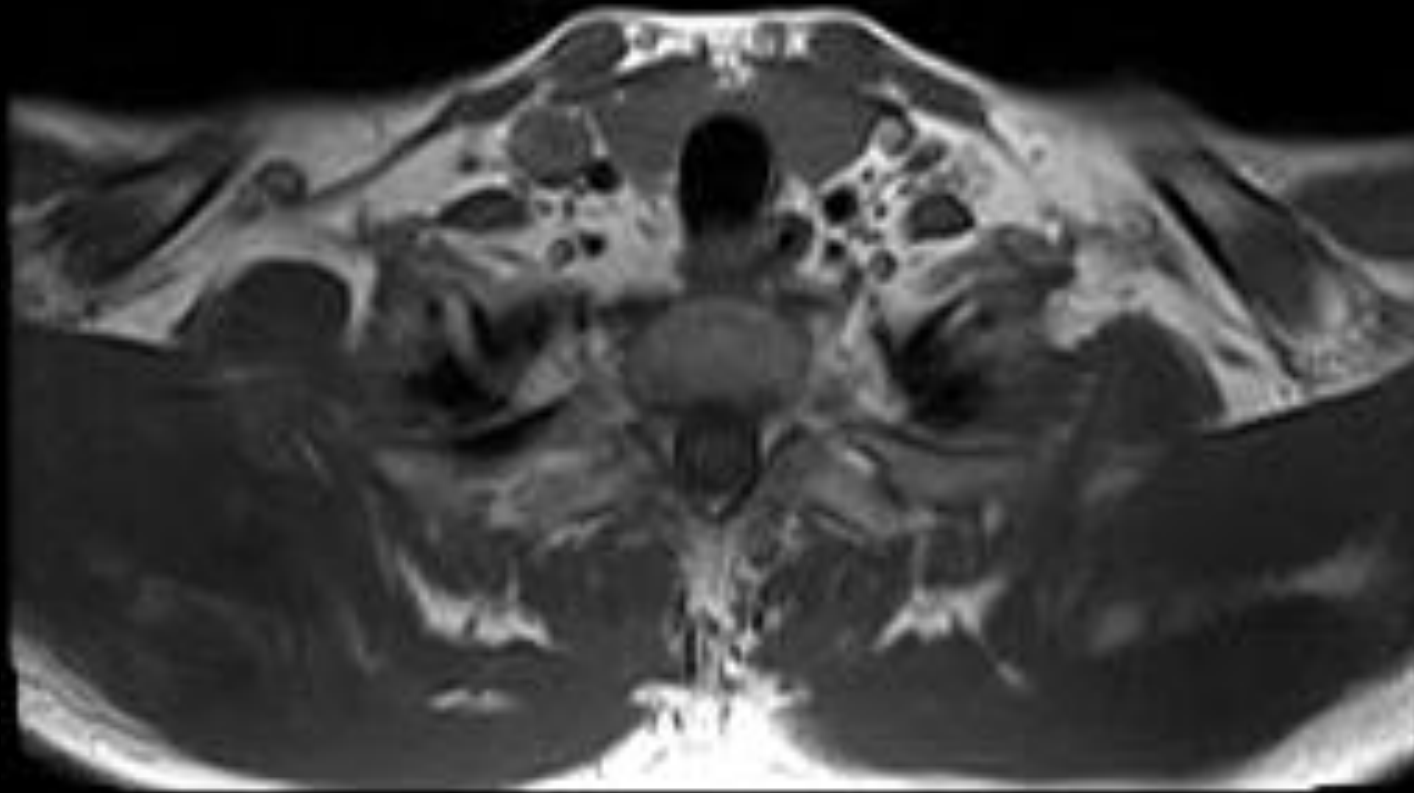




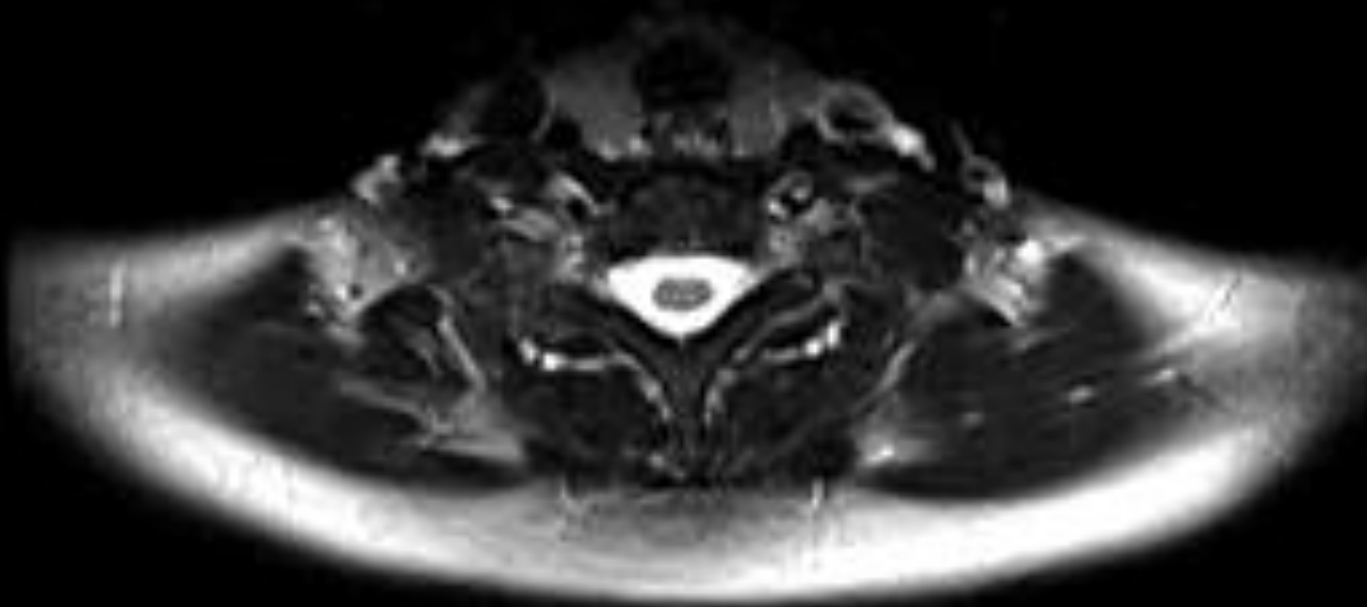
**Tiroid bezi**

**T1-ağırlıklı MR**

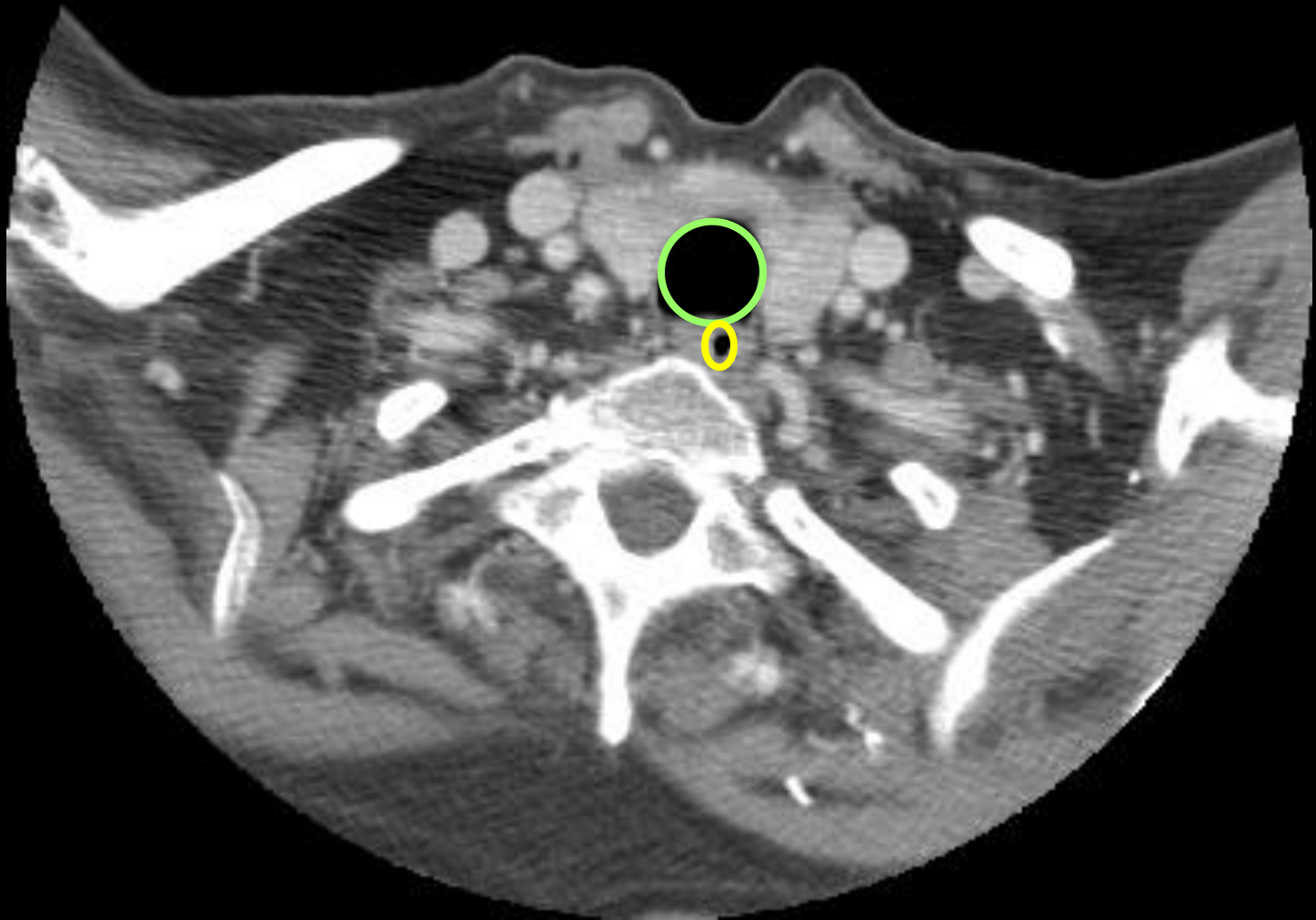
**Transvers kesit**



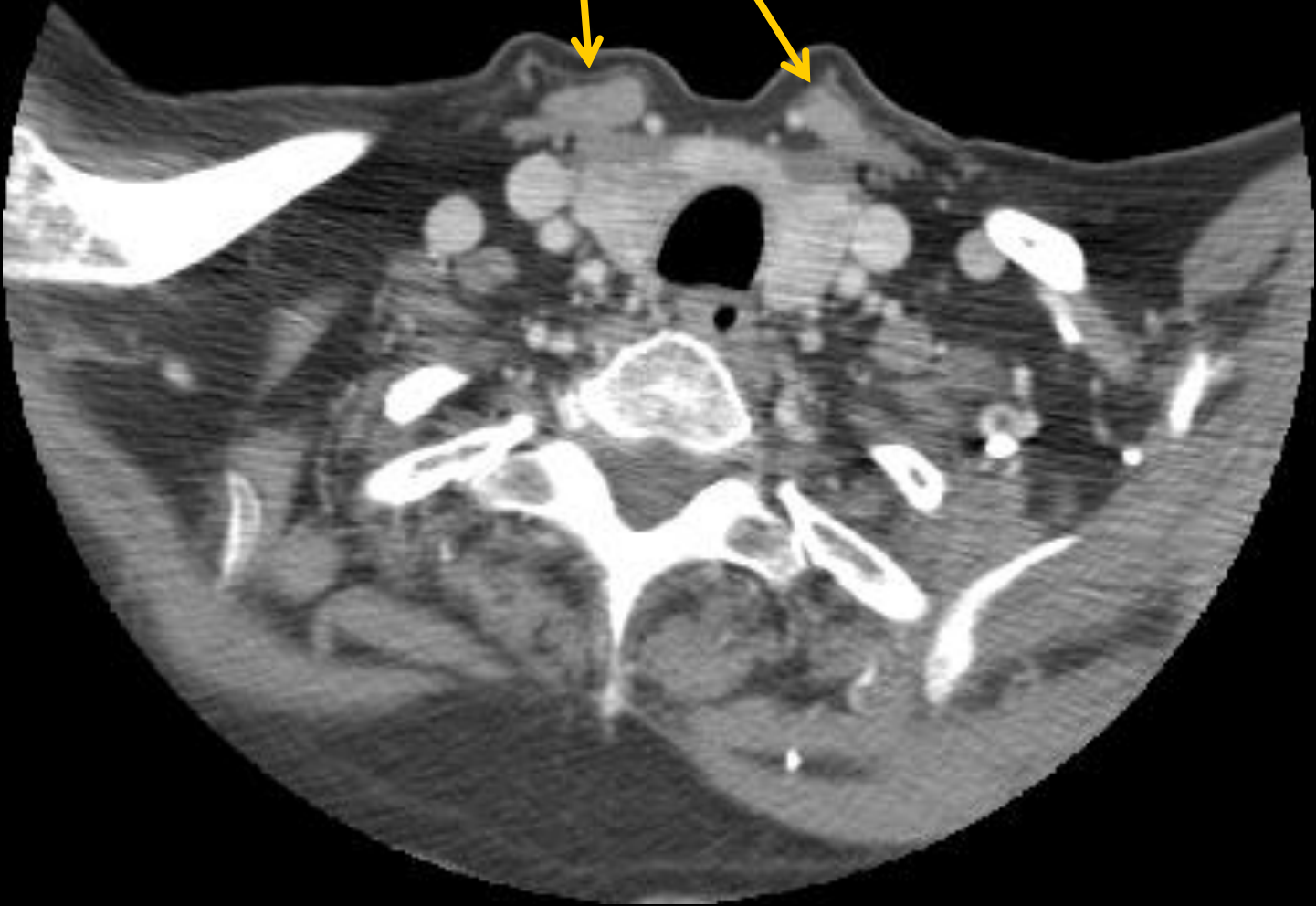
Tiroid bezi / Vasküler yapılar  
T2-ağırlıklı yağ baskılı MR  
Transvers kesit



Trakea  
Özofagus

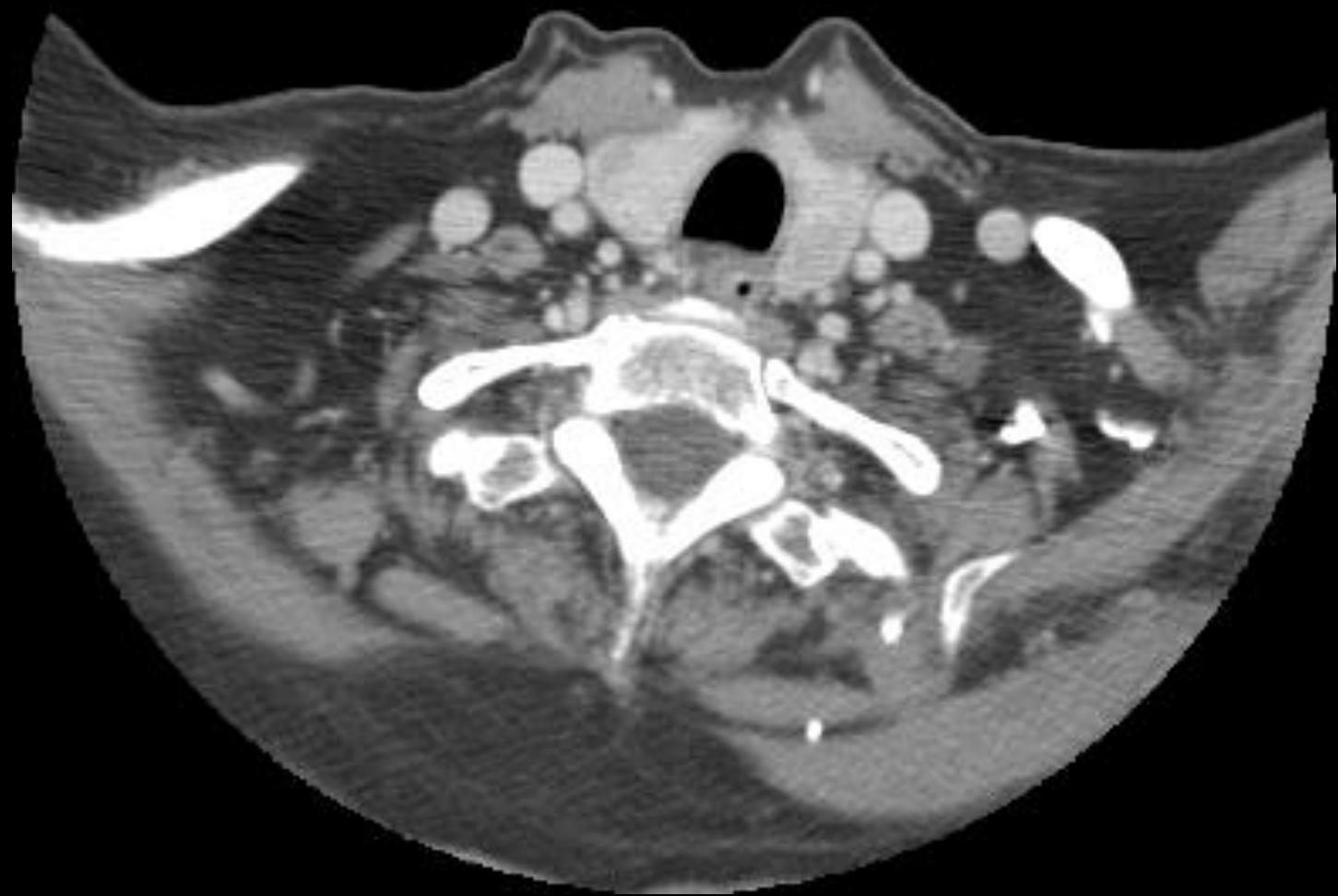


Sternokleidomastoid kasları

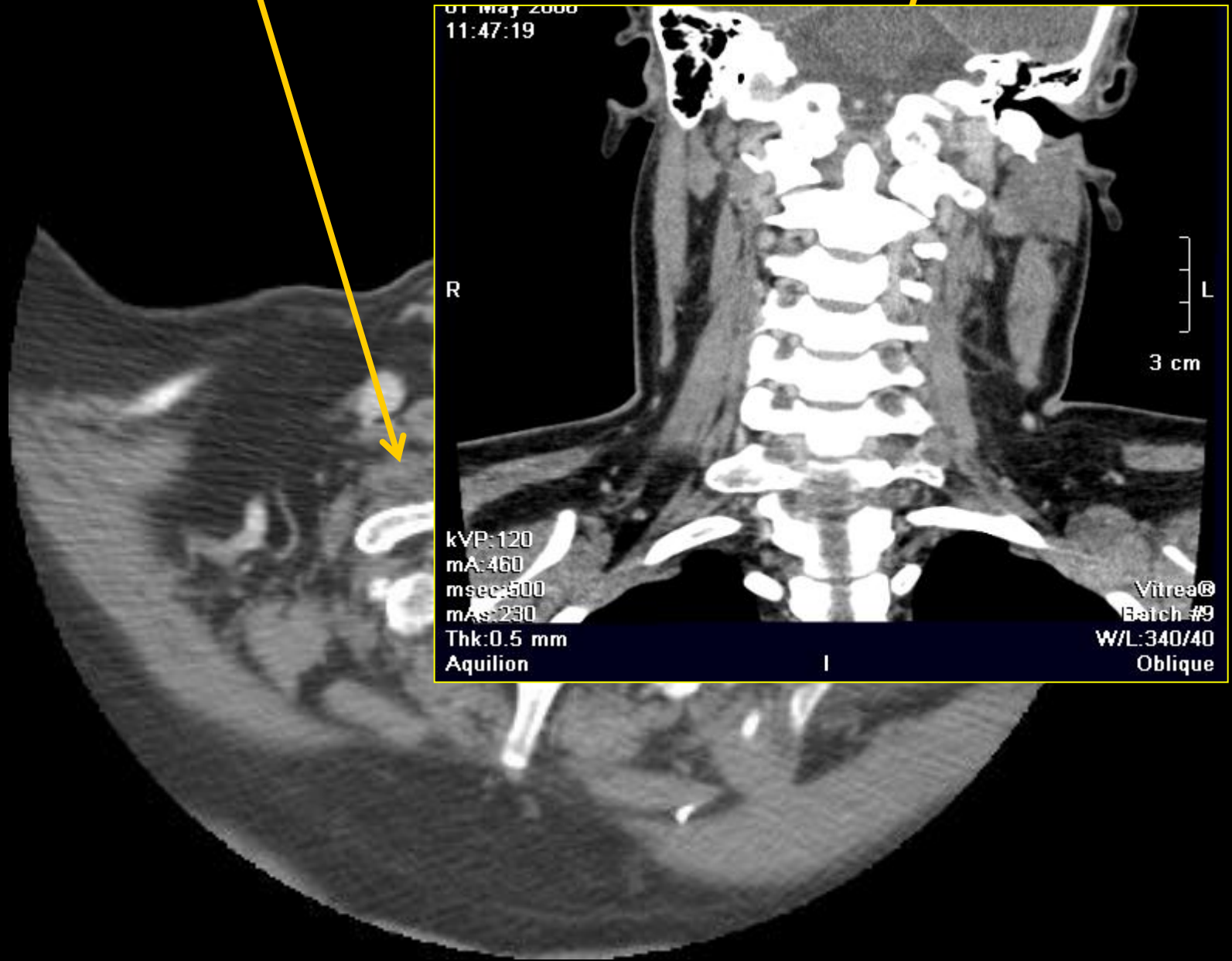






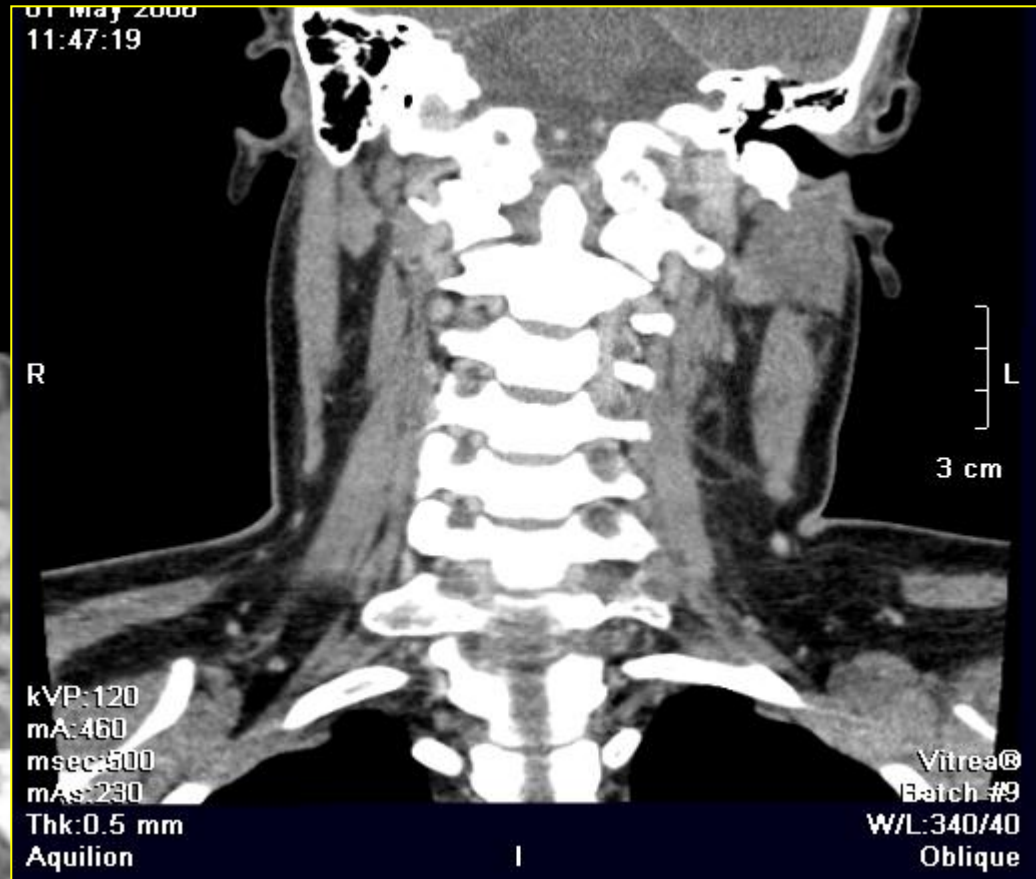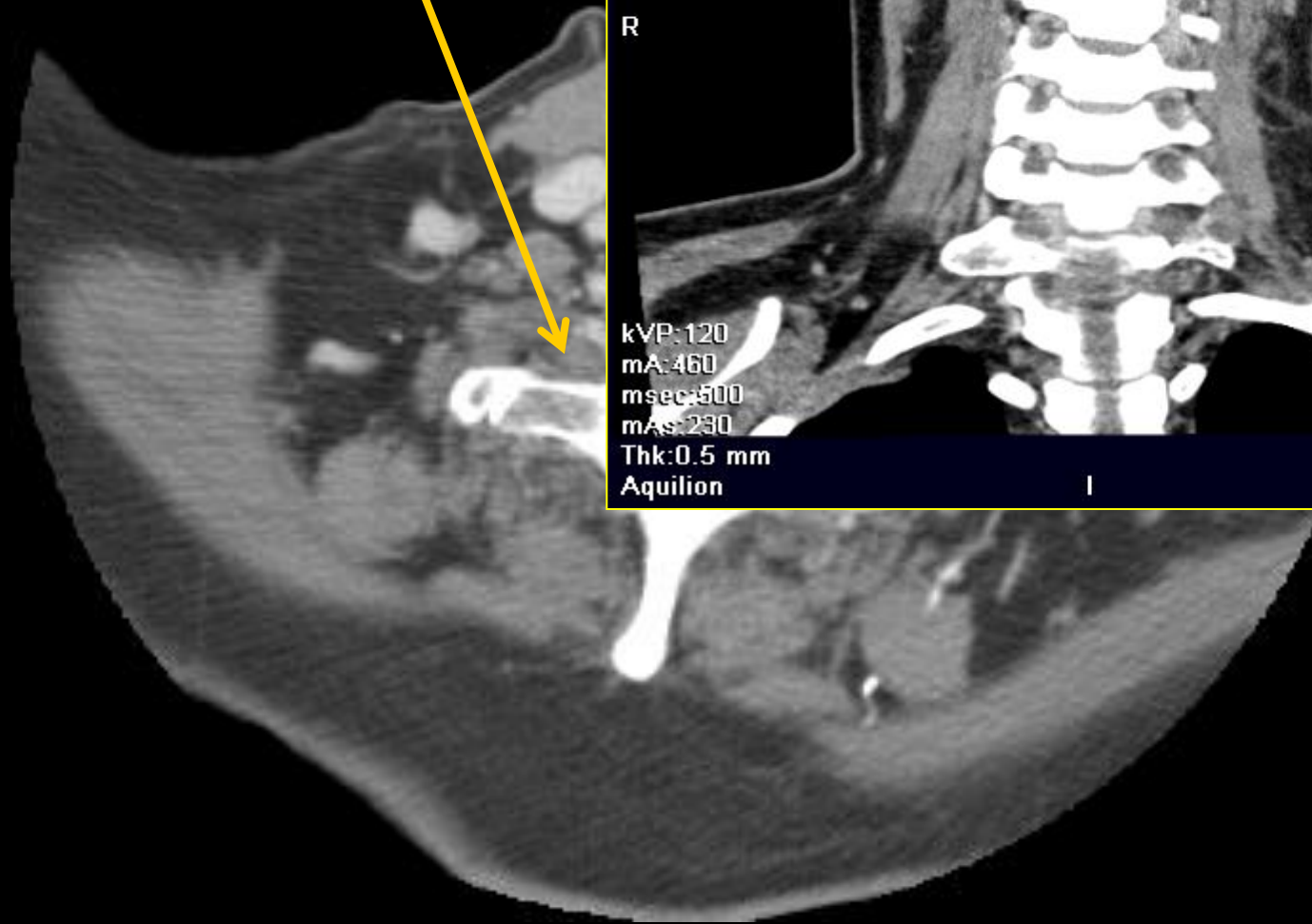


Skalen kaslar

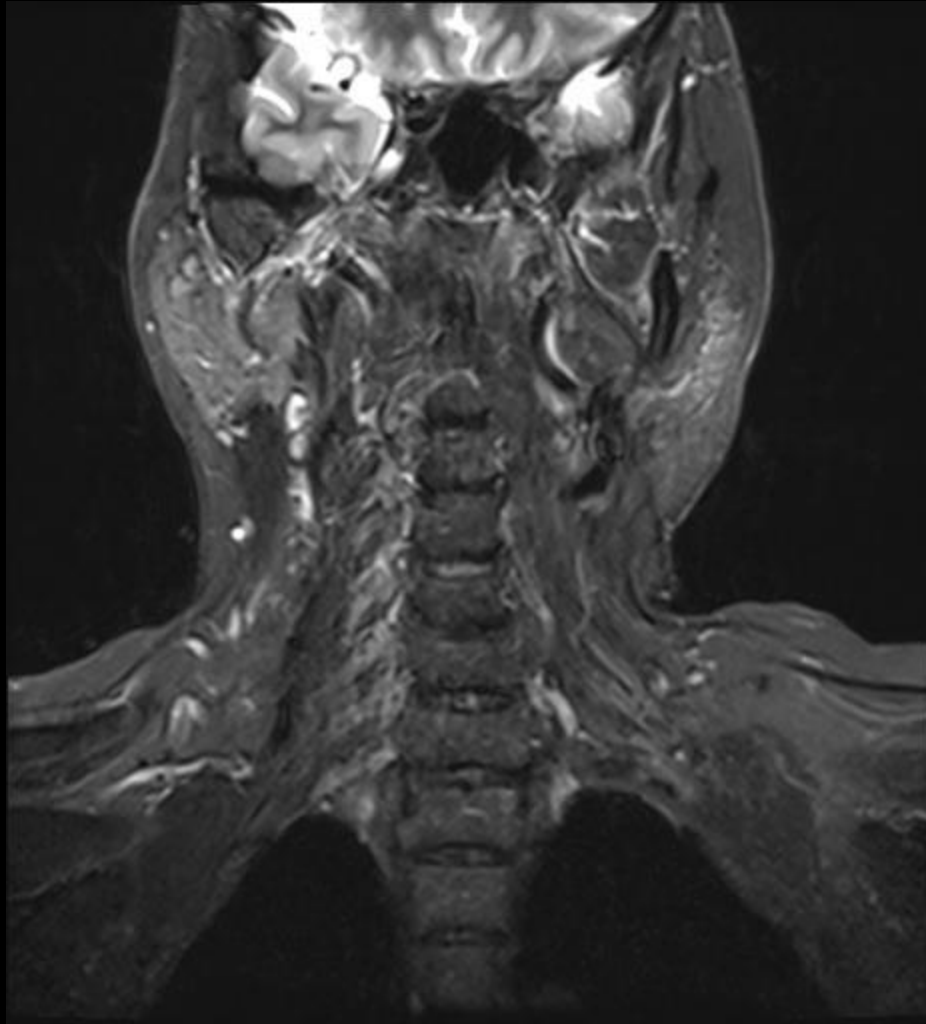


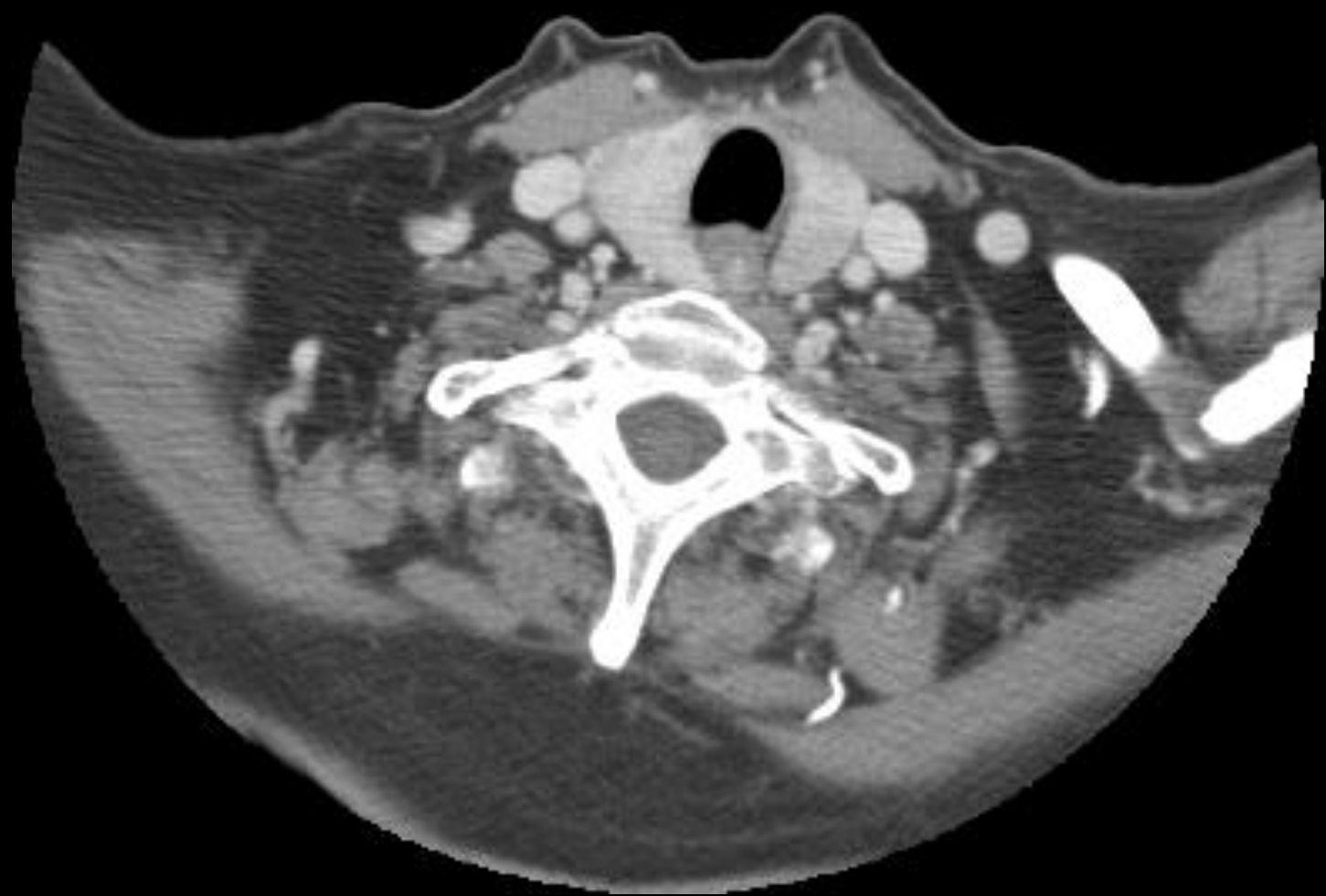


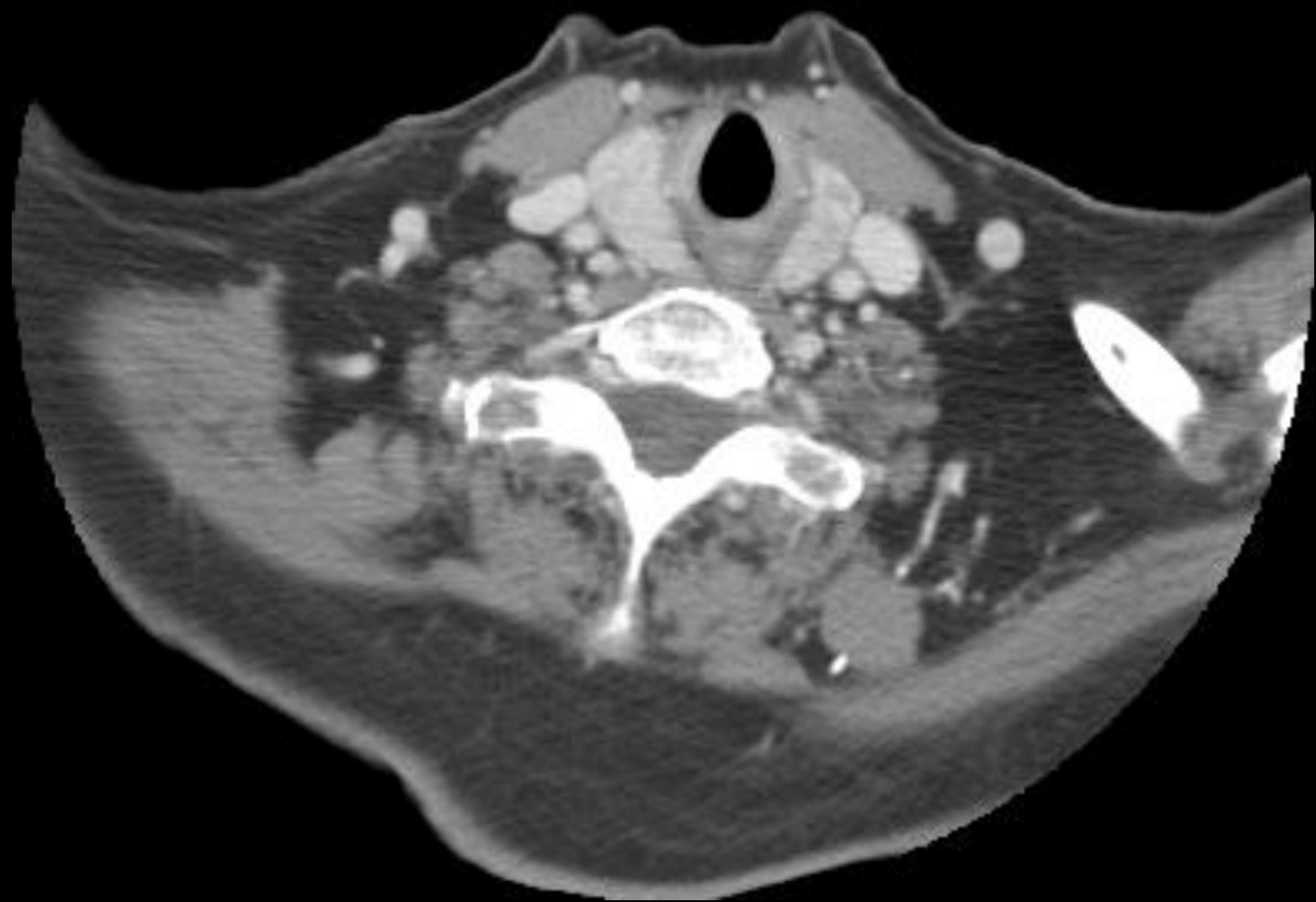
Brakial pleksus



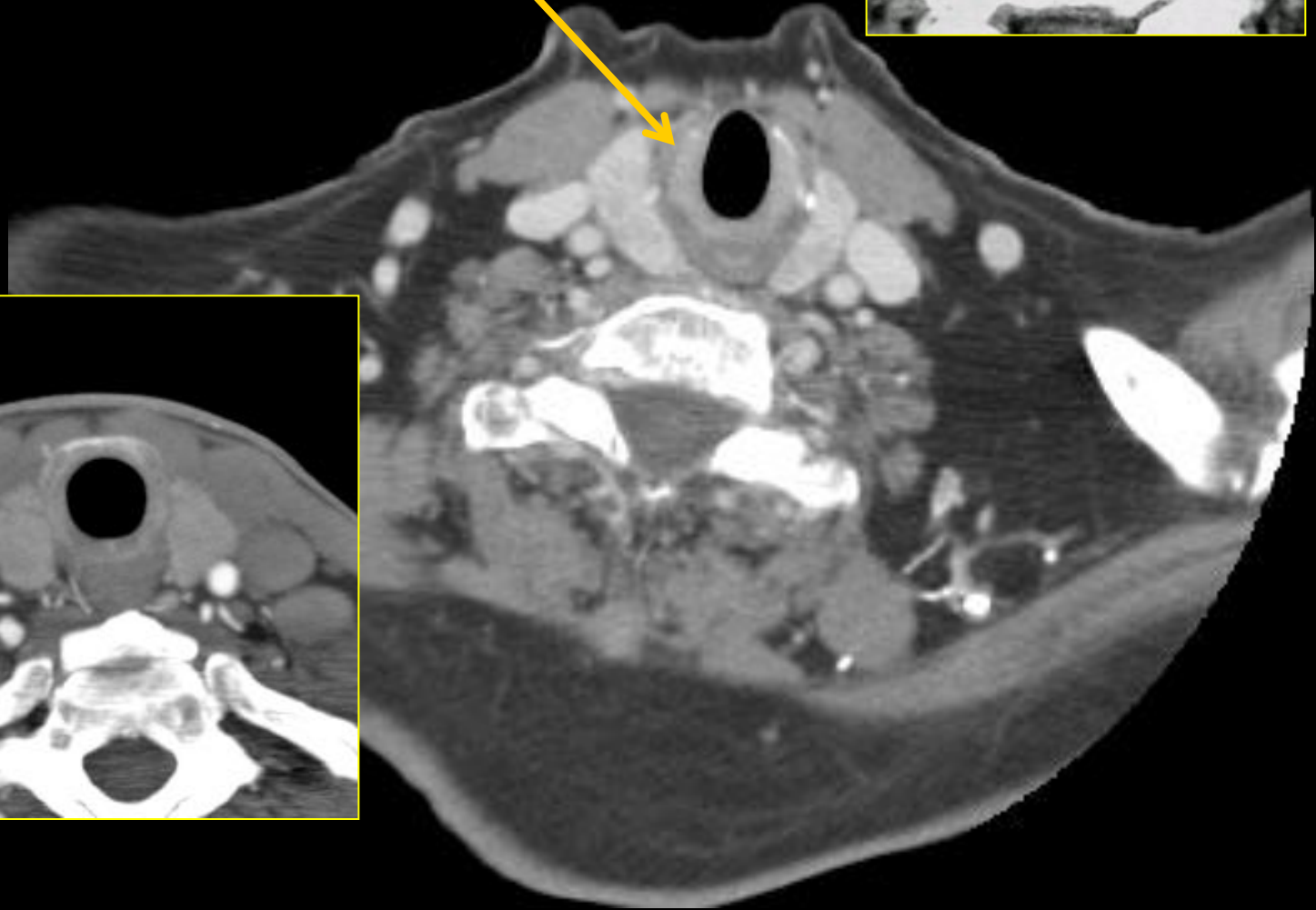
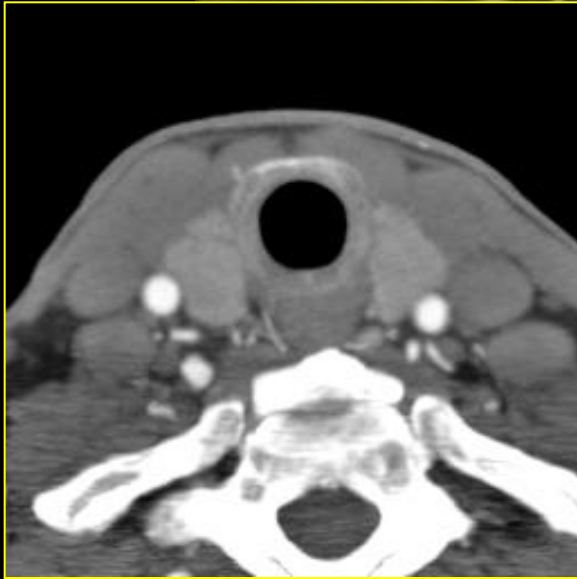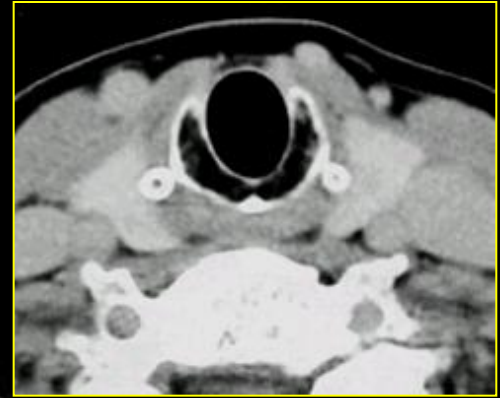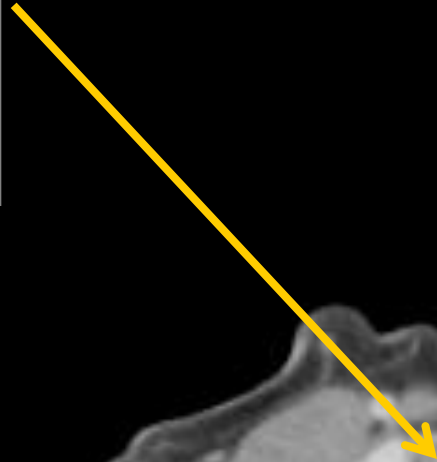
# Brakial pleksus

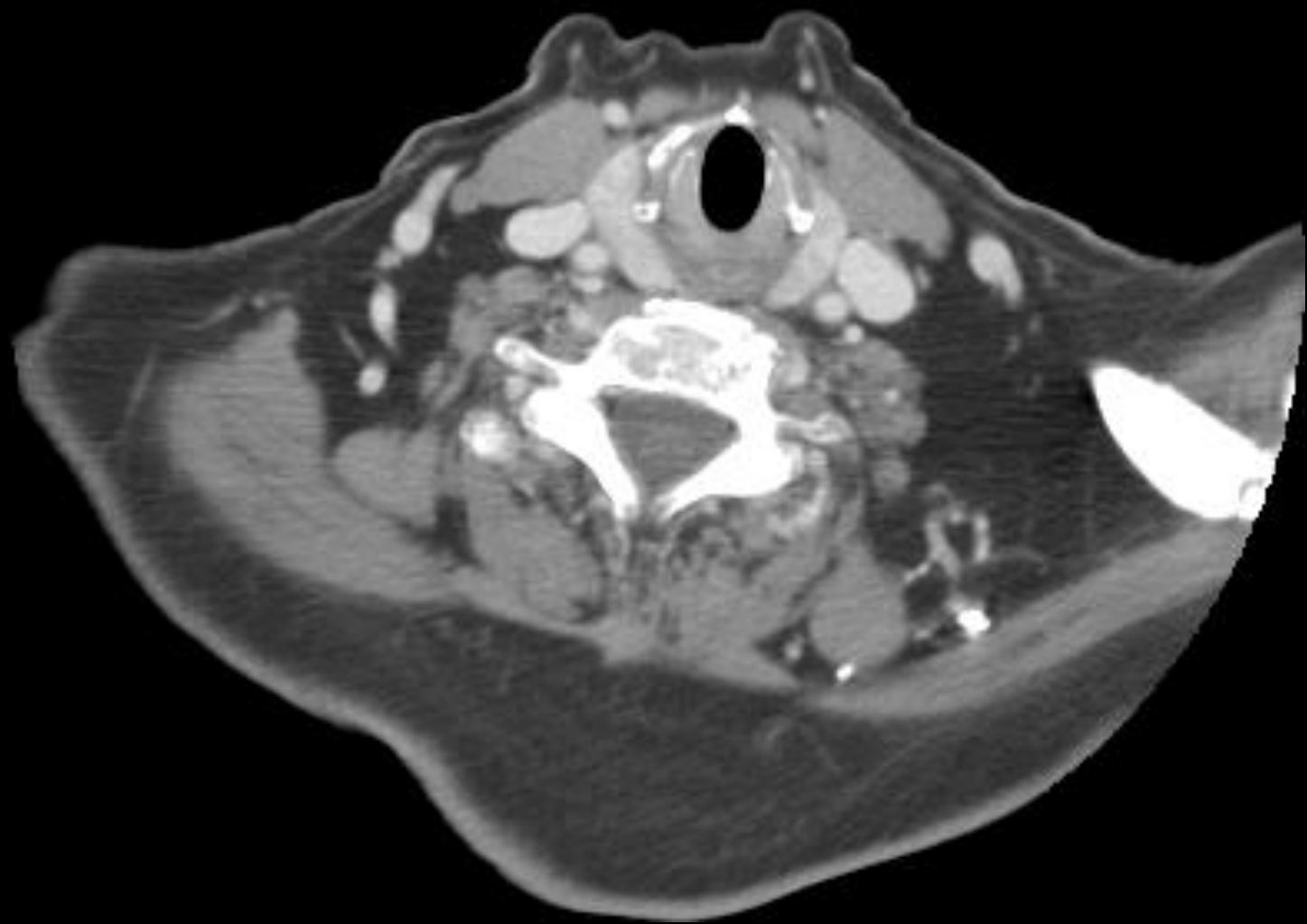




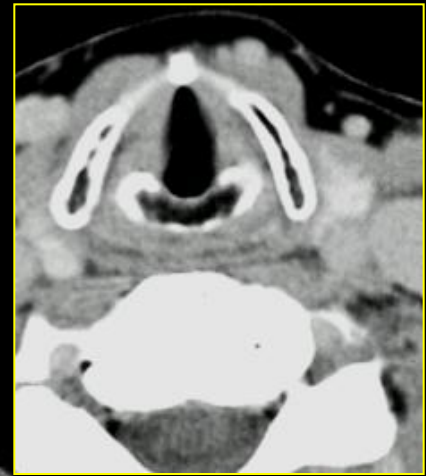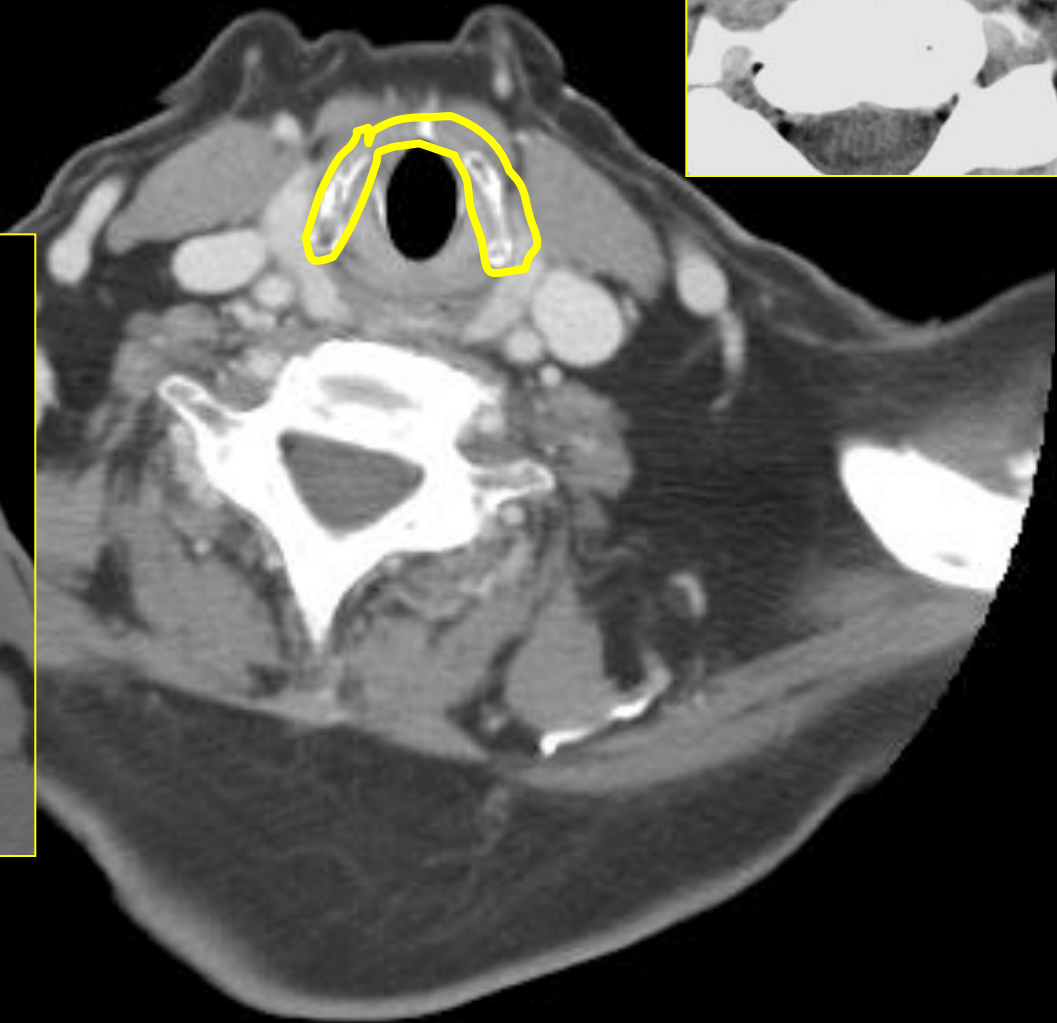

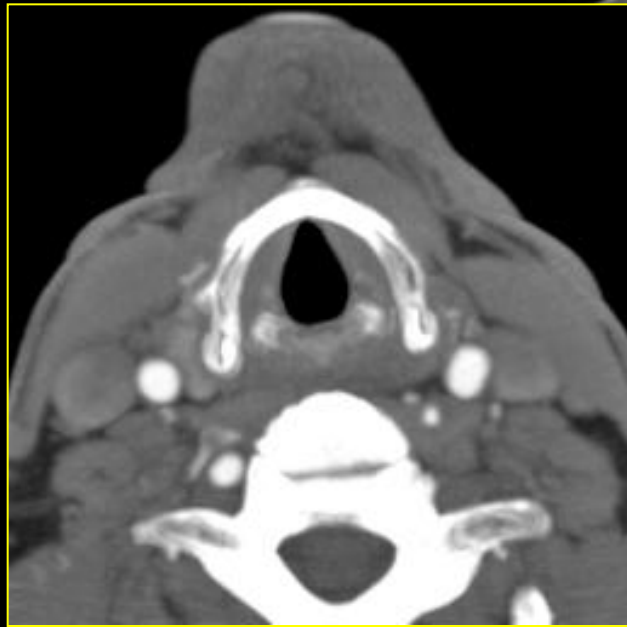
Krikoid kıkırdak

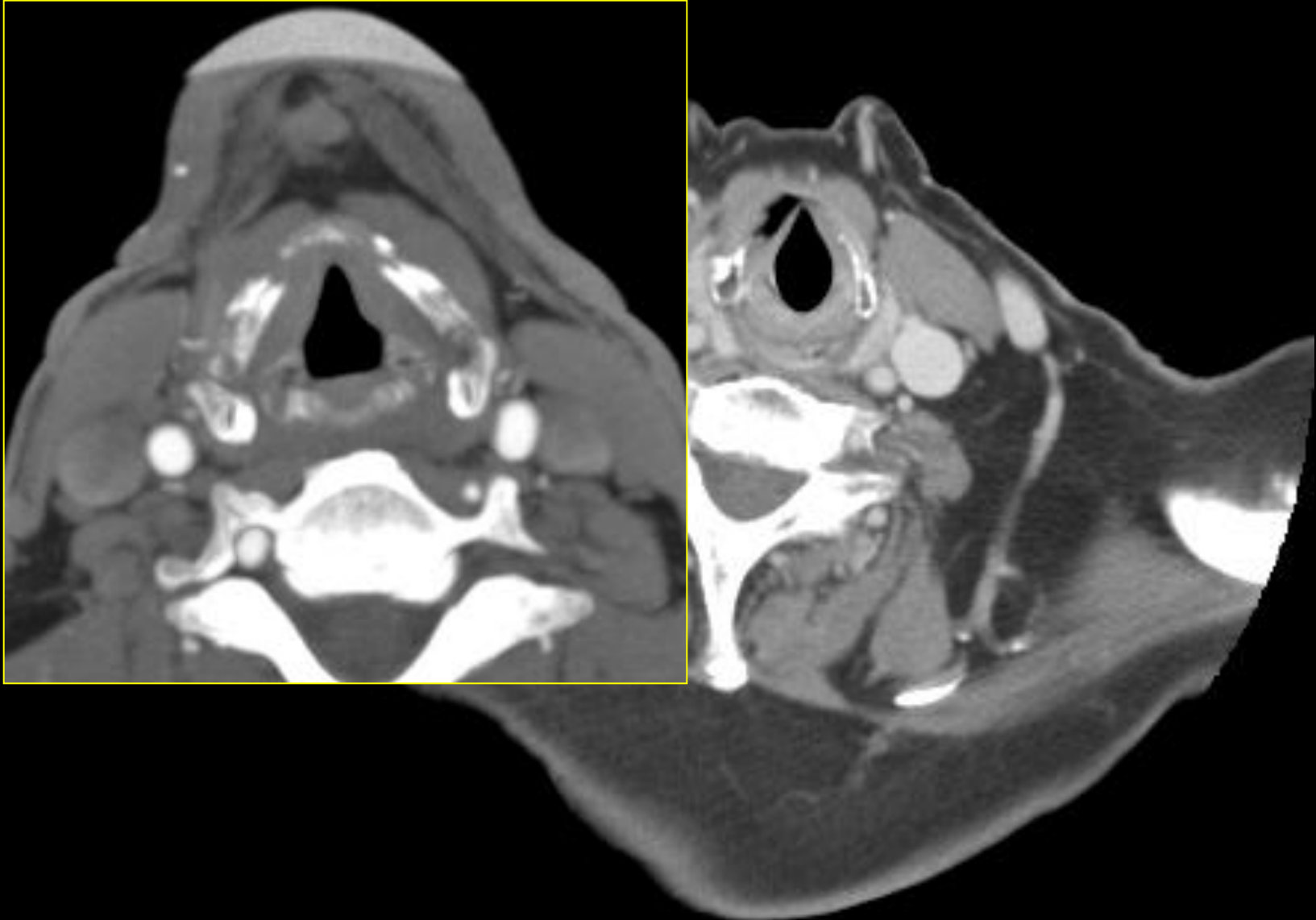




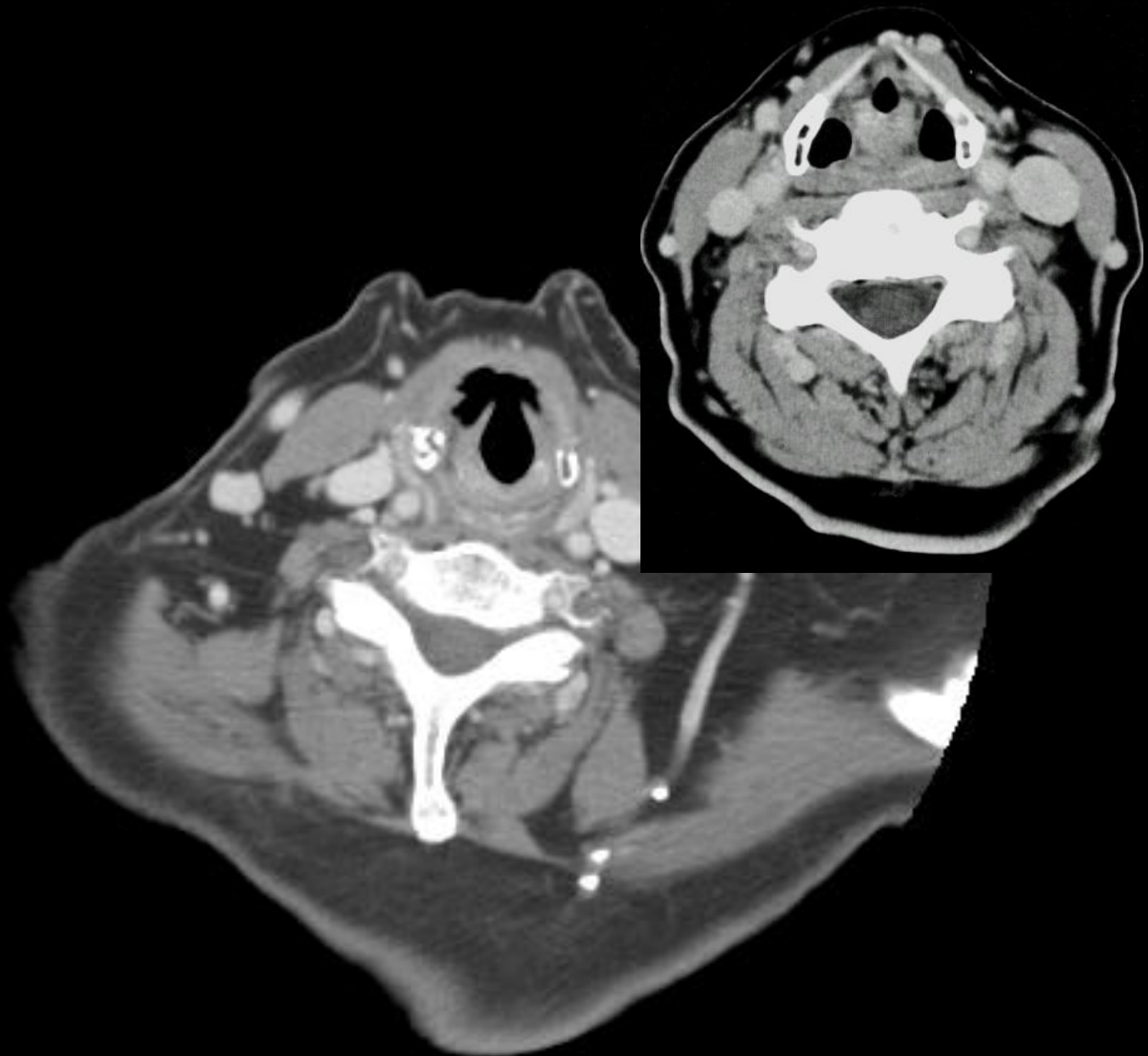
# Tiroid kıkırdak

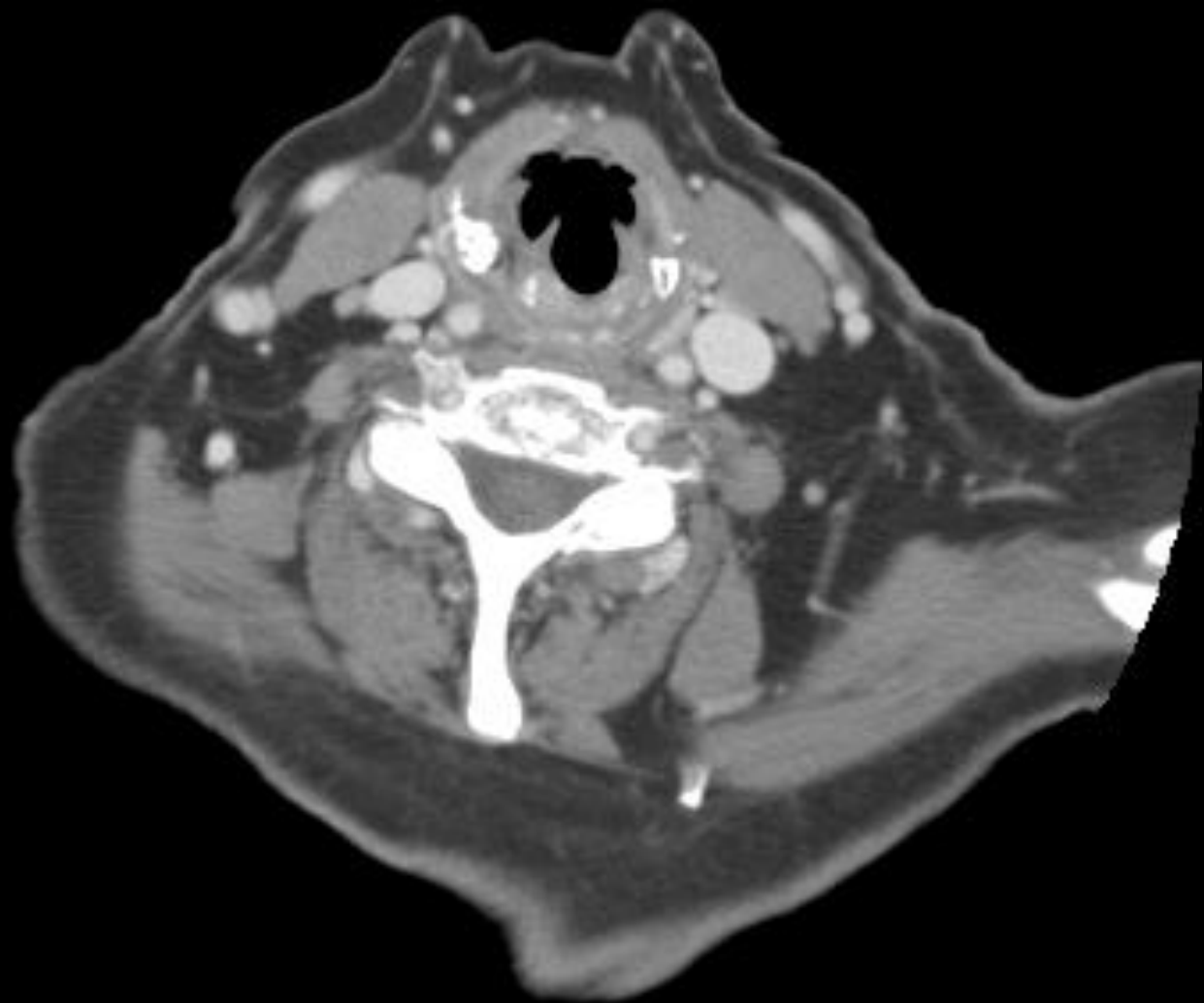


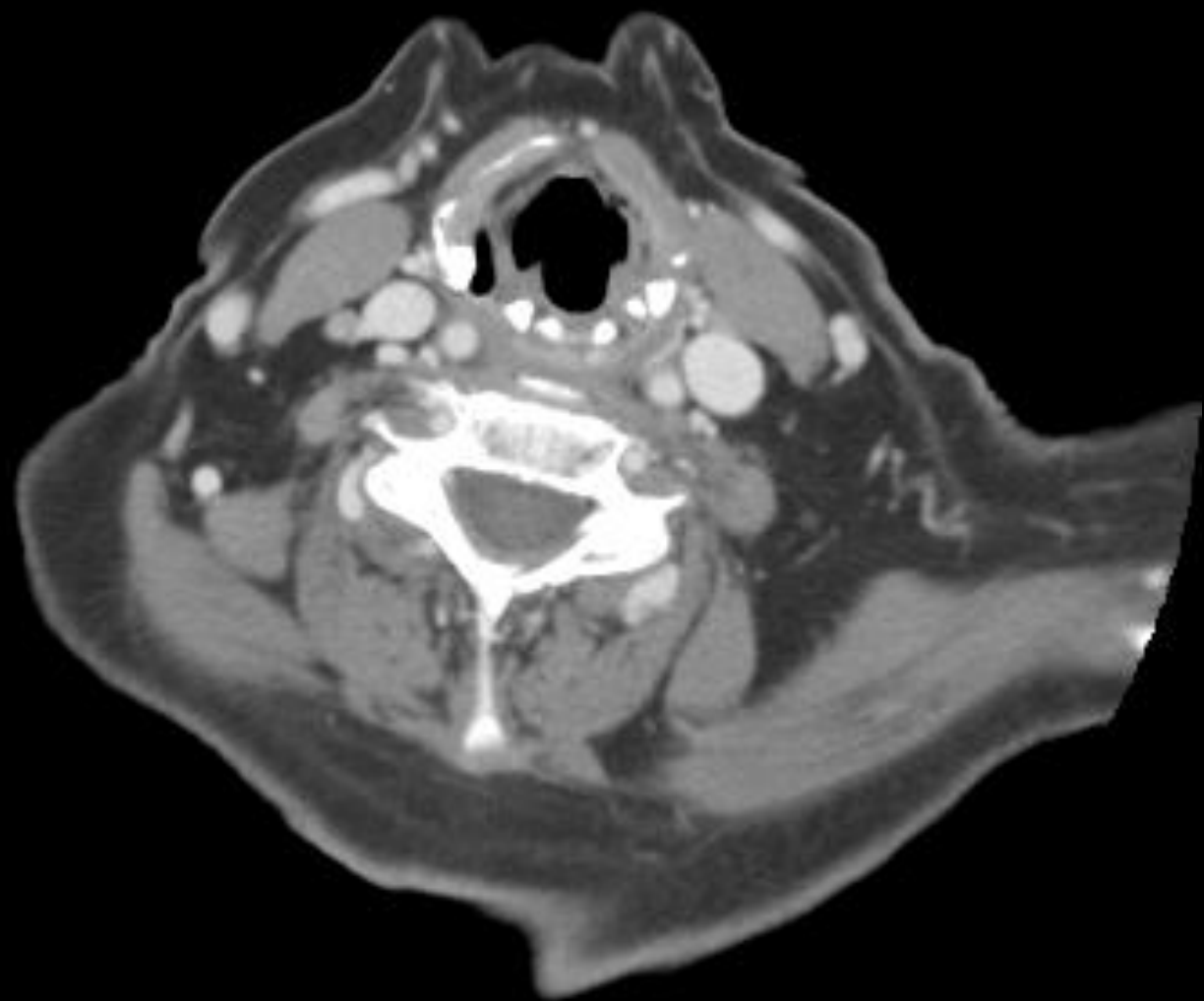
# Aritenoid kıkırdak



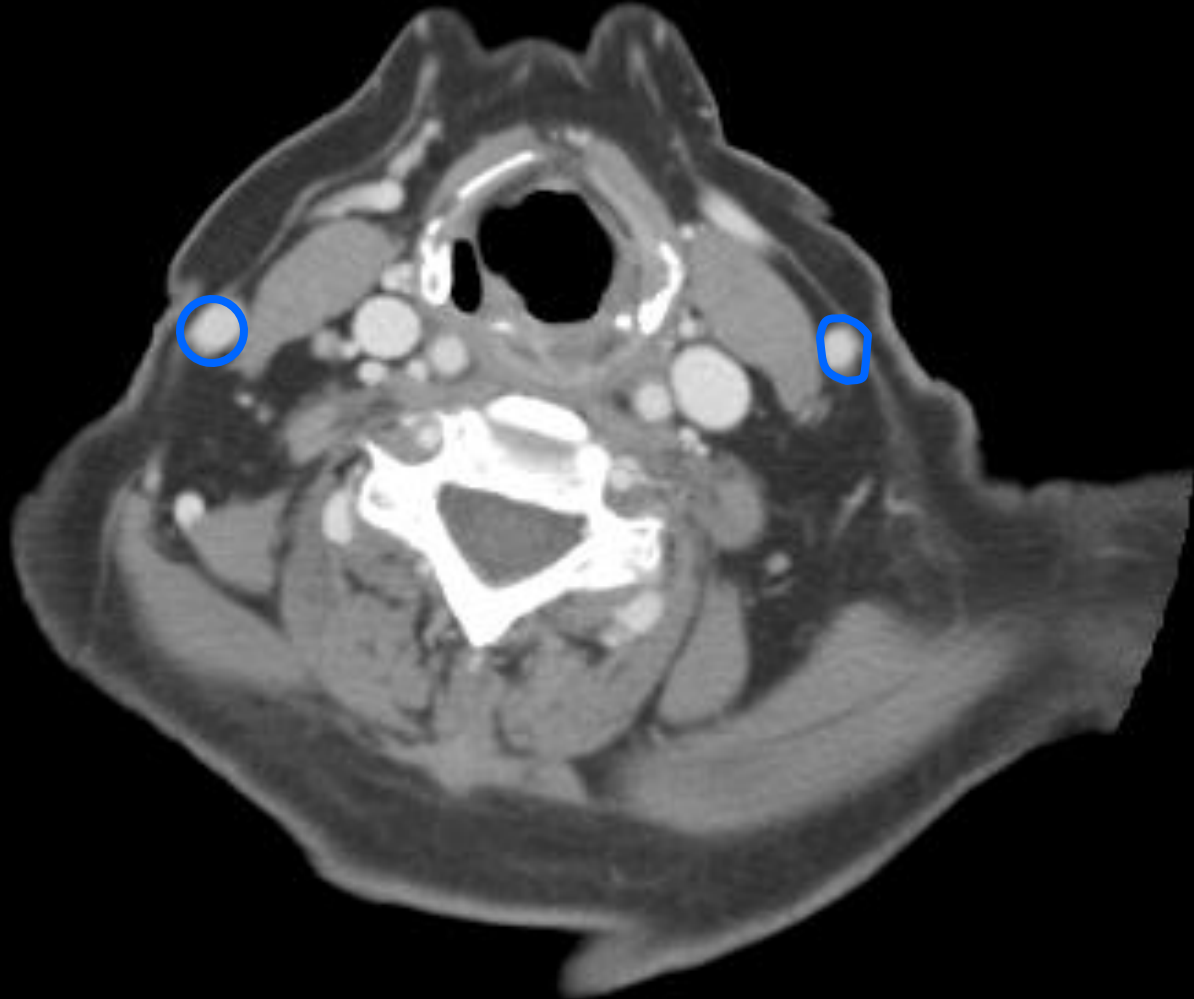


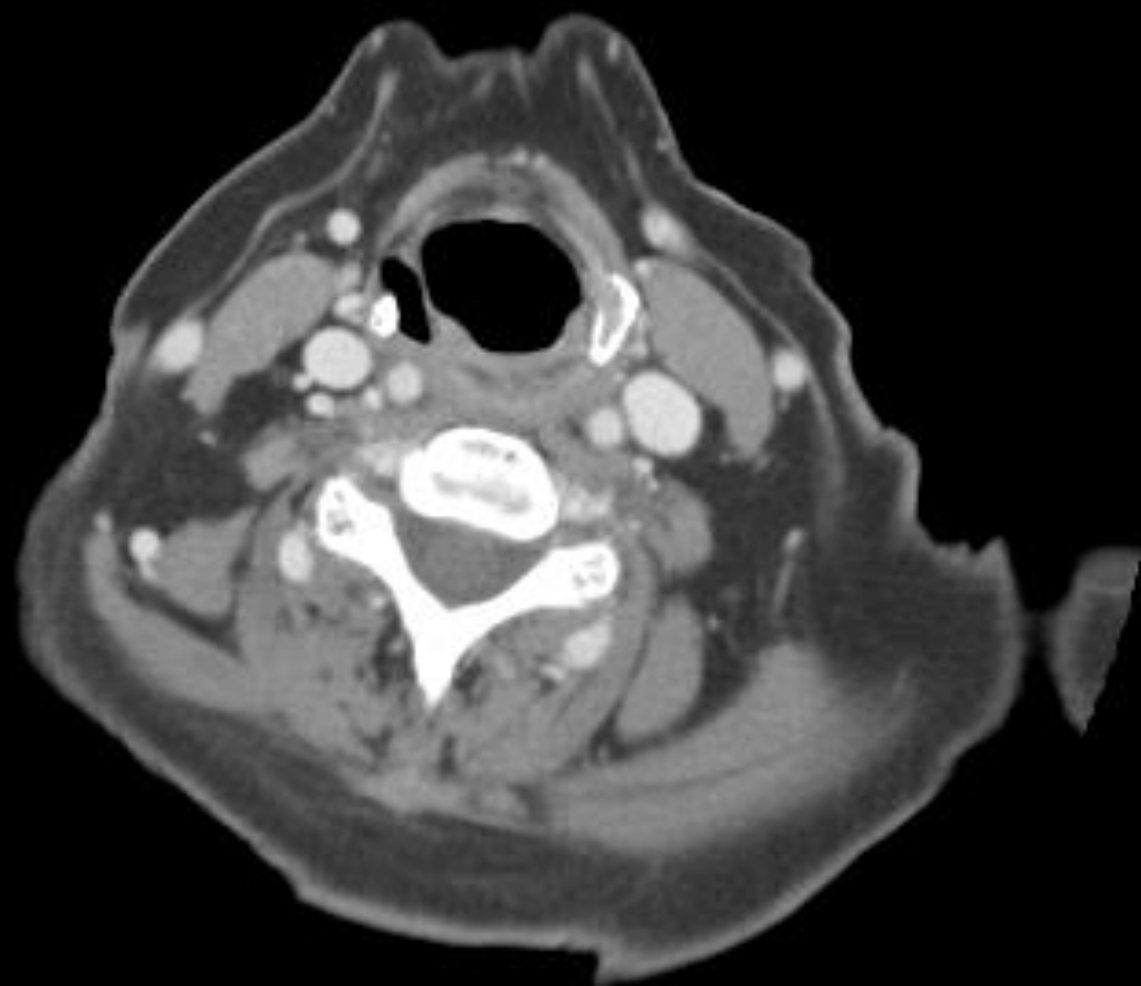


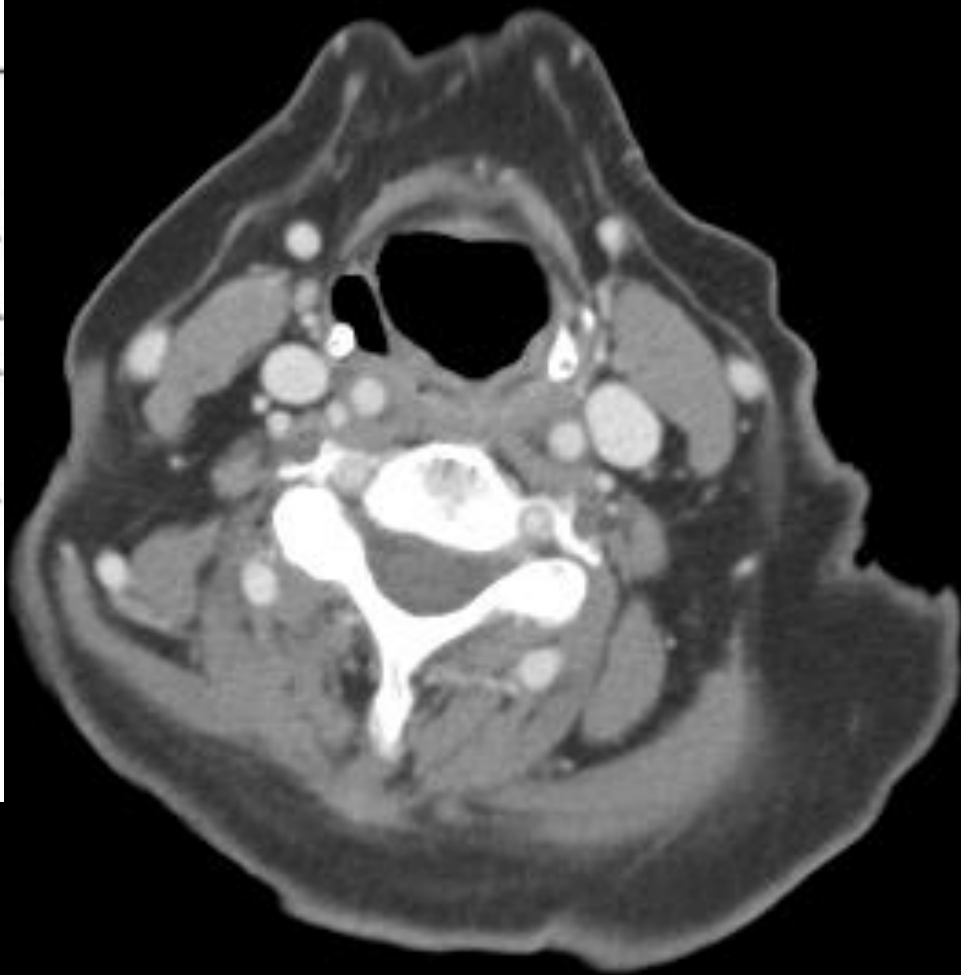
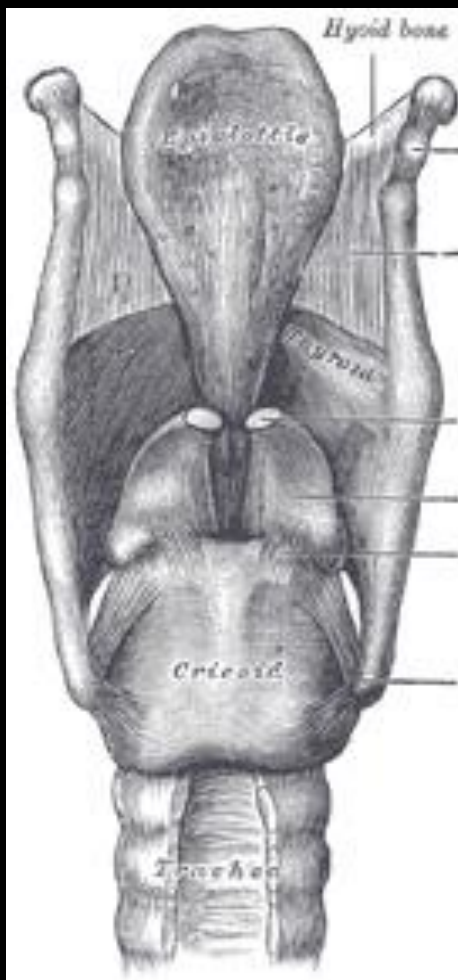




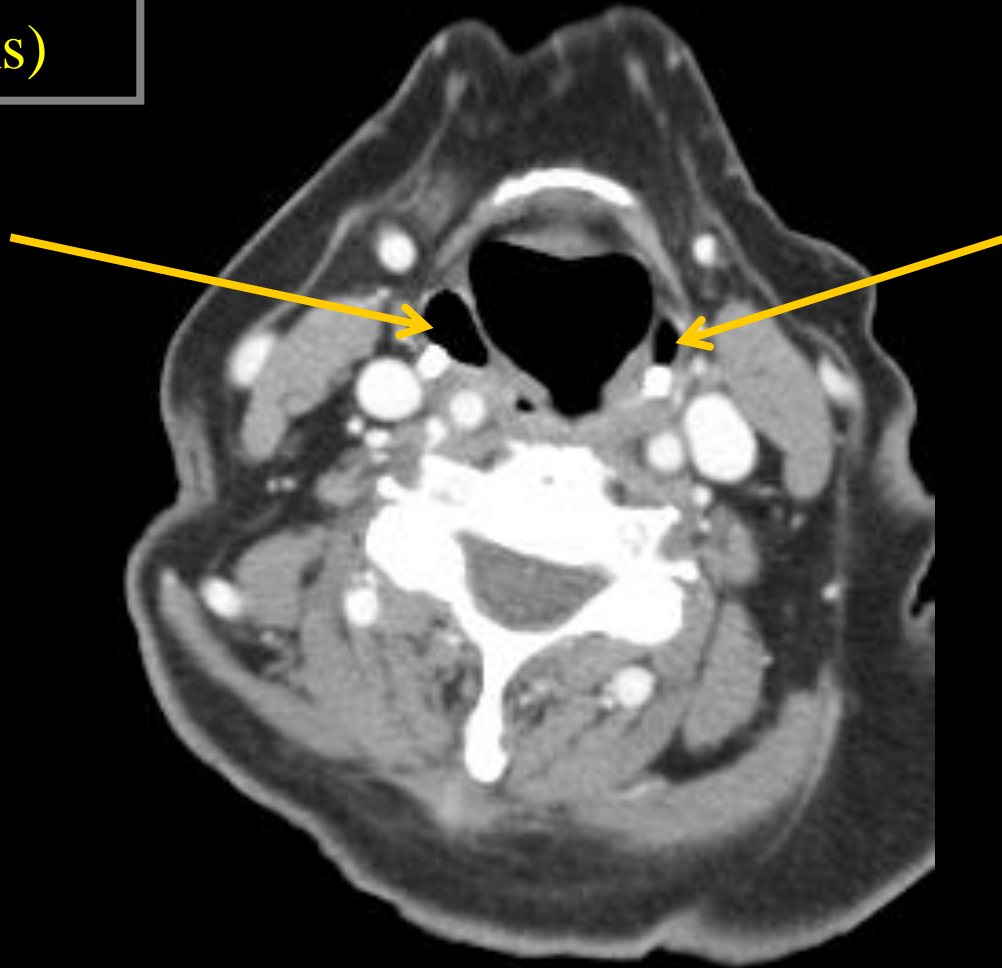
External jugular venler



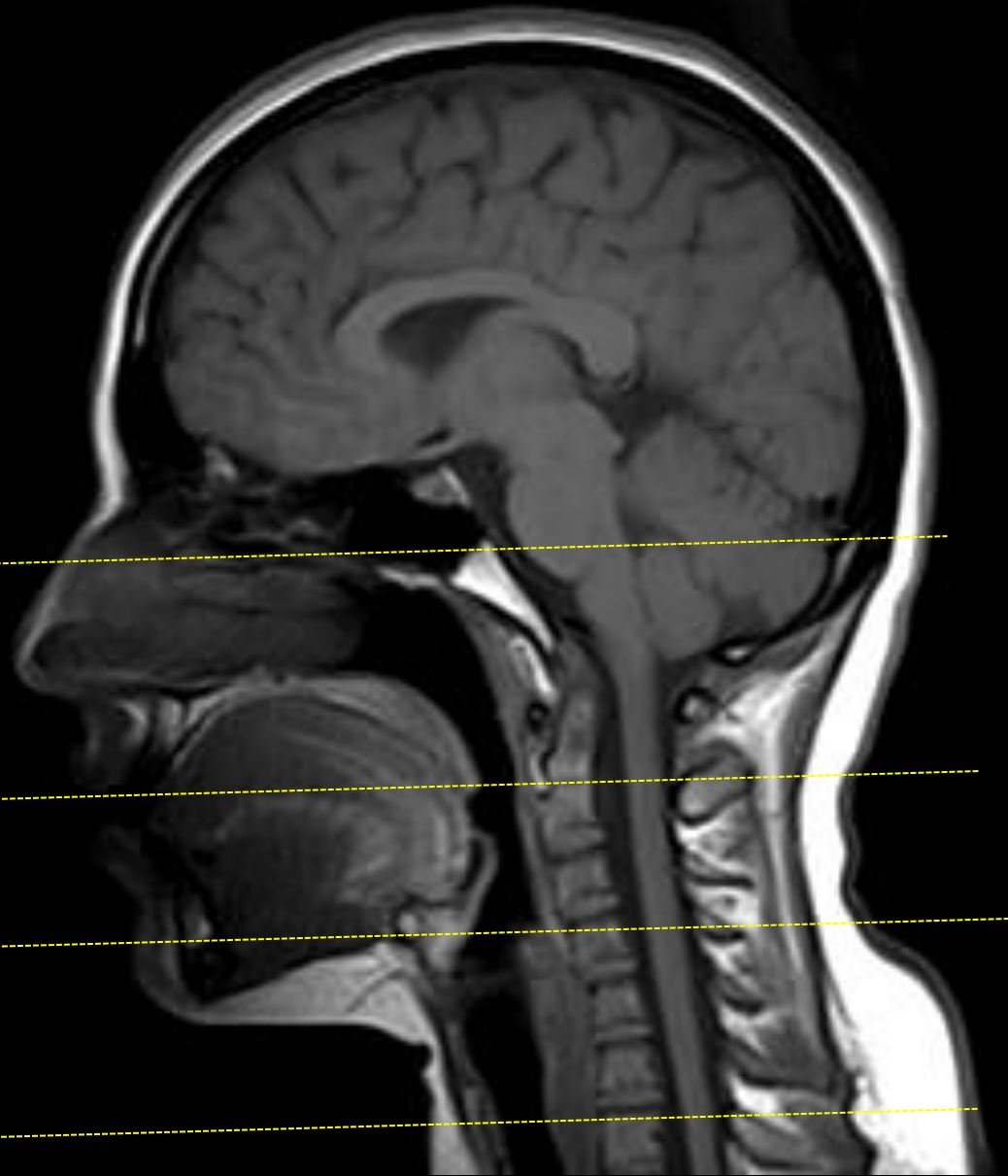




Piriform sinüsler  
(hipofarinks)



Nazofarinks



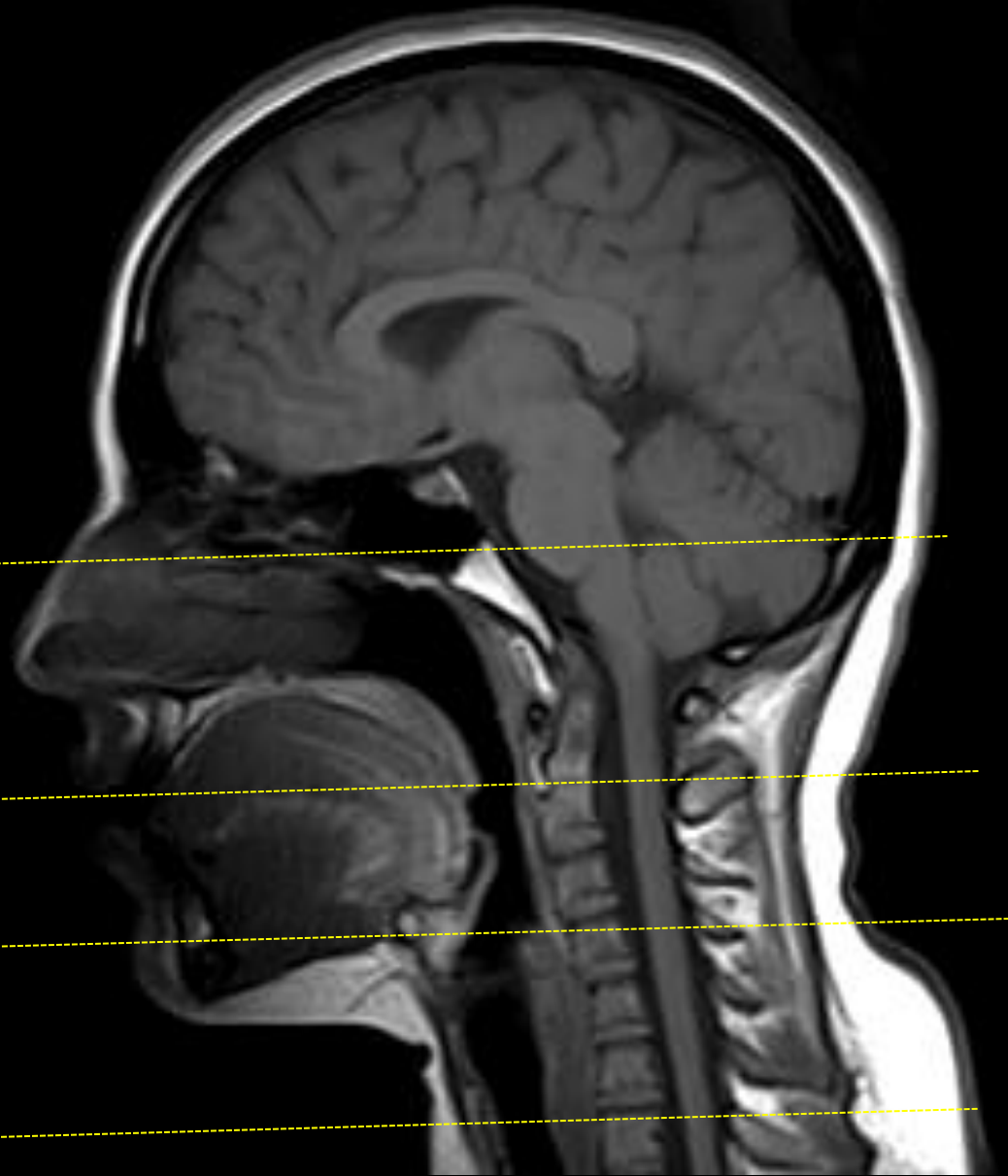




A sagittal MRI scan of the human head and neck. The image shows the brain, nasal cavity, oral cavity, and cervical spine. Four horizontal dashed yellow lines are drawn across the image to indicate anatomical planes: the top line is at the level of the nasal cavity, the second line is at the level of the hard palate, the third line is at the level of the soft palate, and the bottom line is at the level of the larynx. A text box on the left contains the word 'Orofarinks'.

Orofarinks

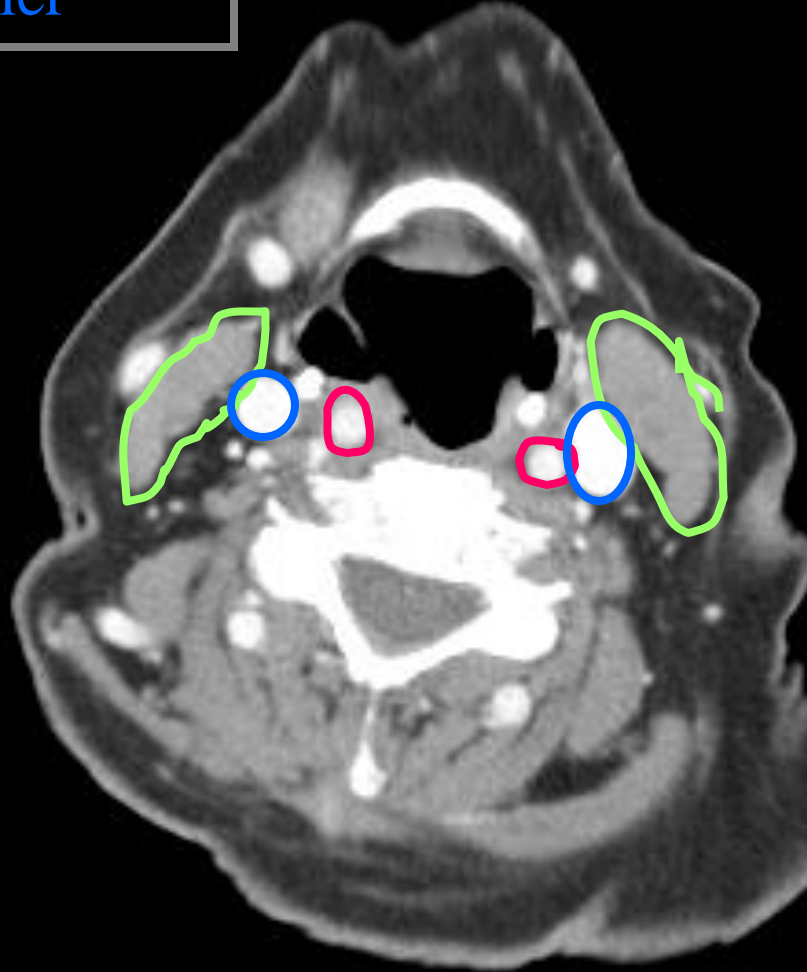
Hipofarinks

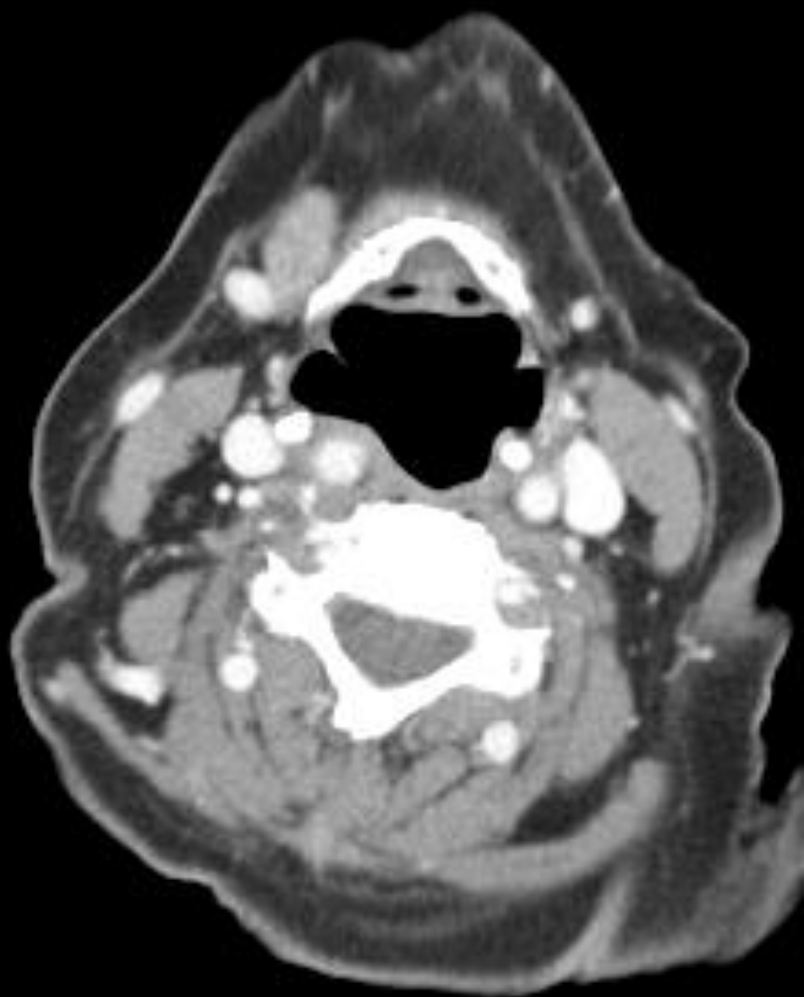


Sternocleidomastoid kasları

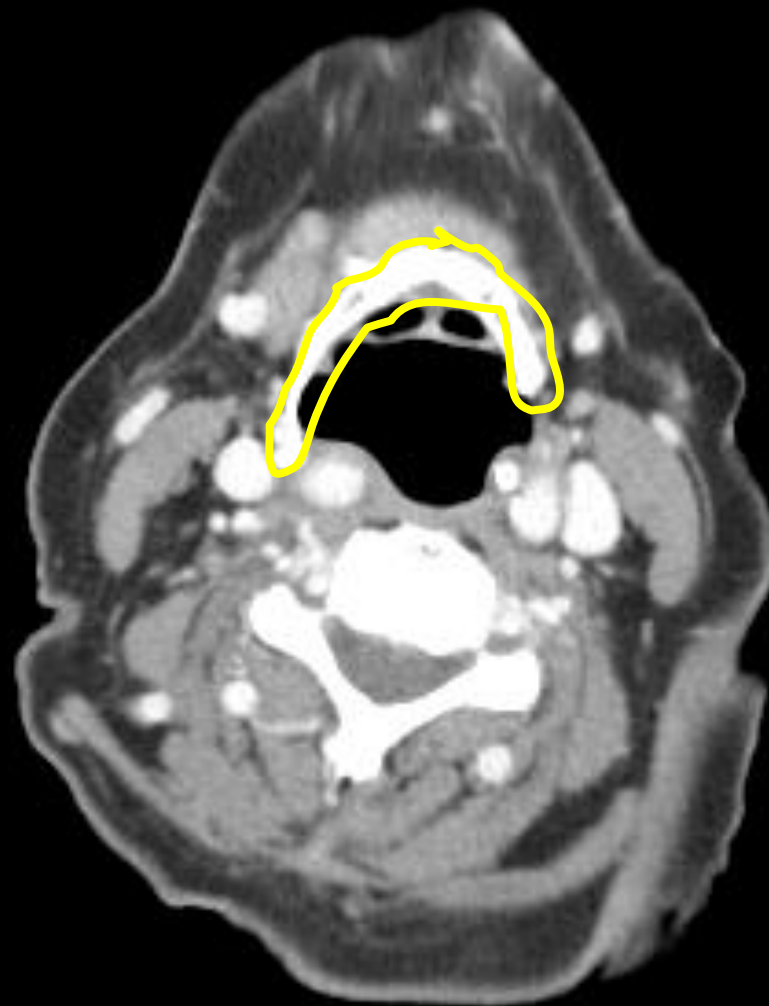
Ana carotid arterler

İnternal jugular venler



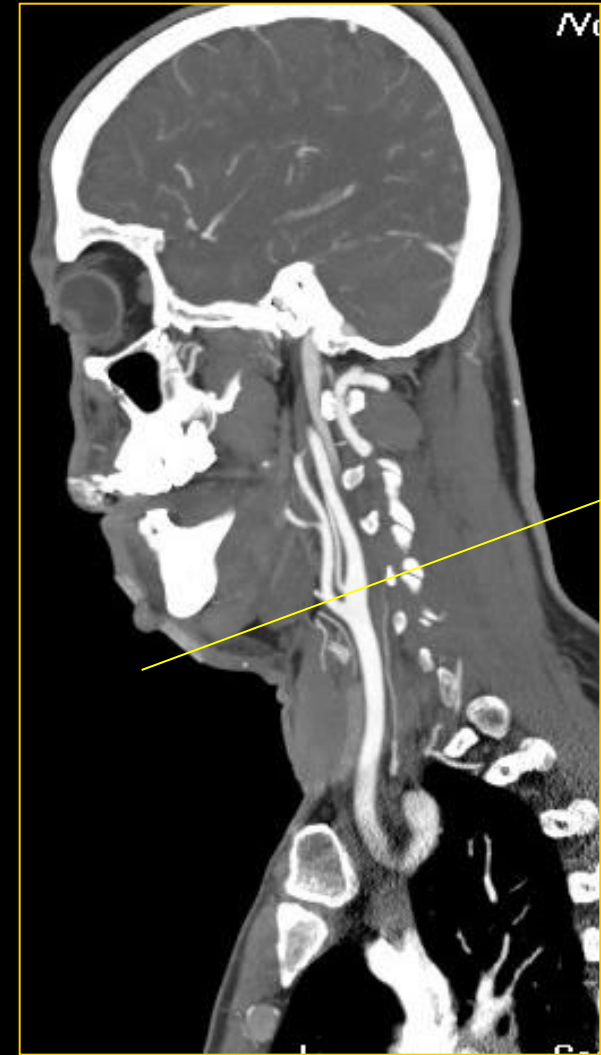
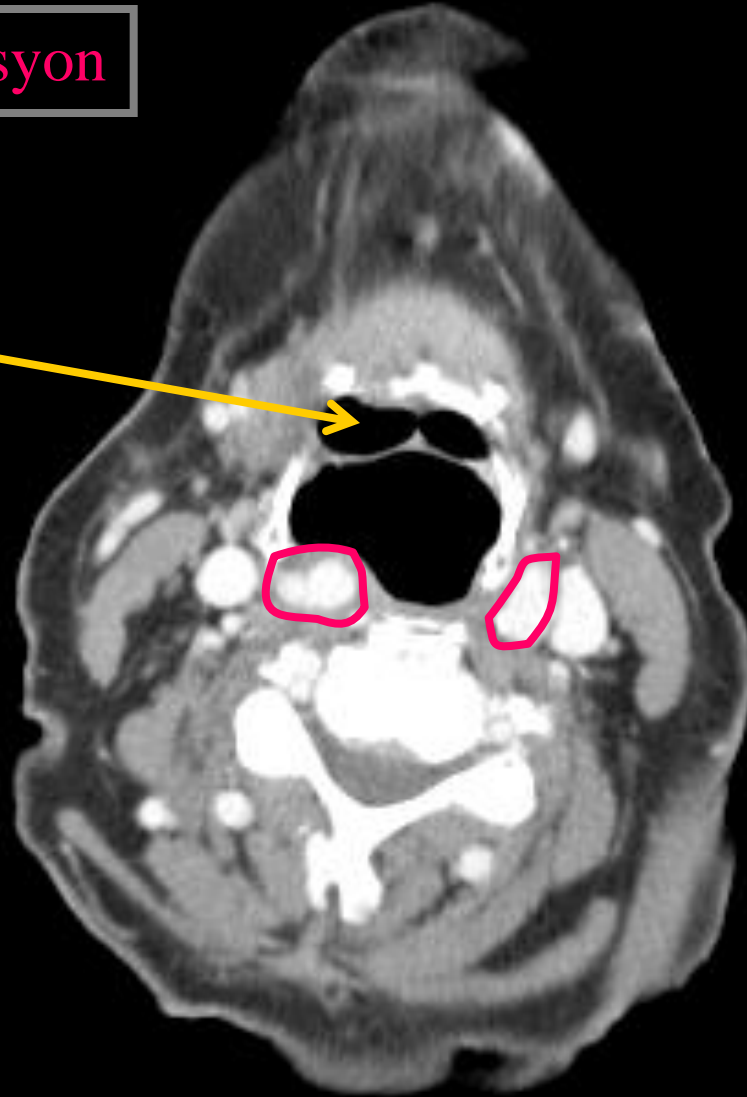
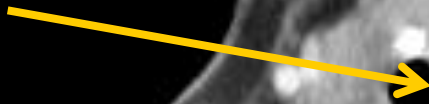


Hyoid

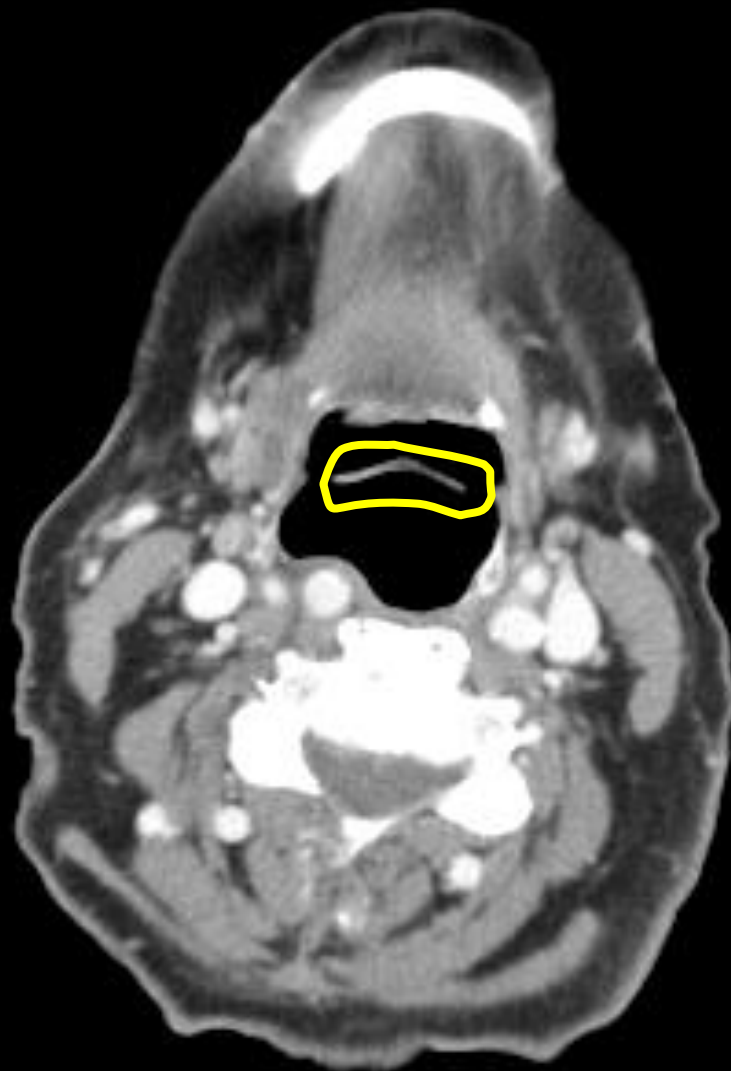


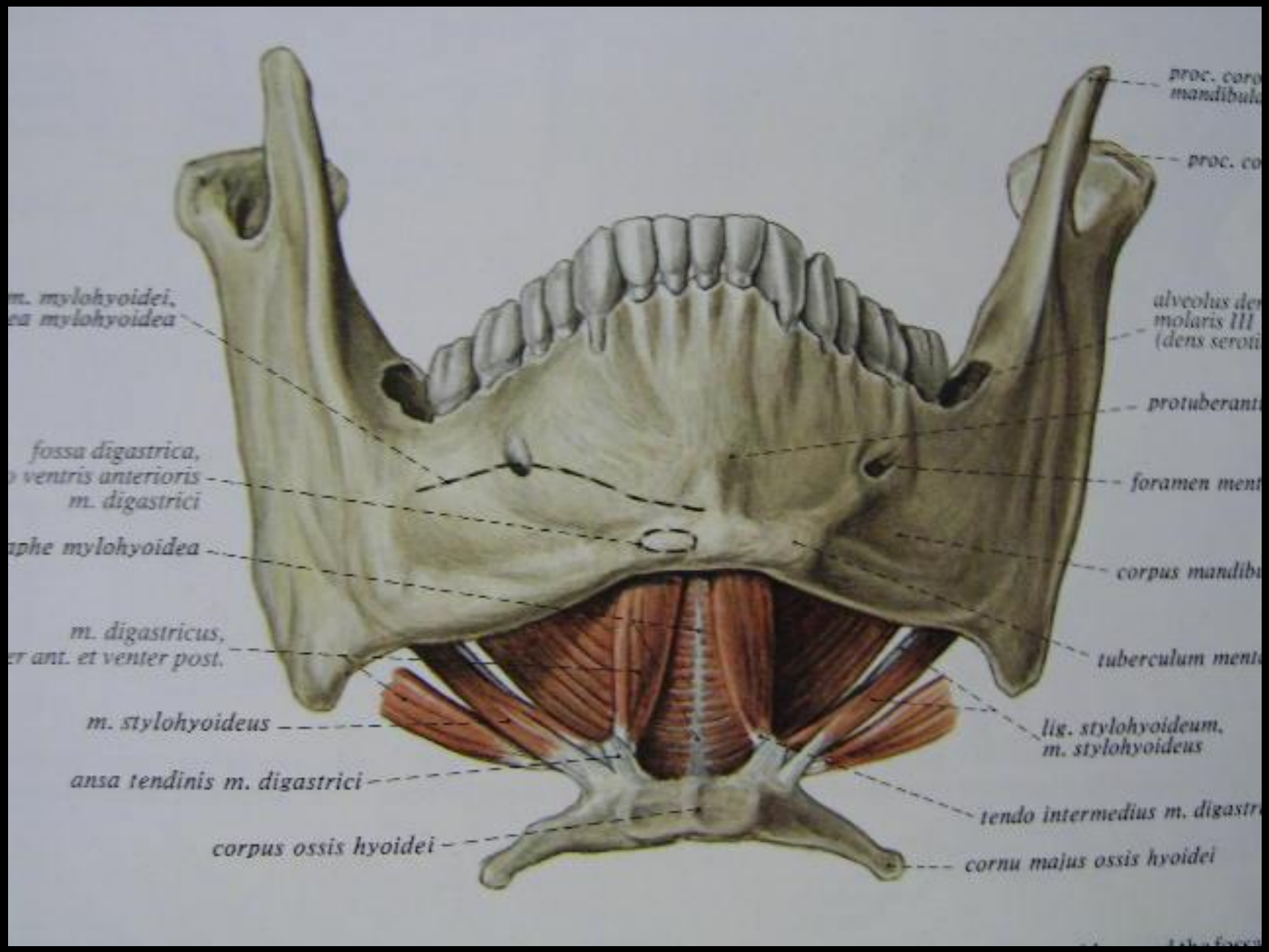
Karotid bifurkasyon

Valleküla



epiglottis





*m. mylohyoidei,  
apophyse mylohyoidea*

*fossa digastrica,  
venter anterioris  
m. digastrici*

*apophyse mylohyoidea*

*m. digastricus,  
venter ant. et venter post.*

*m. stylohyoideus*

*ansa tendinis m. digastrici*

*corpus ossis hyoidei*

*proc. coronoideus  
mandibulae*

*proc. coronoideus*

*alveolus dentium  
molaris III  
(dens seroti)*

*protuberantia  
mentalis*

*foramen mentale*

*corpus mandibulae*

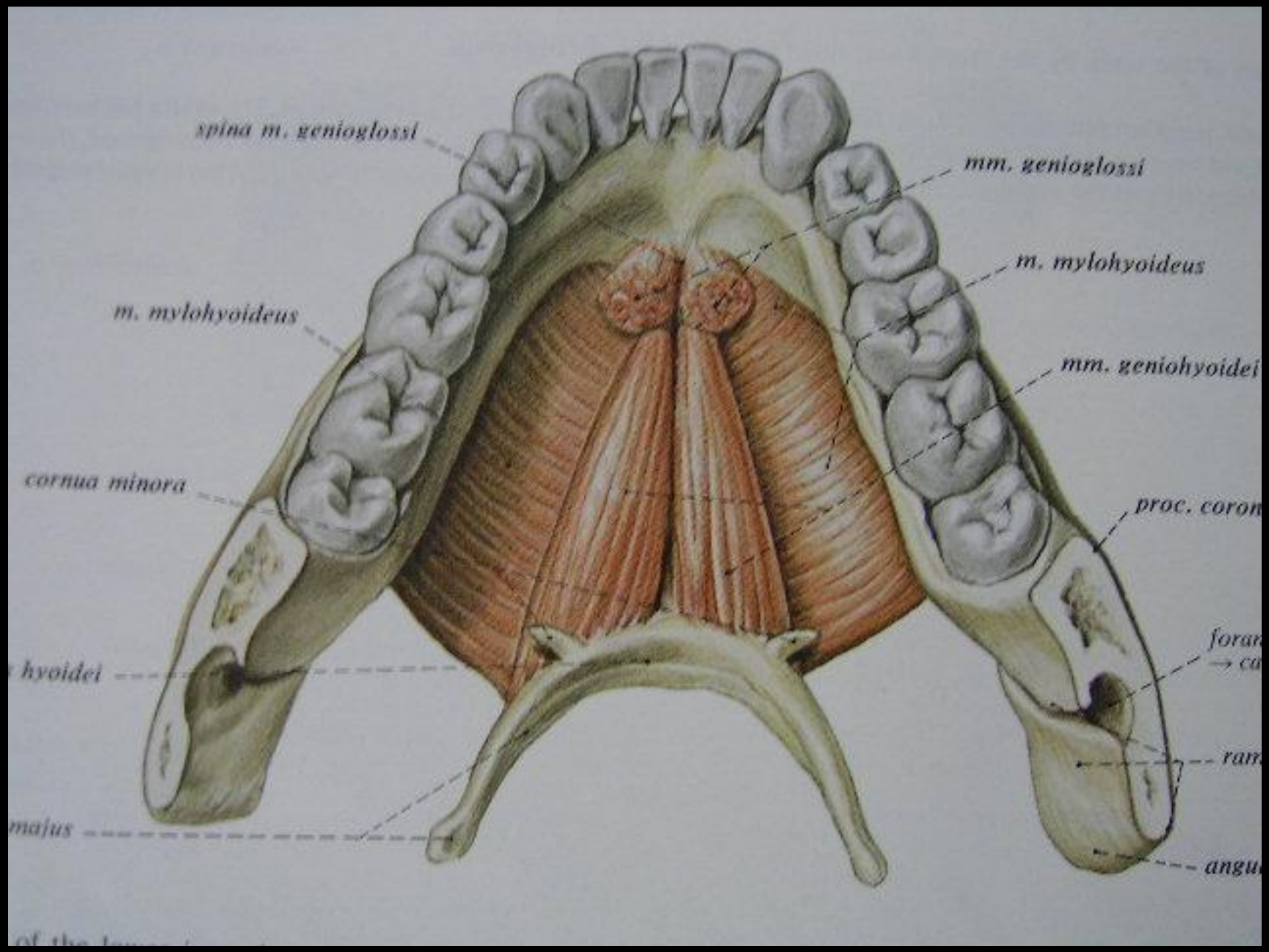
*tuberculum mentale*

*lig. stylohyoideum,  
m. stylohyoideus*

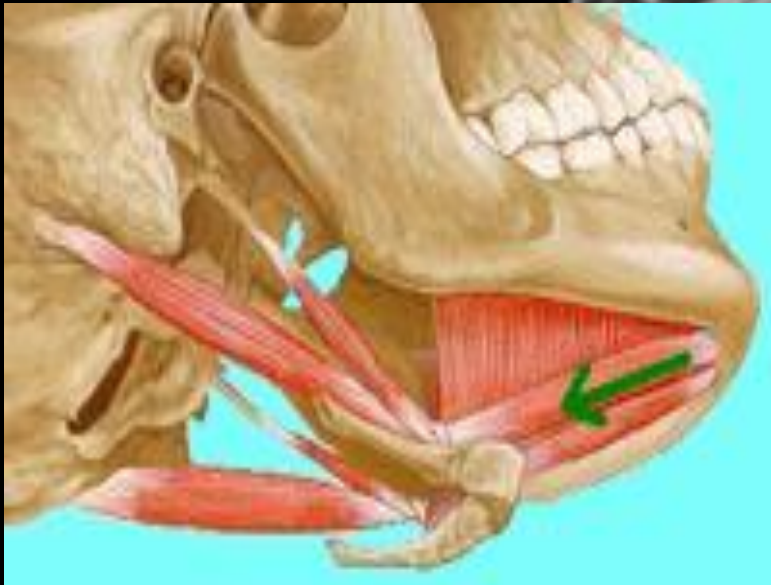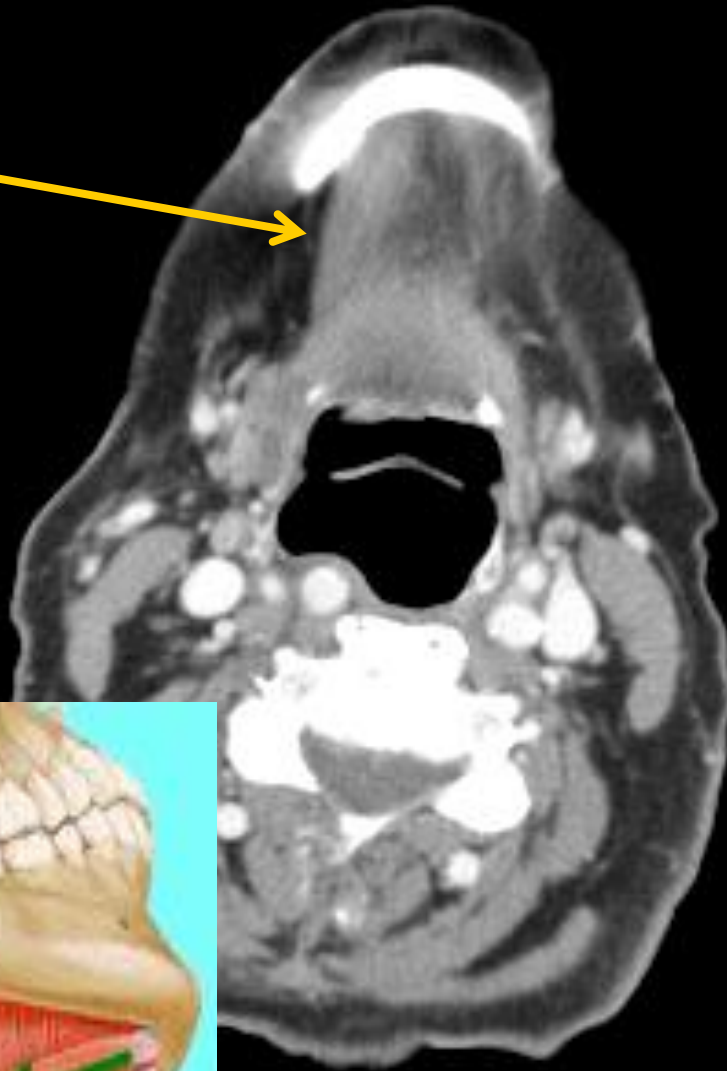
*tendo intermedius m. digastrici*

*cornu majus ossis hyoidei*

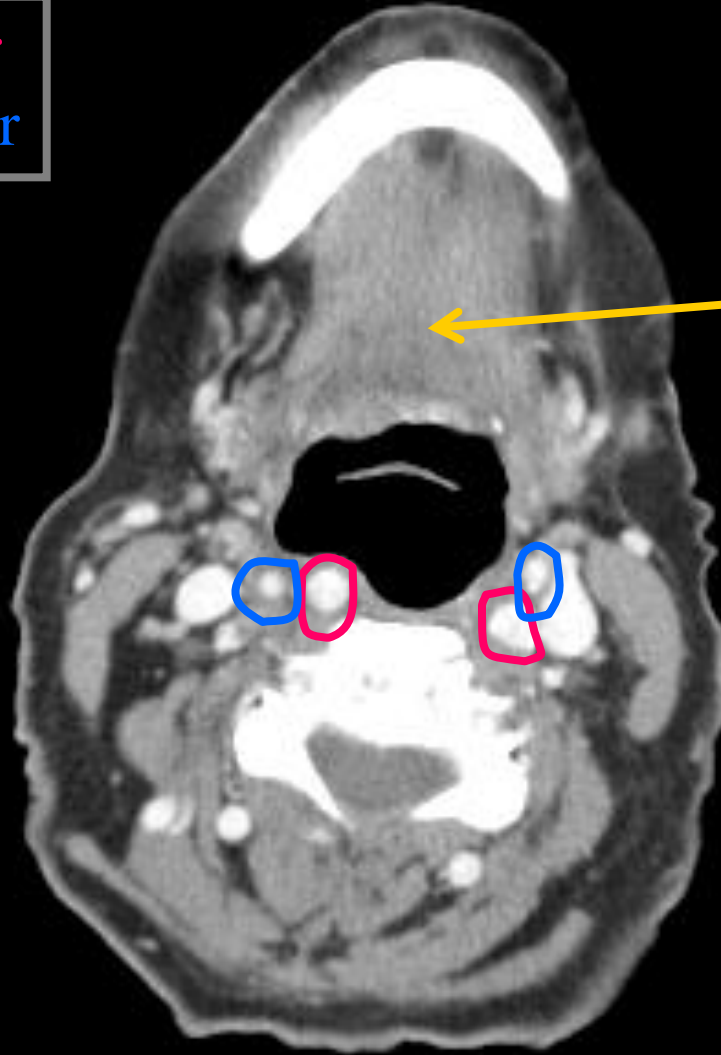




Digastrik kas

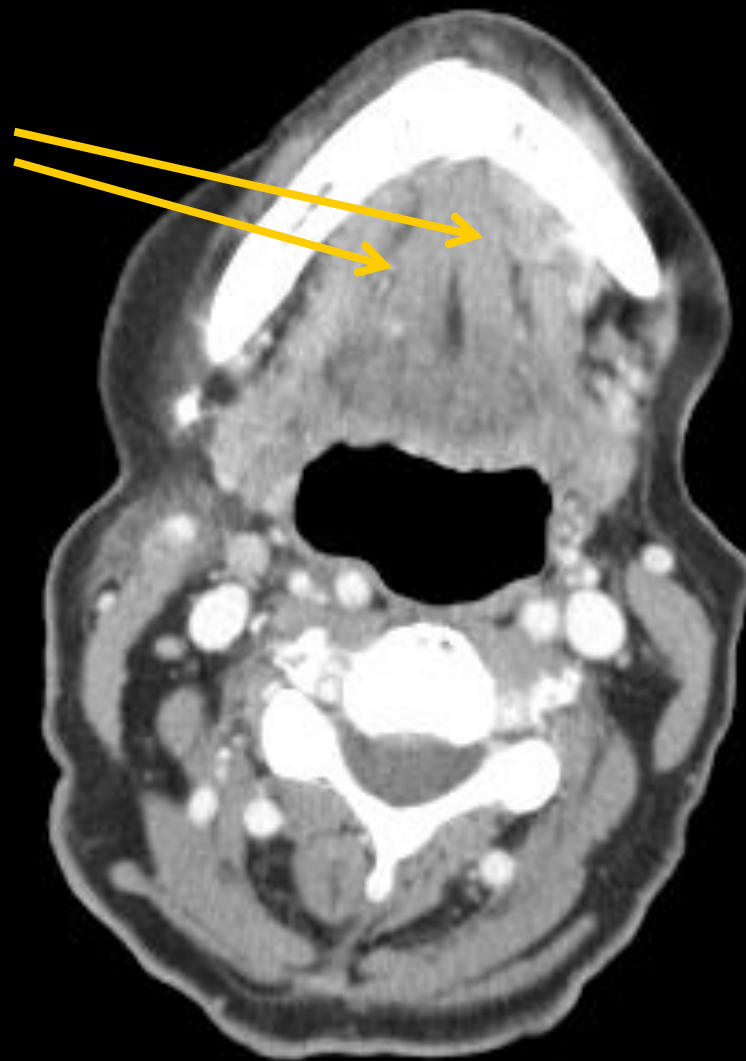

İnternal karotid arter  
External karotid arter

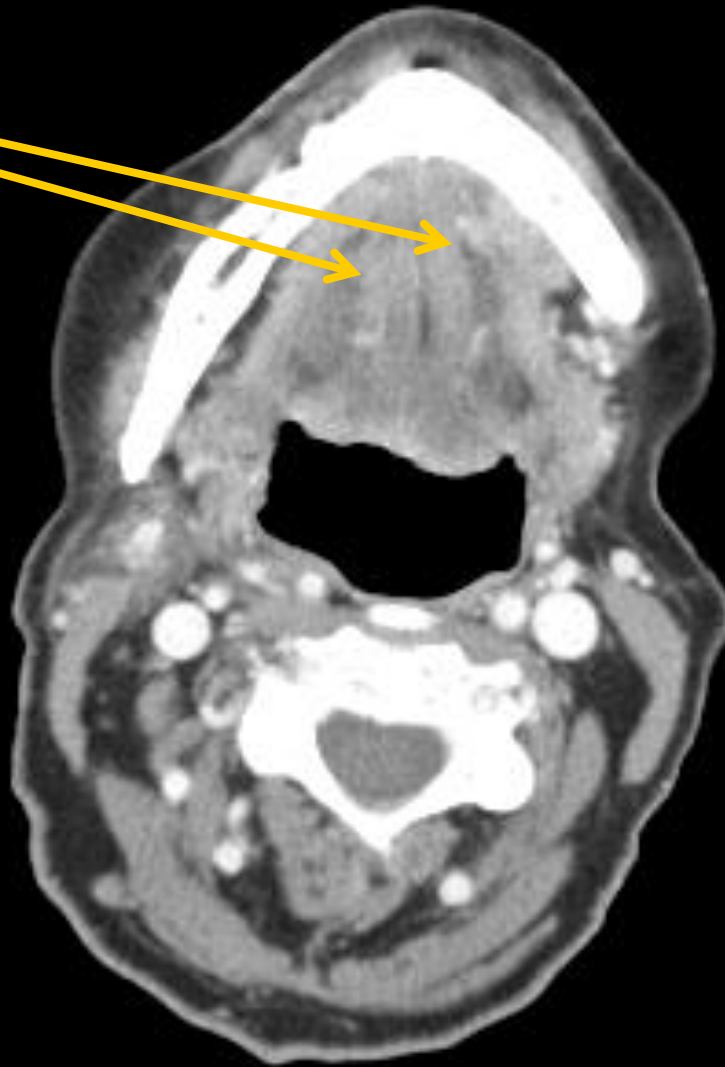


Mylohyoid kası

Geniohyoid kası



Genioglossus kası

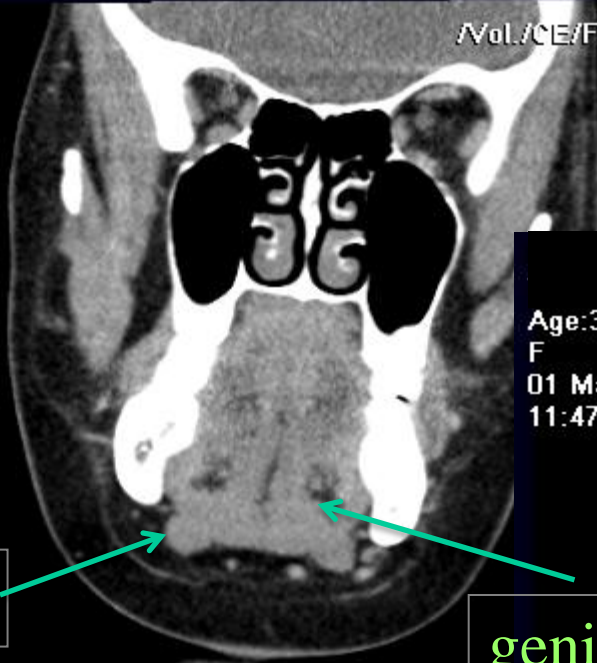


S AKDENIZ UNIV.TIP FAK.HASTANE

CT

/Vol./CE/FC04/ORG/

Age:31 years  
F  
01 May 2006  
11:47:19

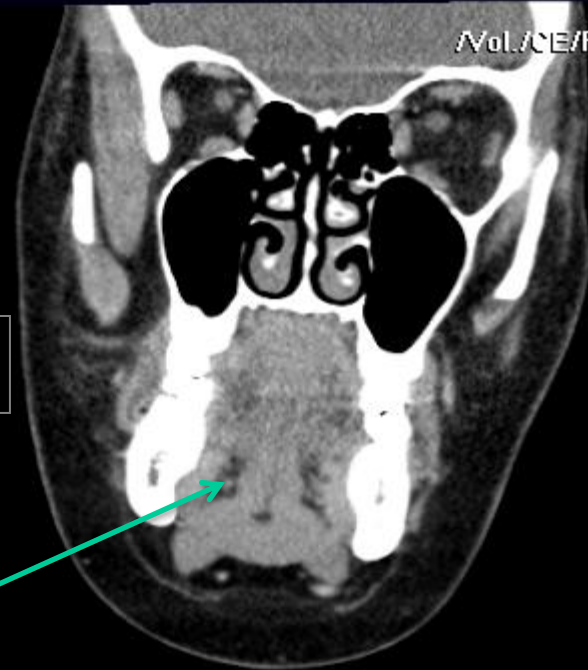


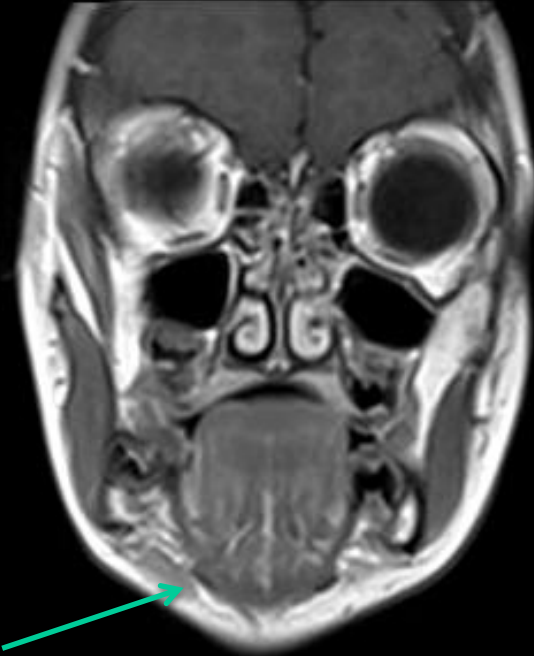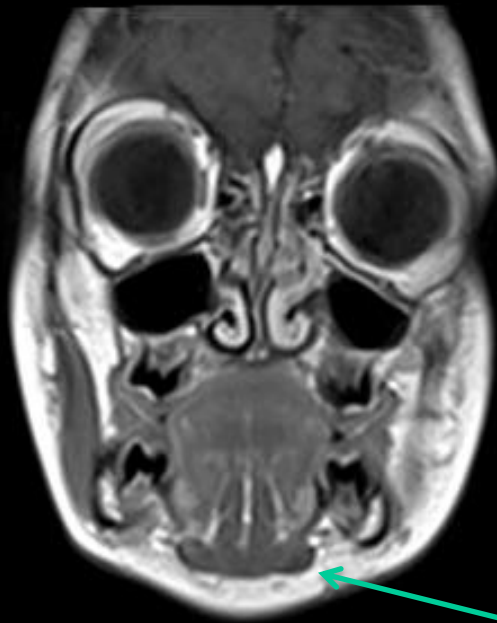
S AKDENIZ UNIV.TIP FAK.HASTANE

CT

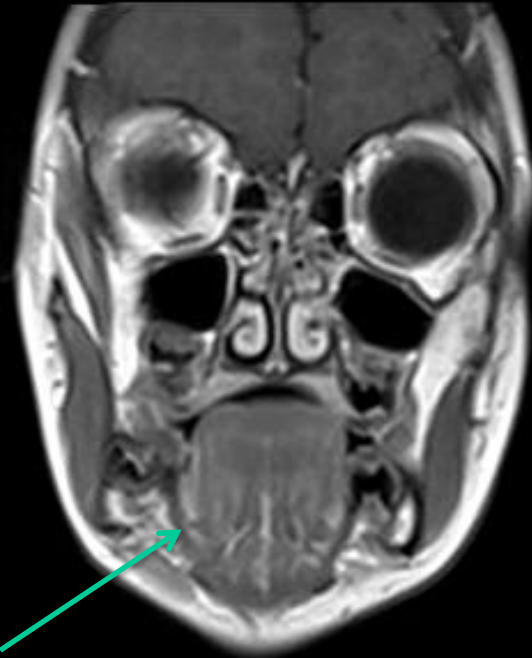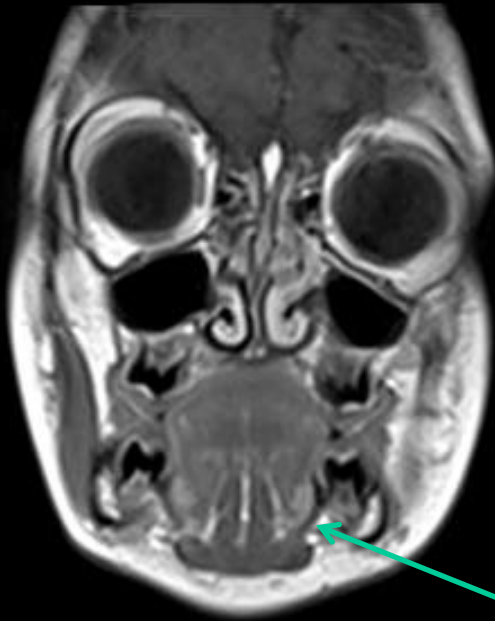/Vol./CE/FC04/ORG/

Age:31 years  
F  
01 May 2006  
11:47:19



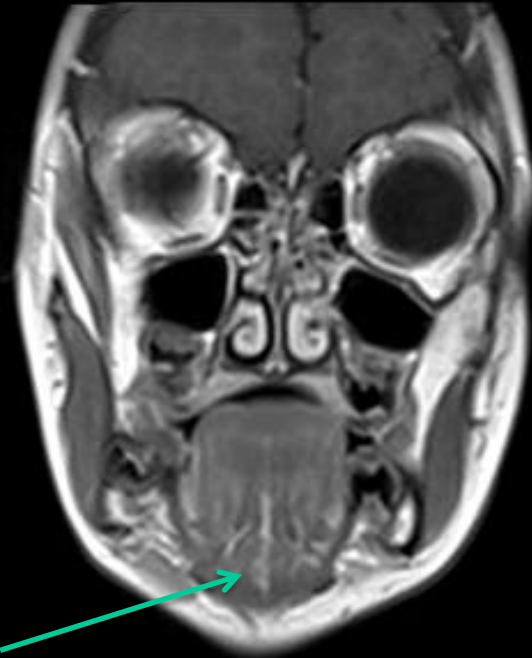
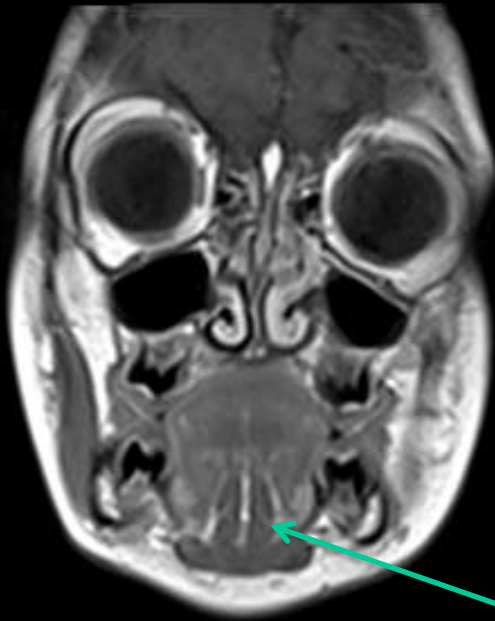
digastrik

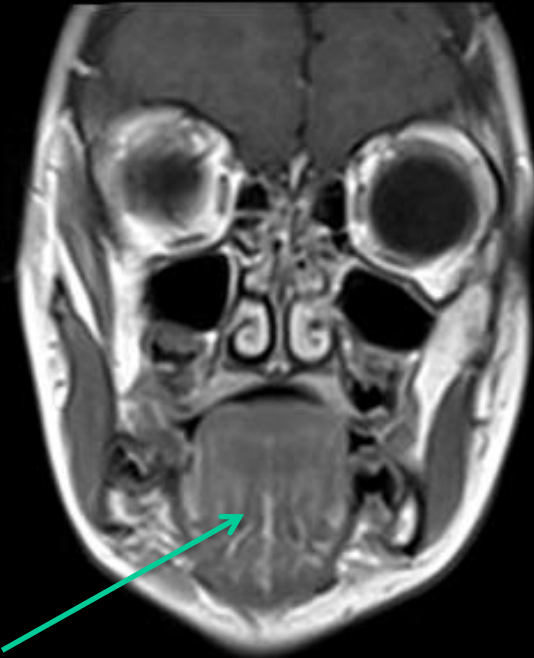
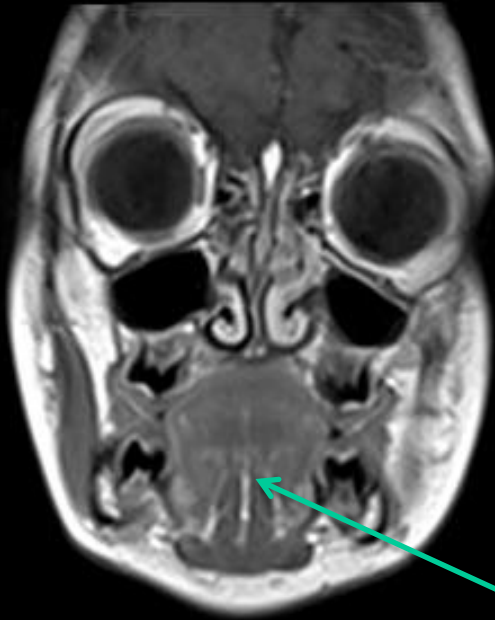
Mylohyoid



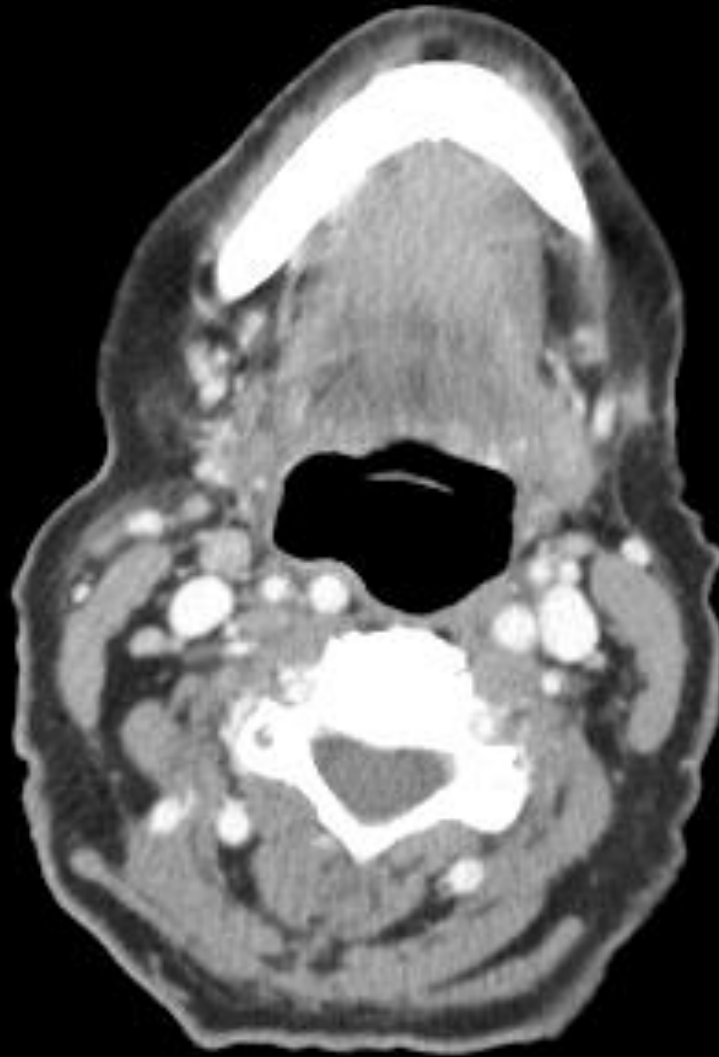


geniohyoid

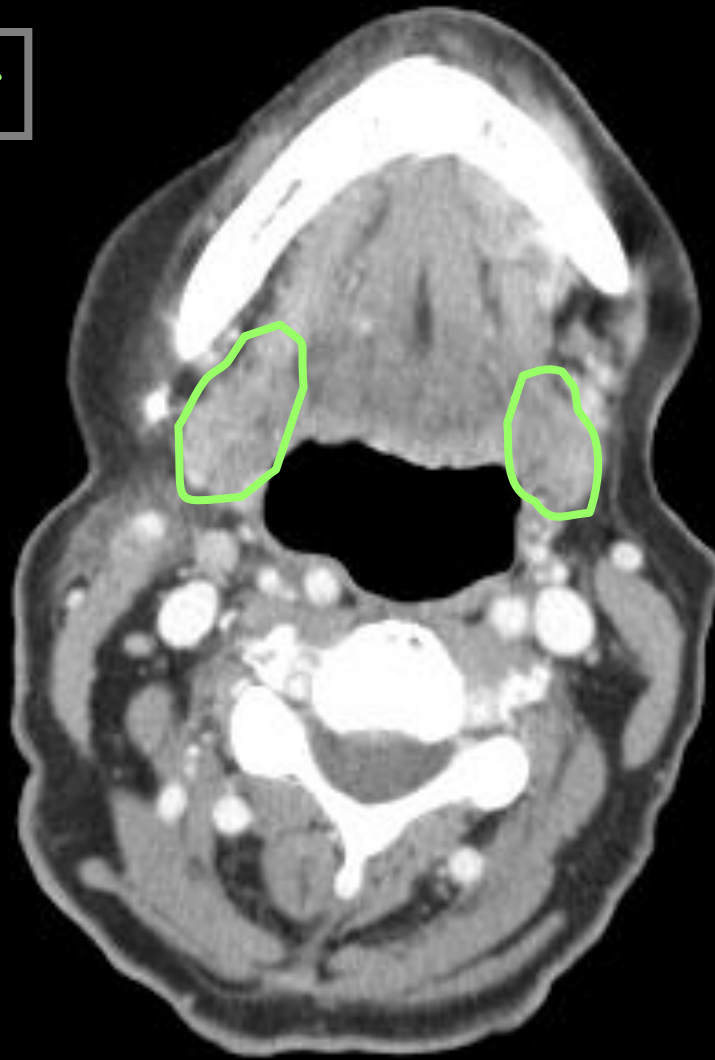

Genioglossus

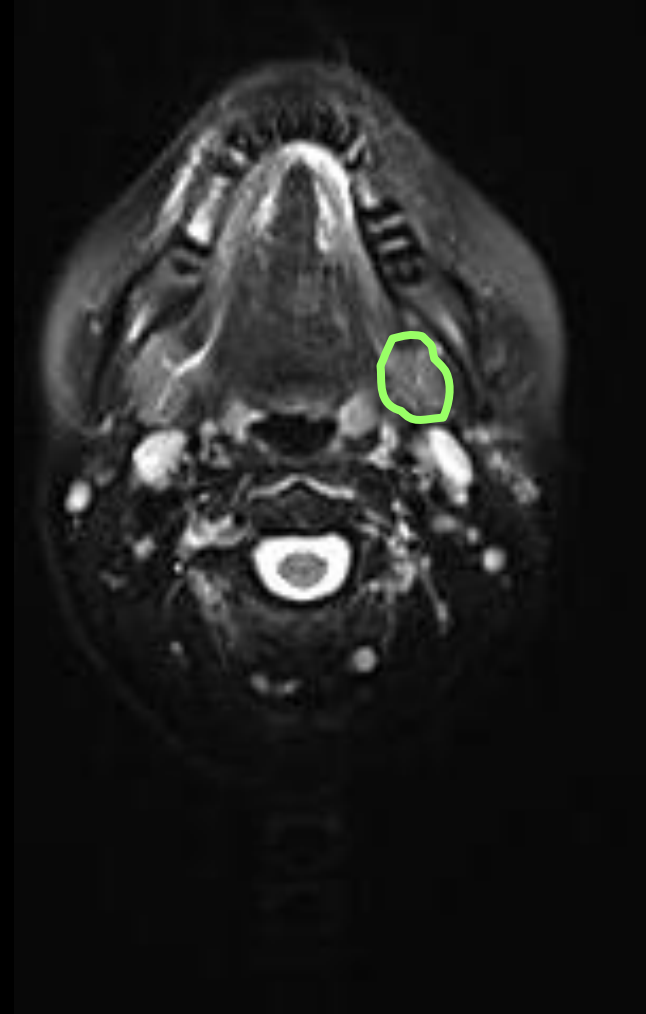
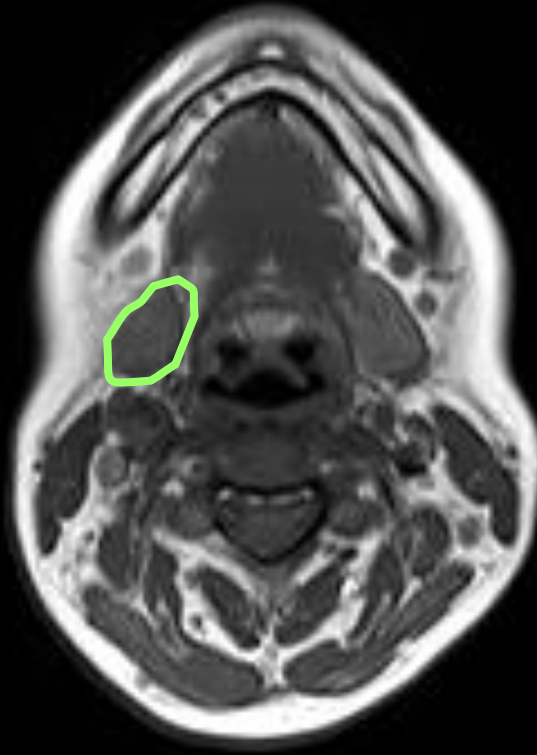Lenf nodları

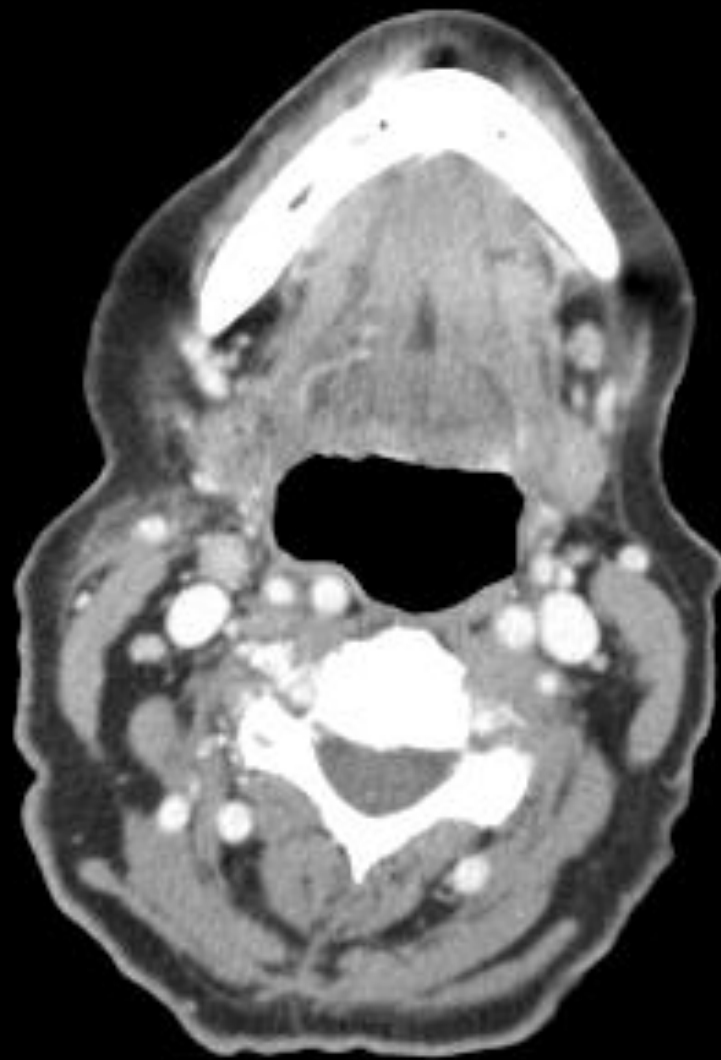


# Submandibuler bezler

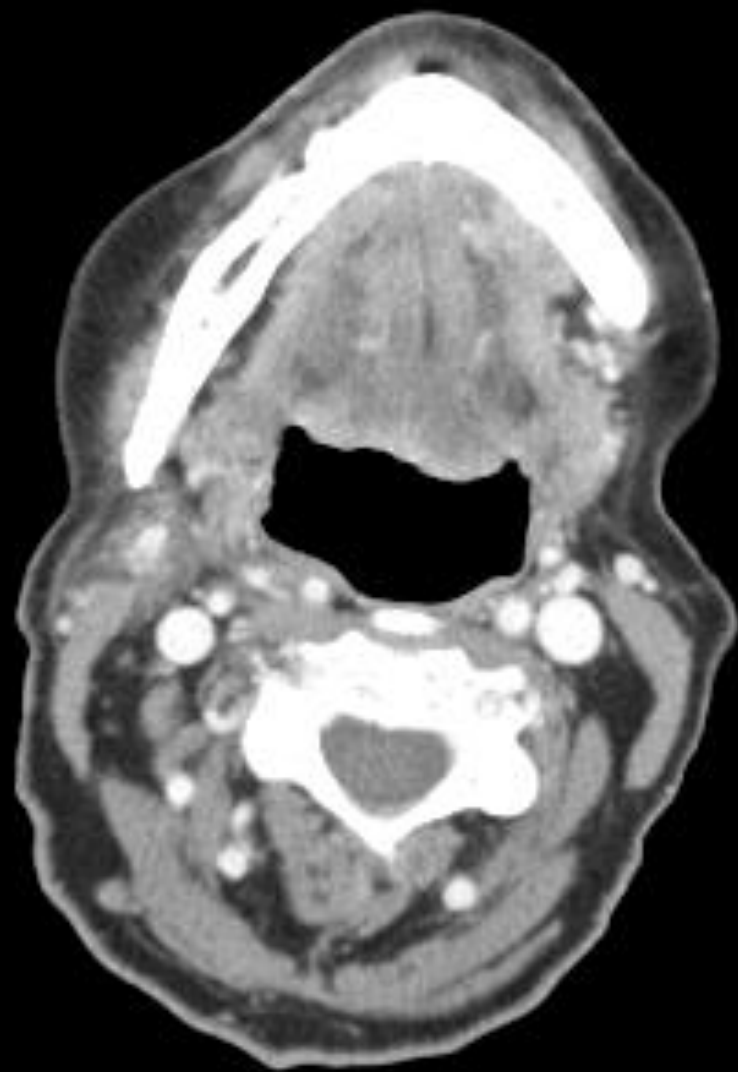


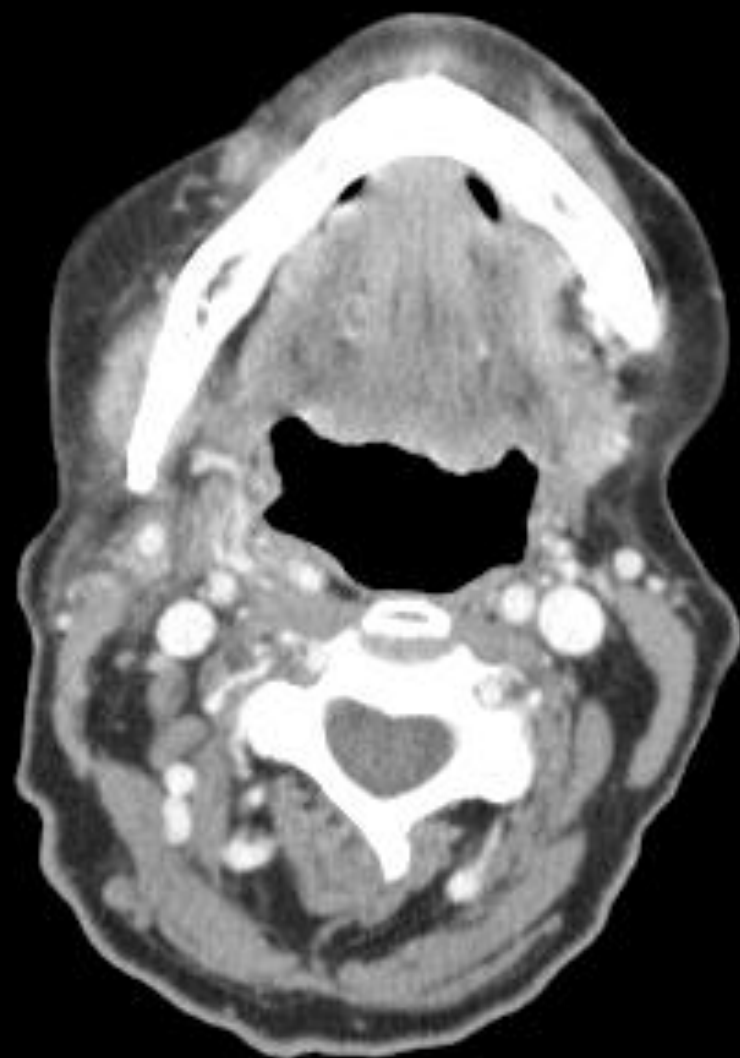
Submandibuler bezler  
T1 ve T2 MR kesitleri





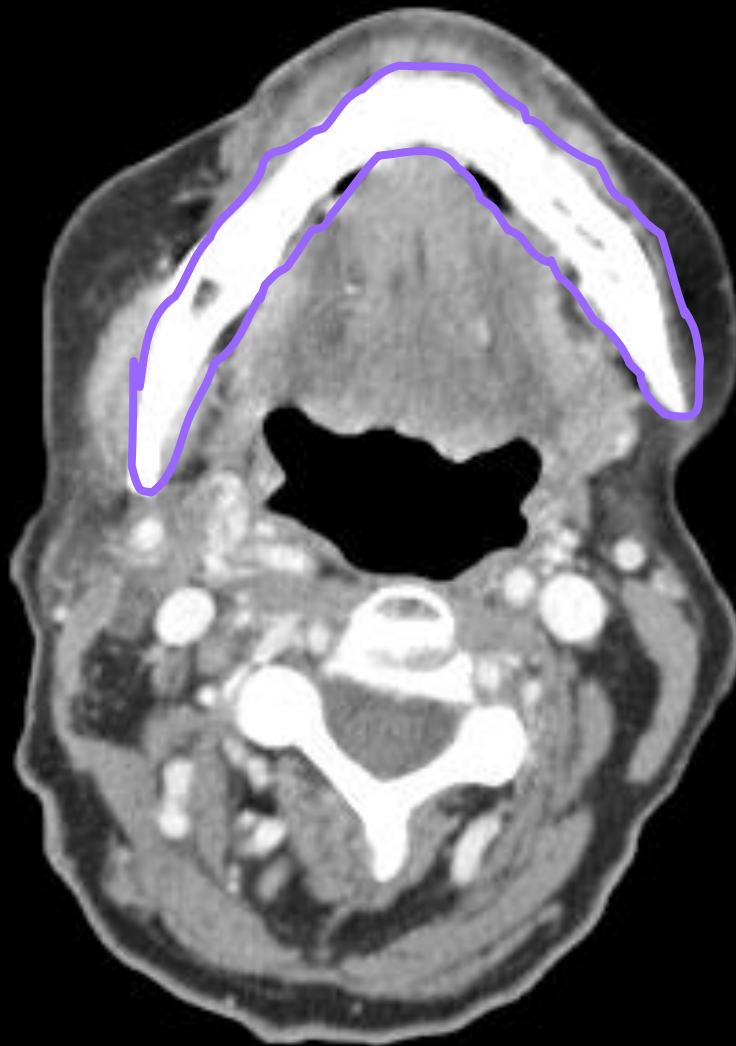
Orofarinks

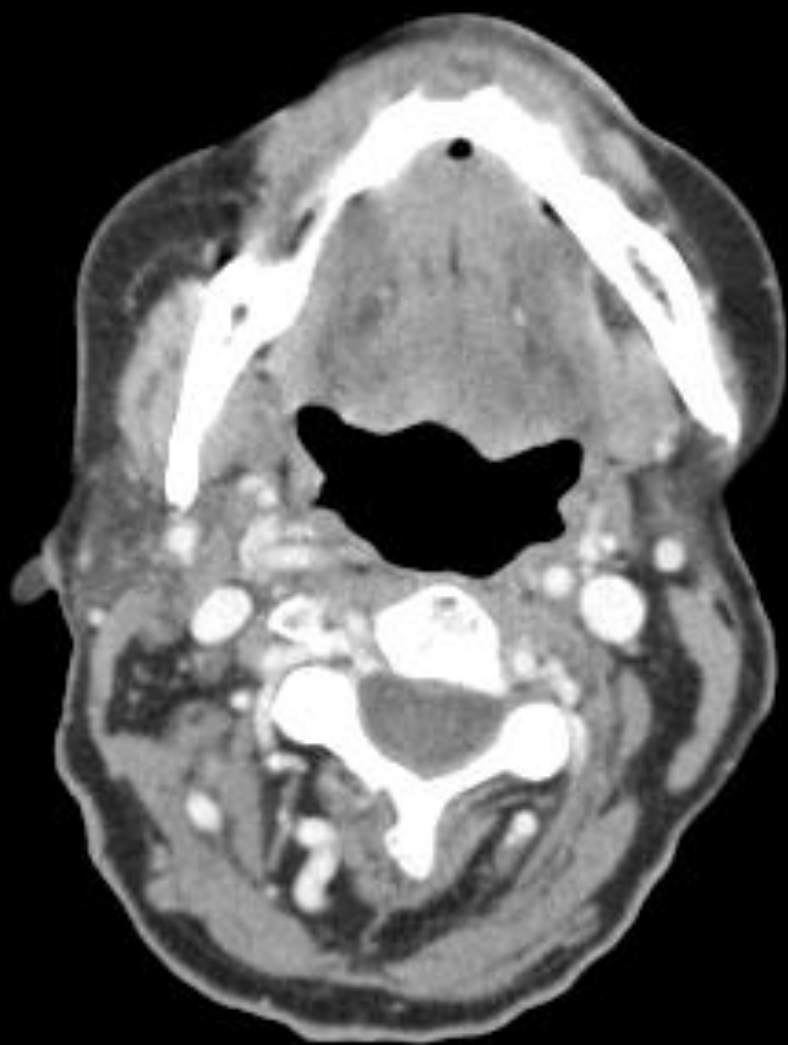


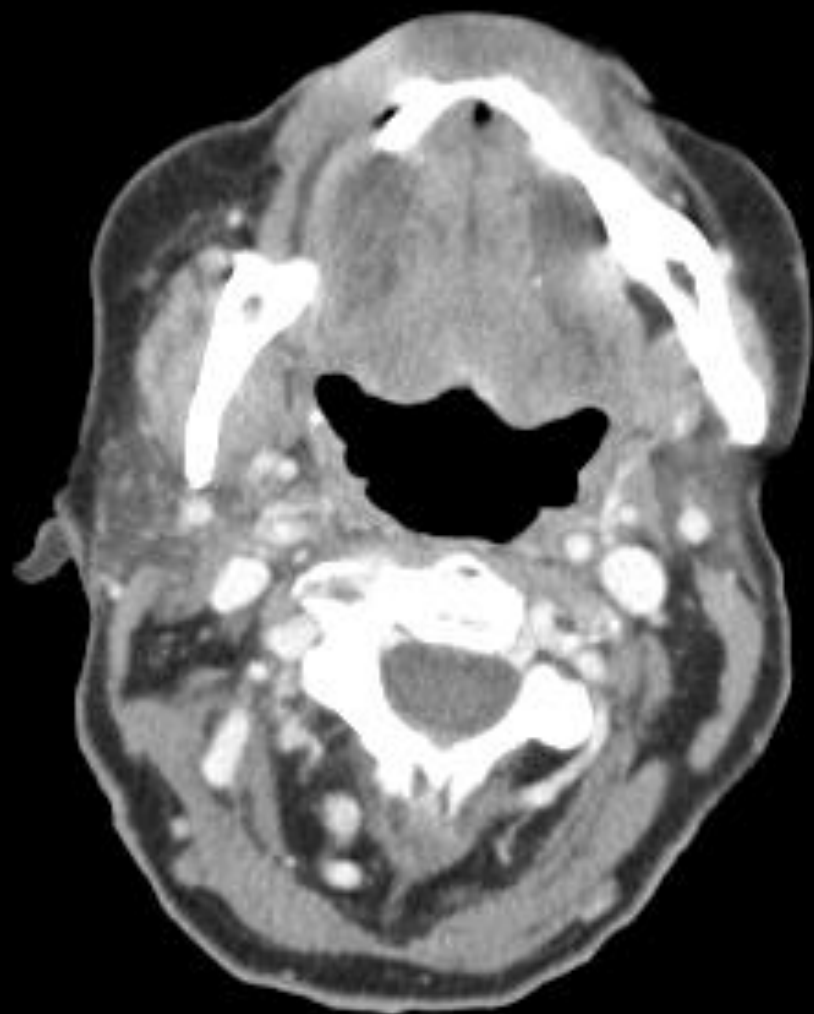




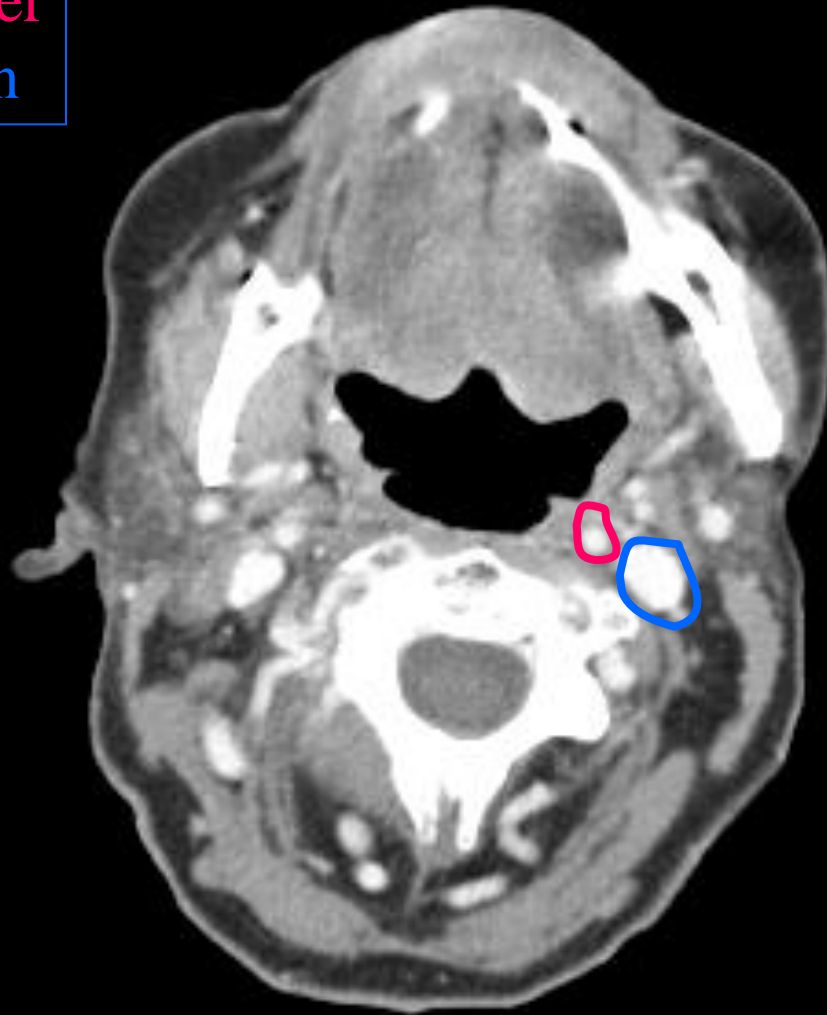
mandibula





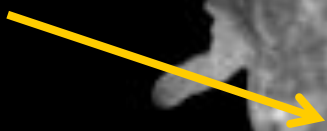


Internal karotid arter  
Internal jugular ven

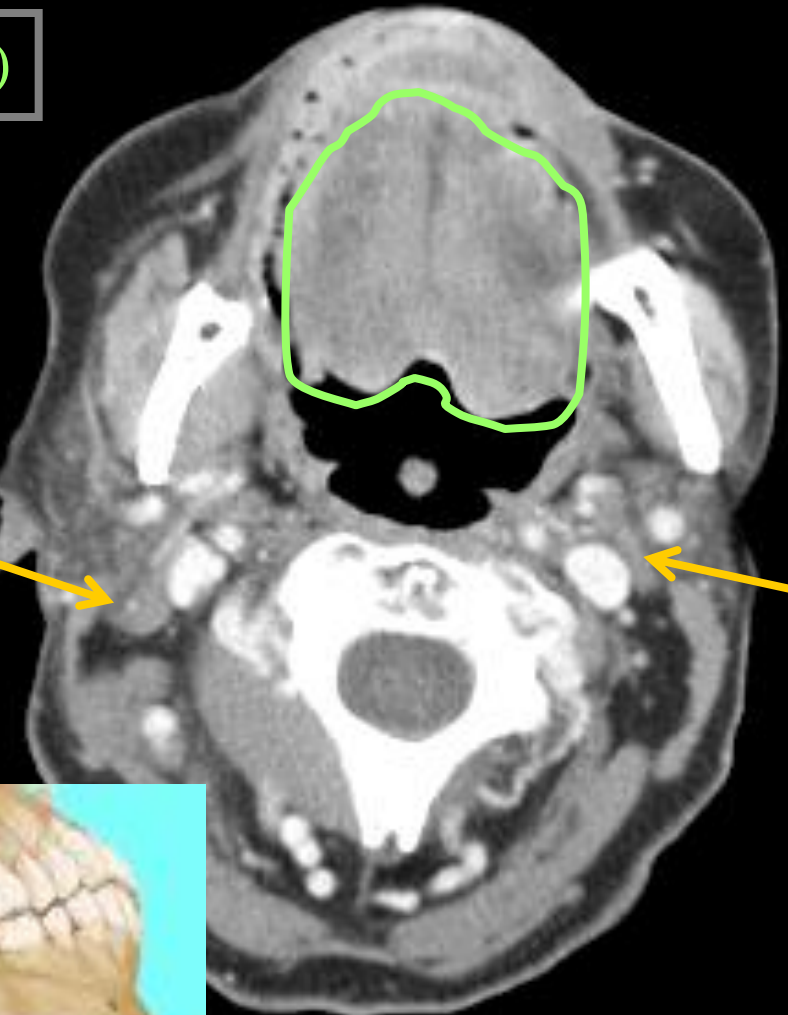
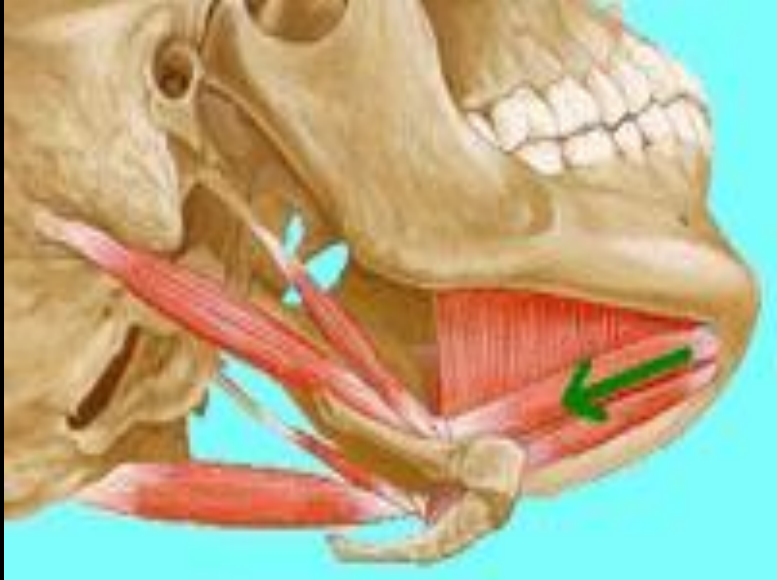
Dil (intrensek kaslar)

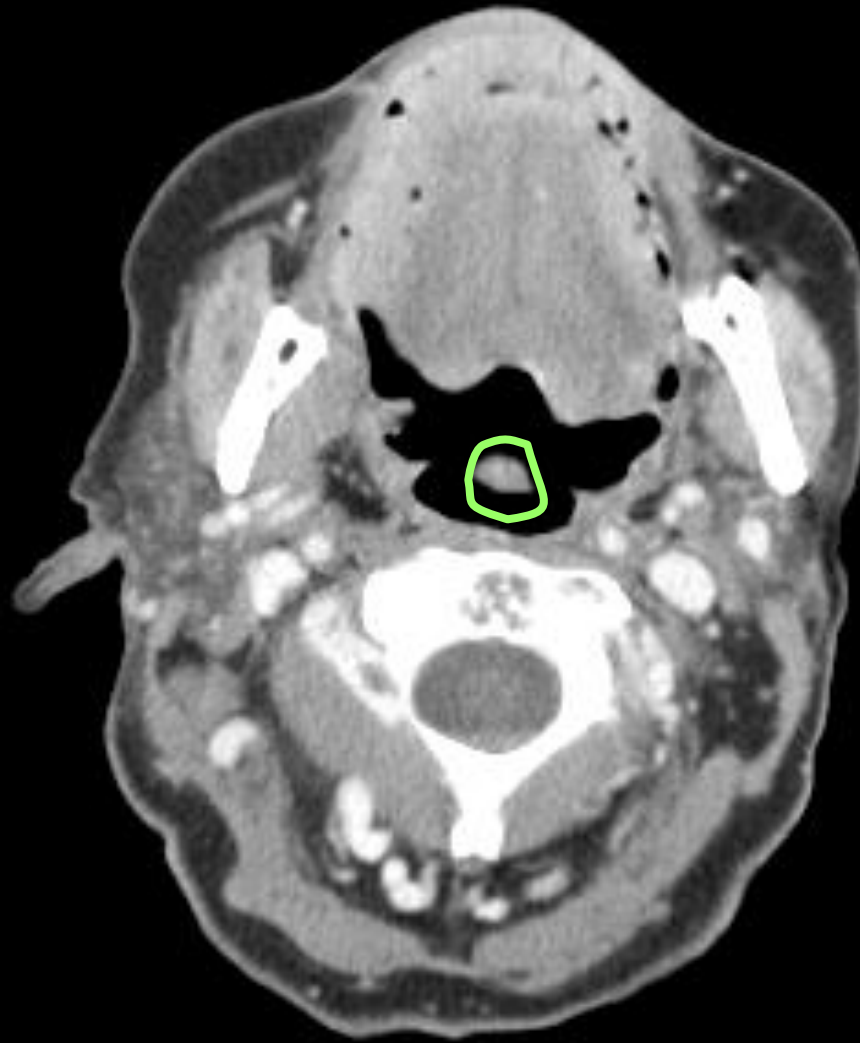
Digastrik kas



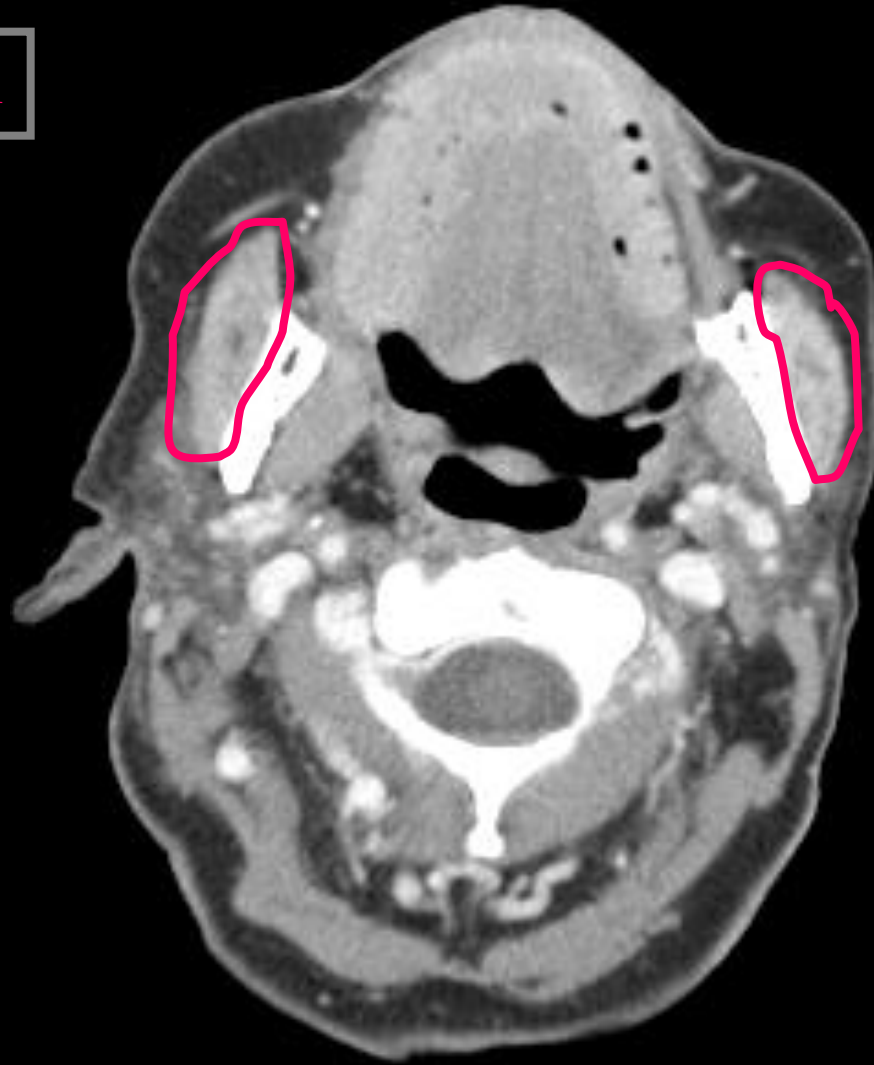Digastrik kas

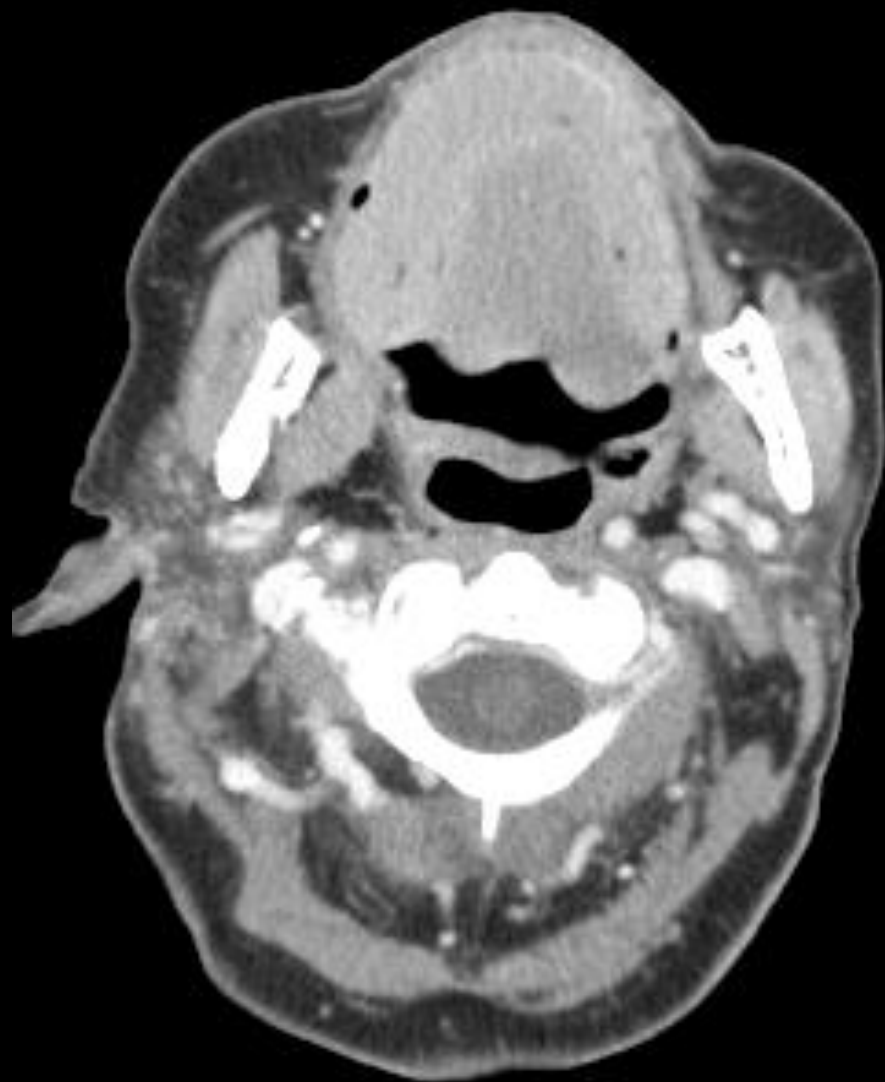


uvula

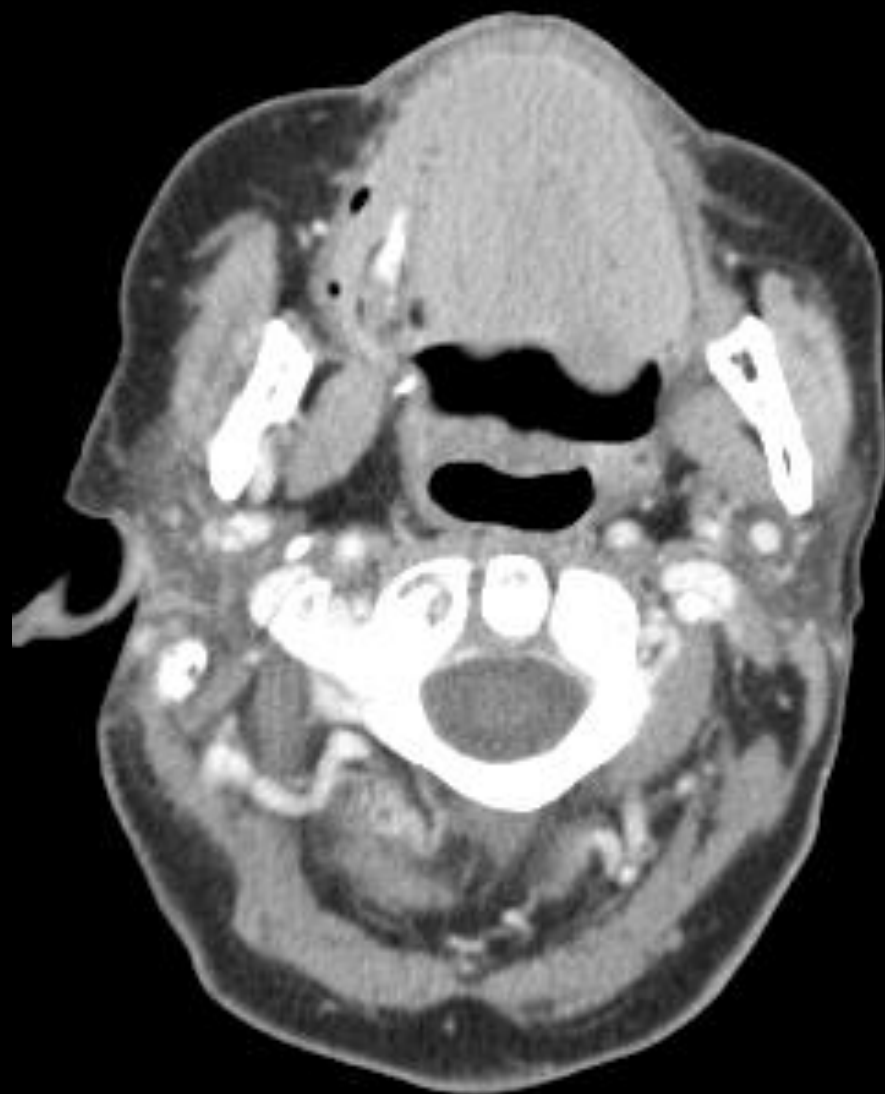


Masseter kasları

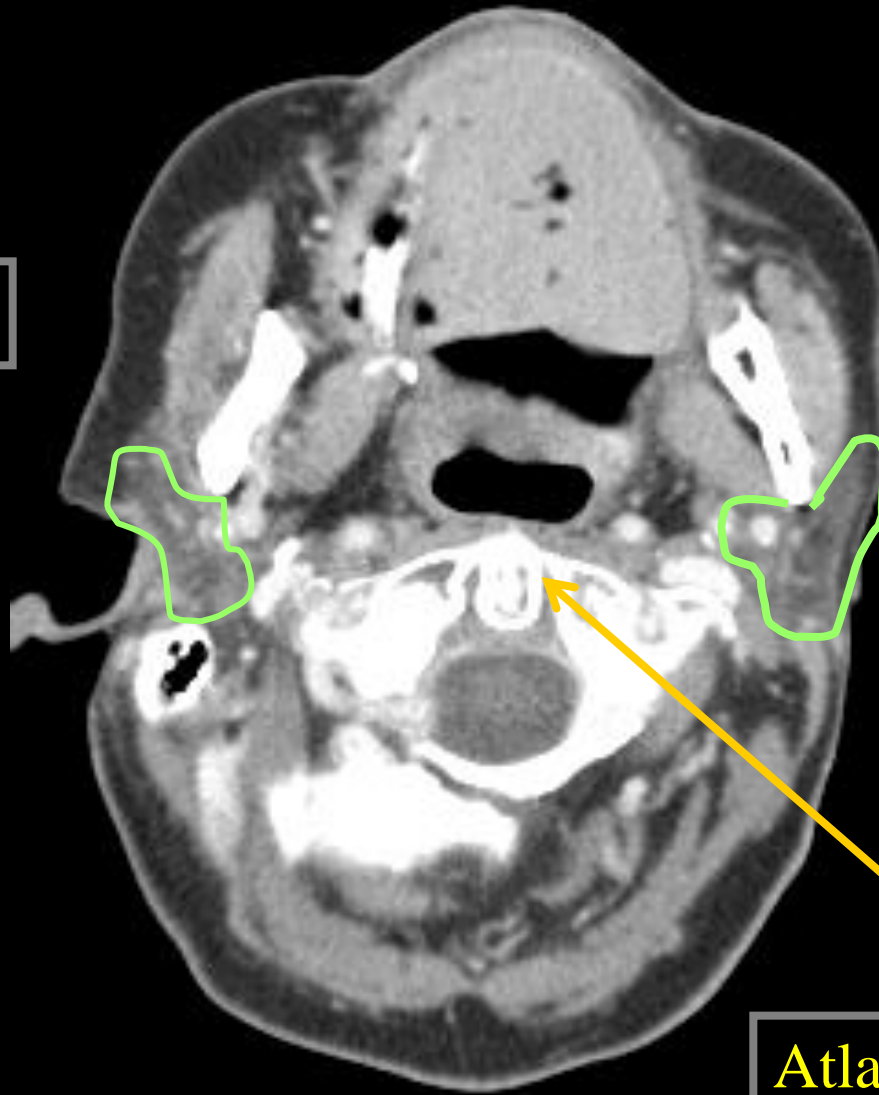








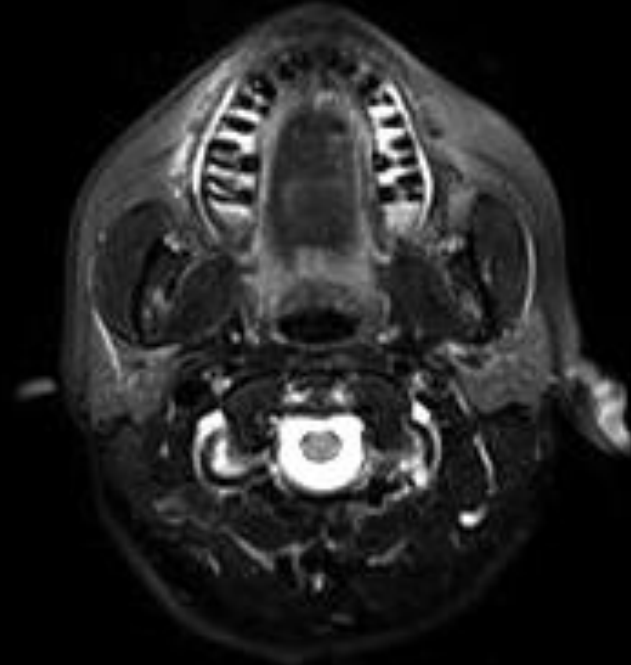
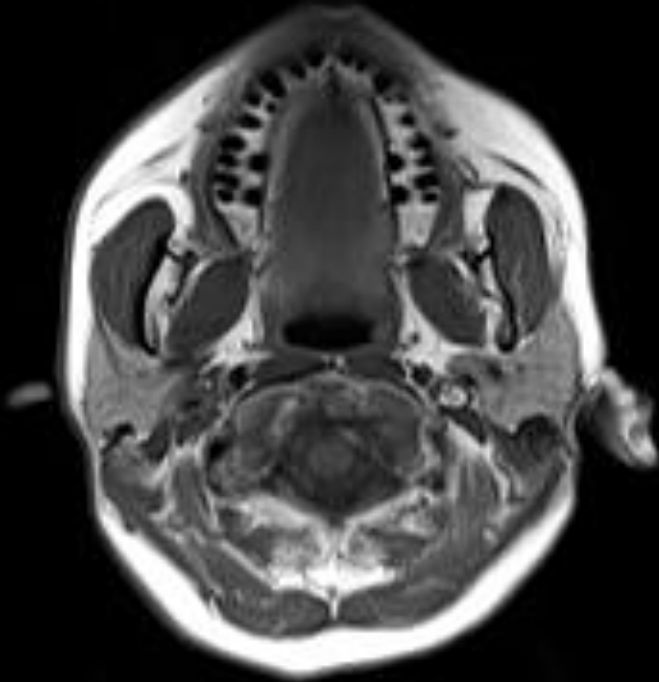
Parotis bezleri



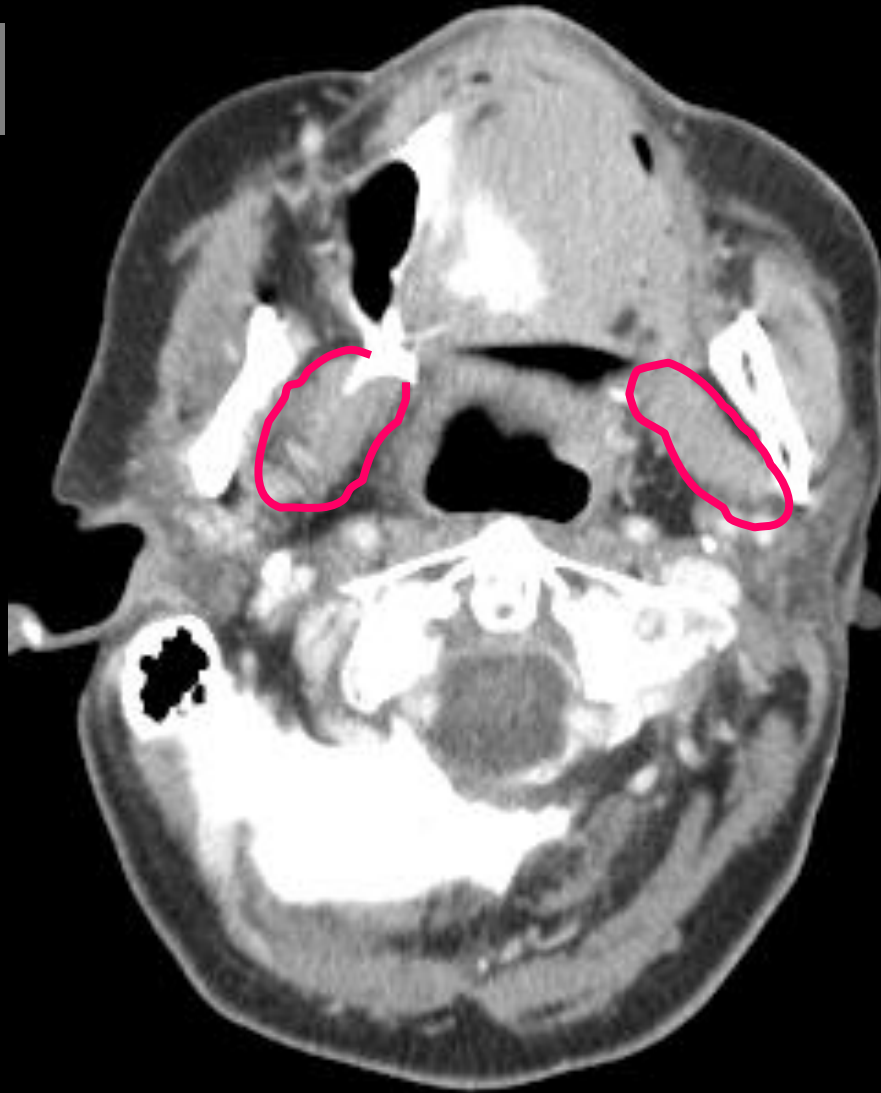
Atlantoaksiyel eklem

Parotis bezleri

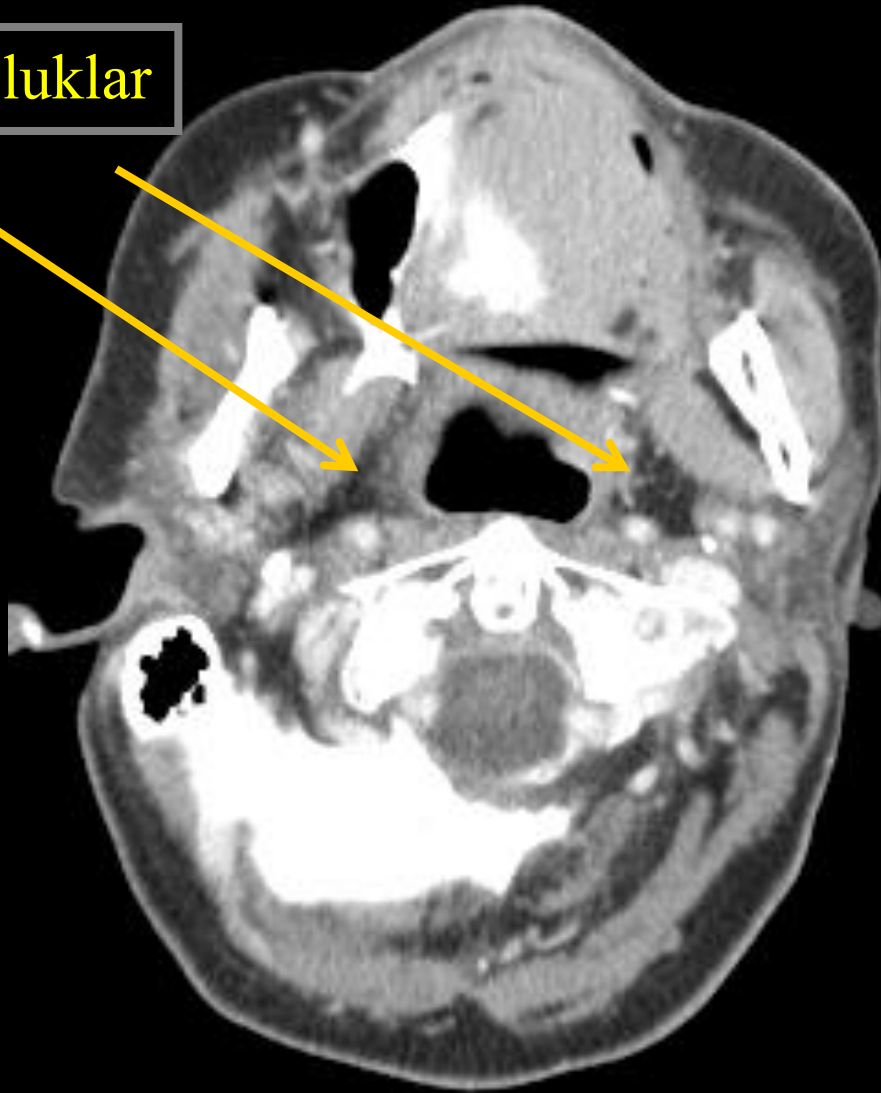
T1 ve T2/Yağ baskılı MR kesitleri



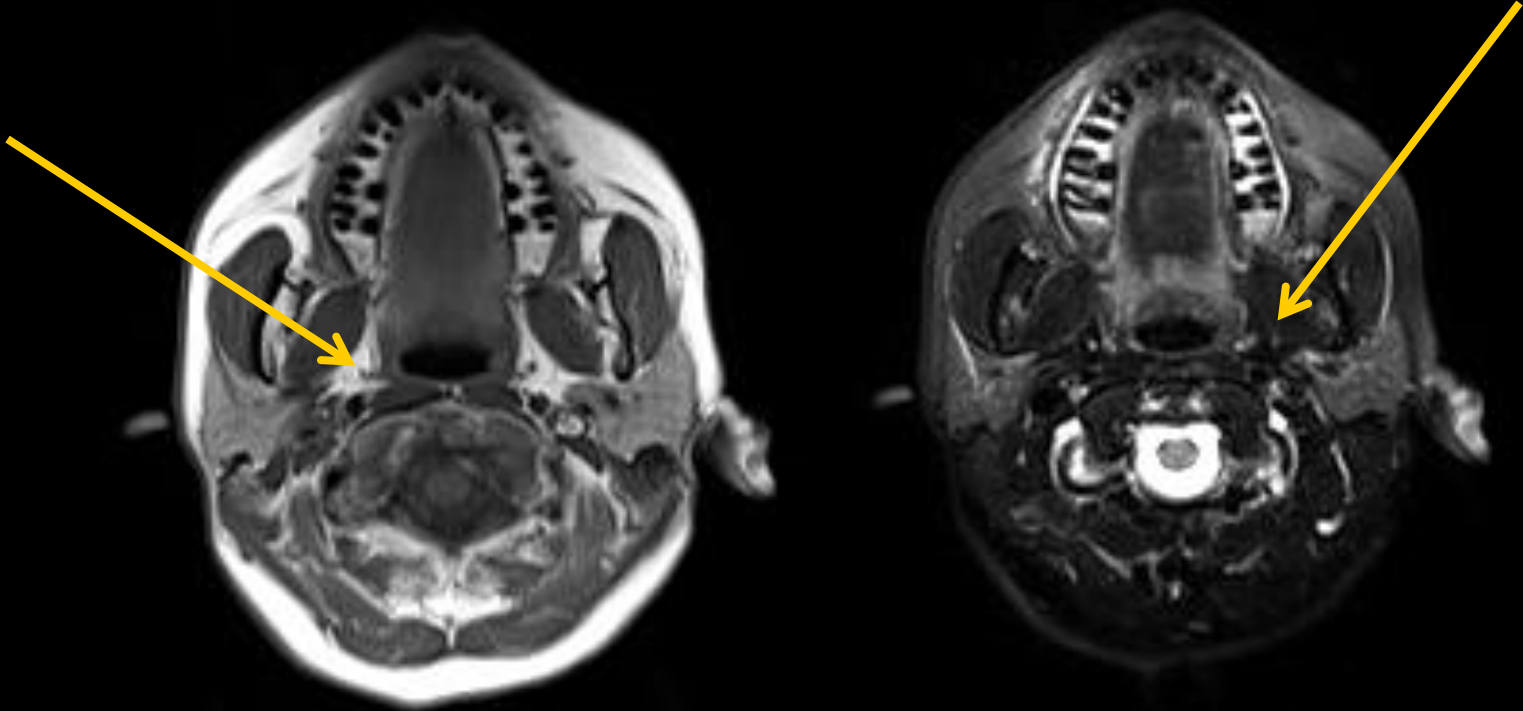
Pterygoid kaslar

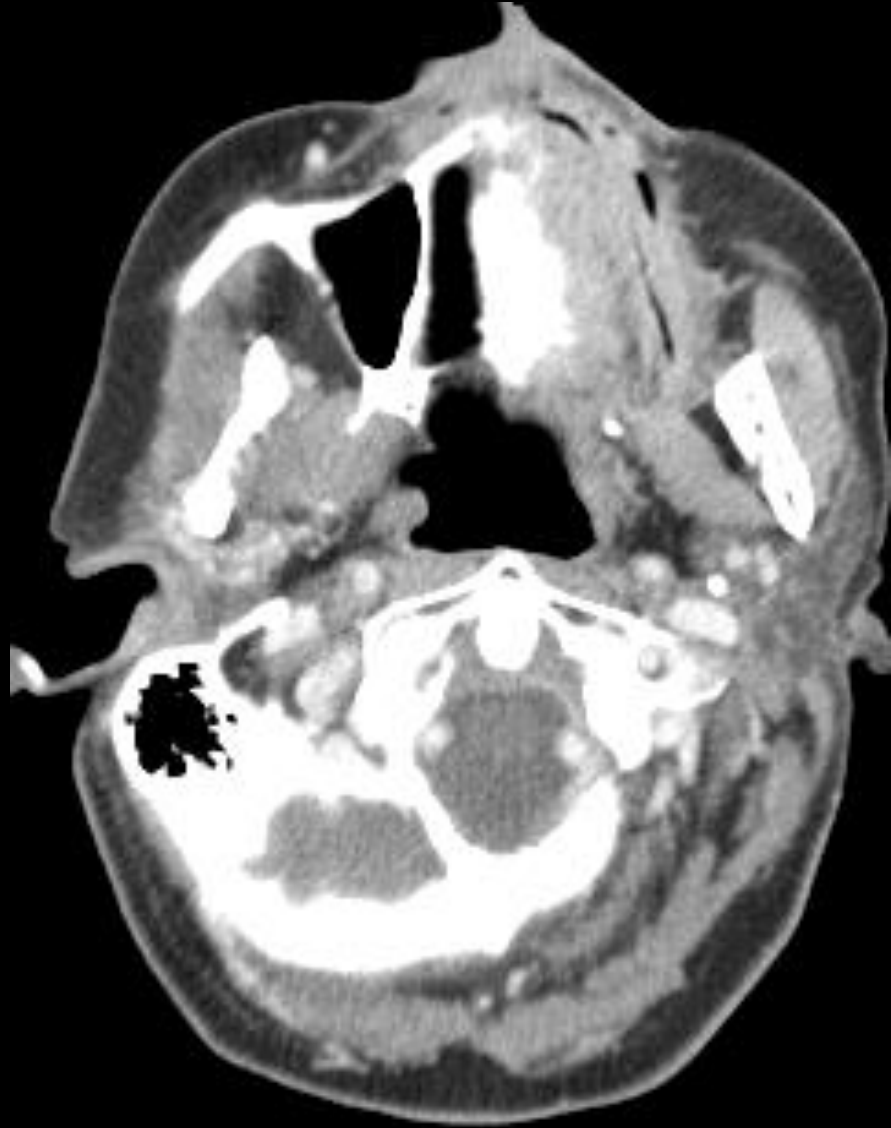

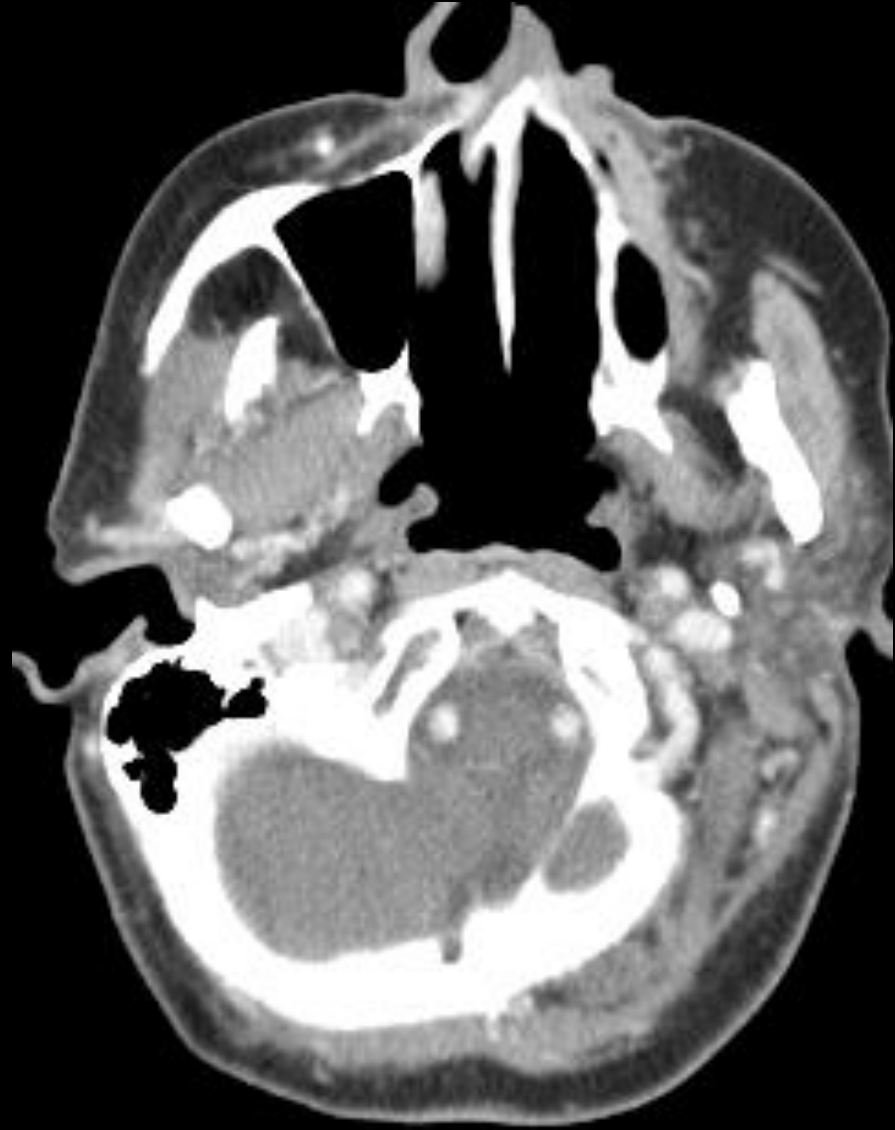
Parafaringeal boşluklar



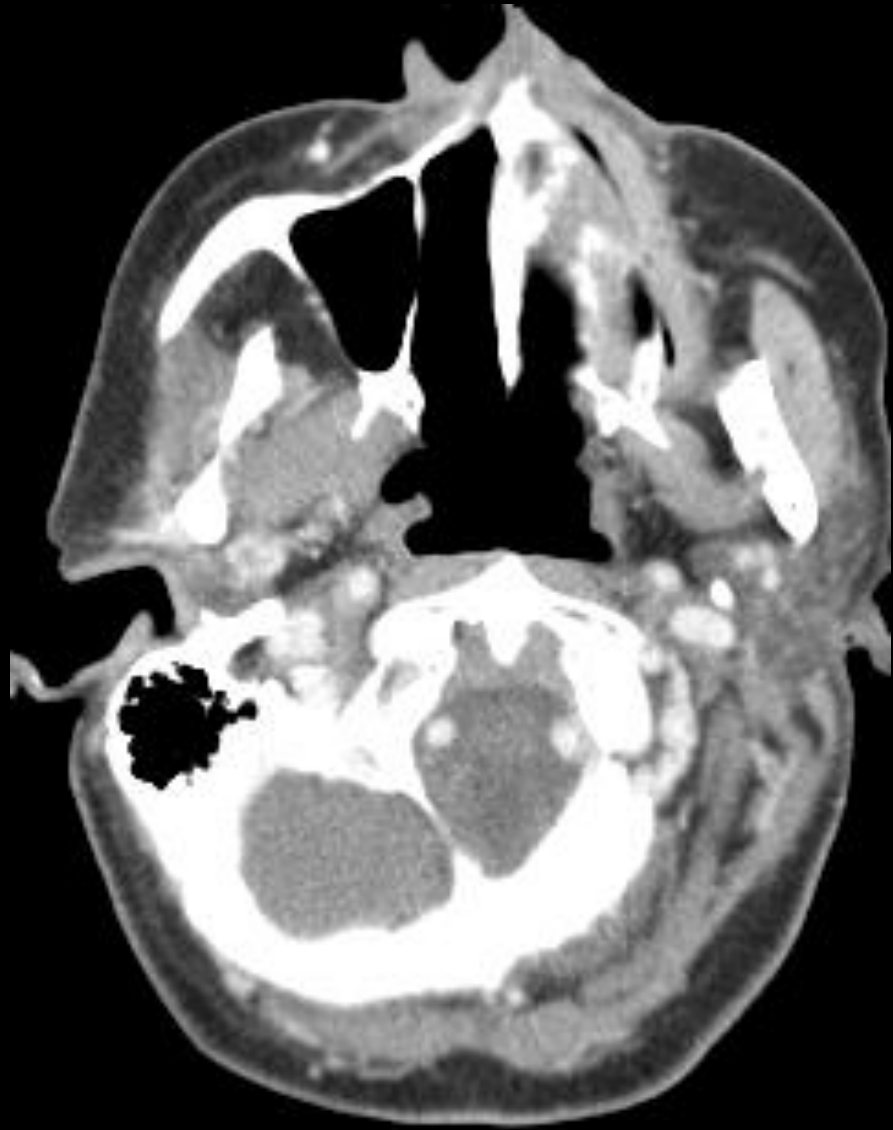Parafaringeal boşluklar  
T1 ve T2 MR kesitleri



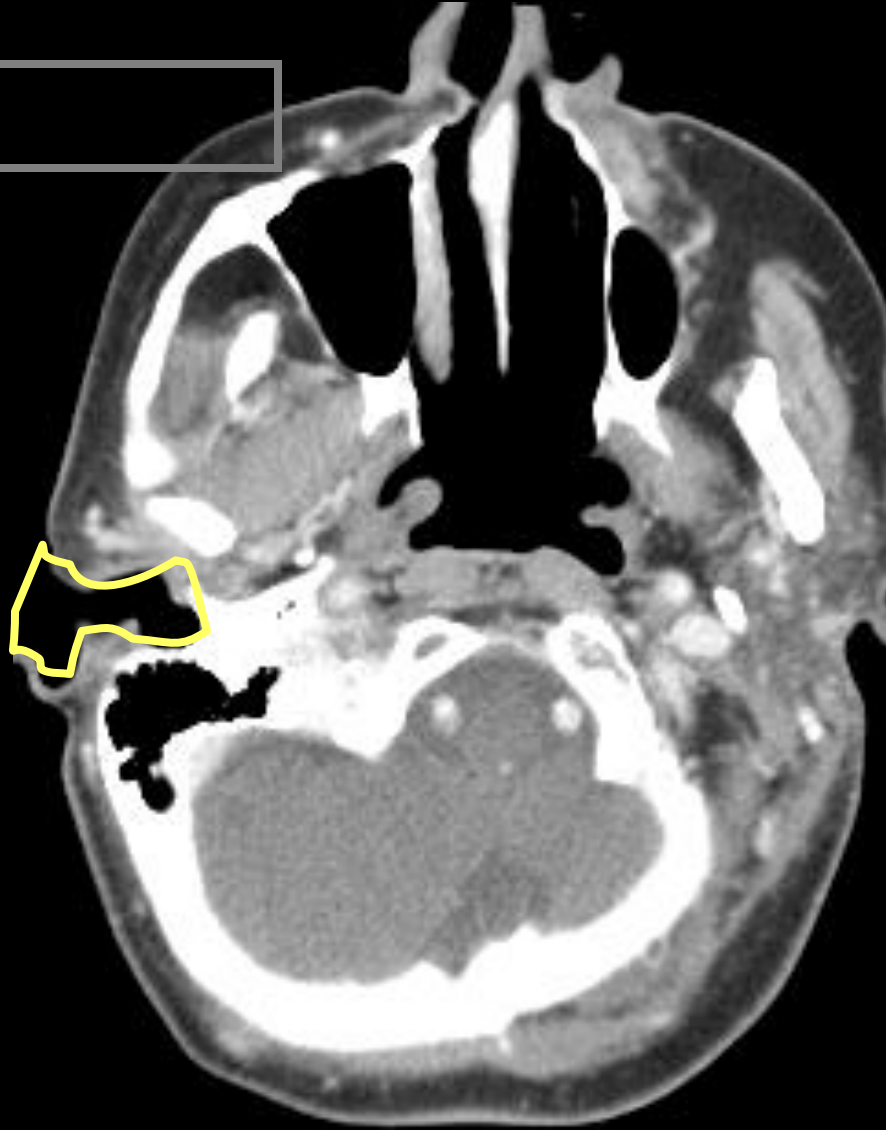


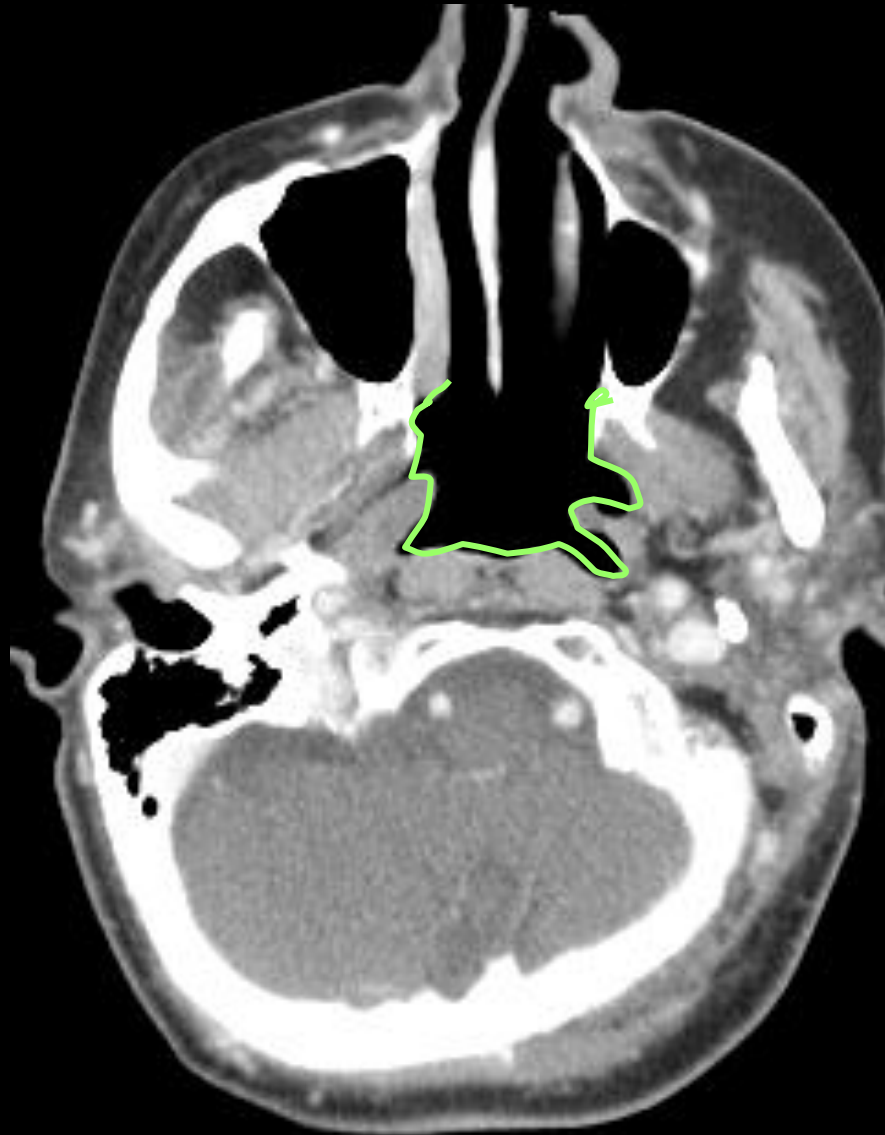




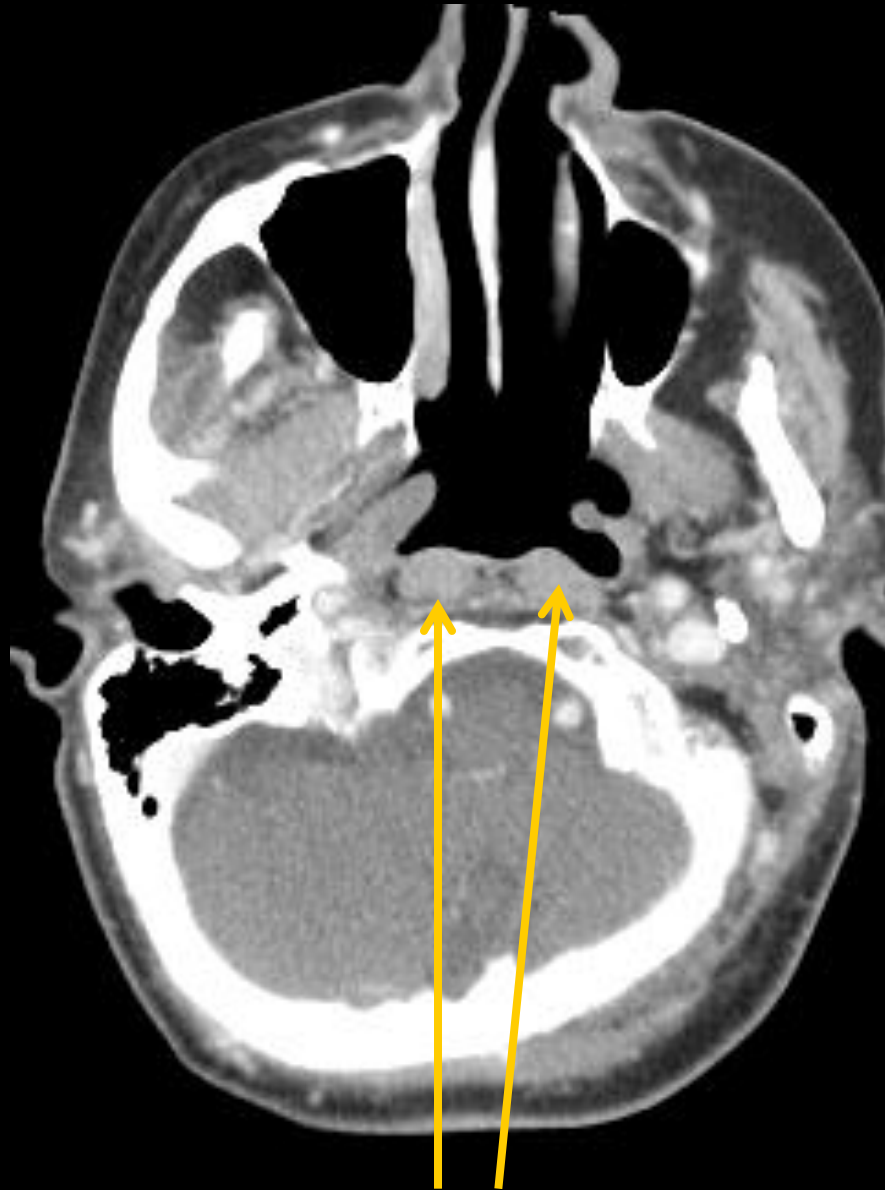
Dış kulak yolu

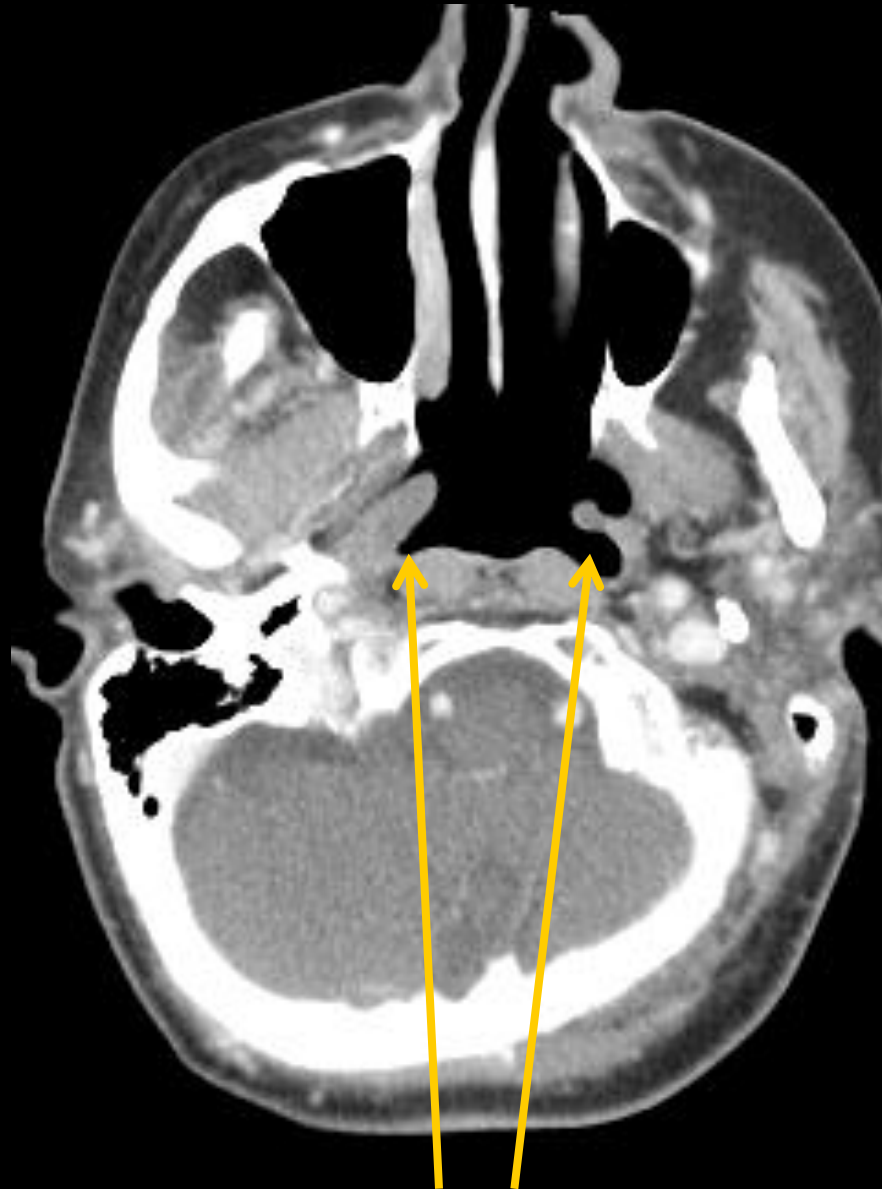




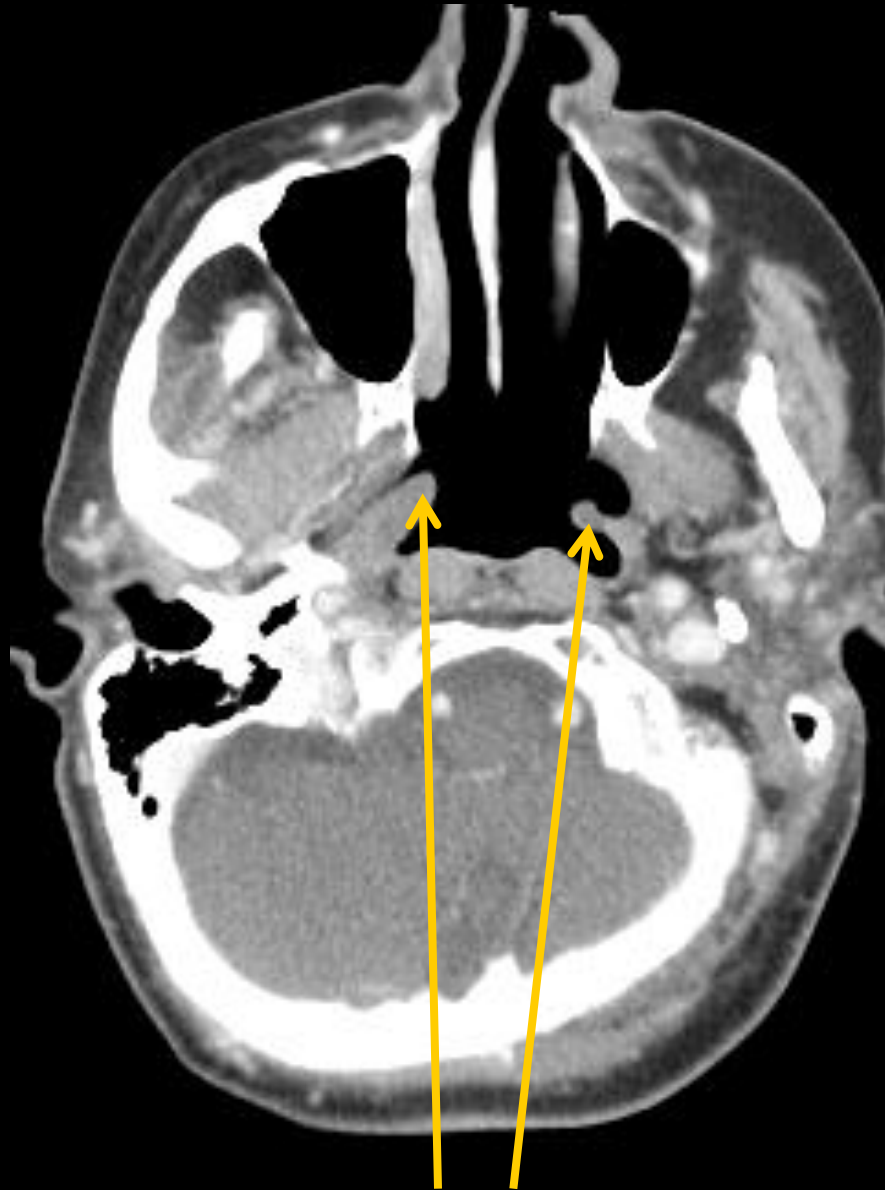
Nazofarinks



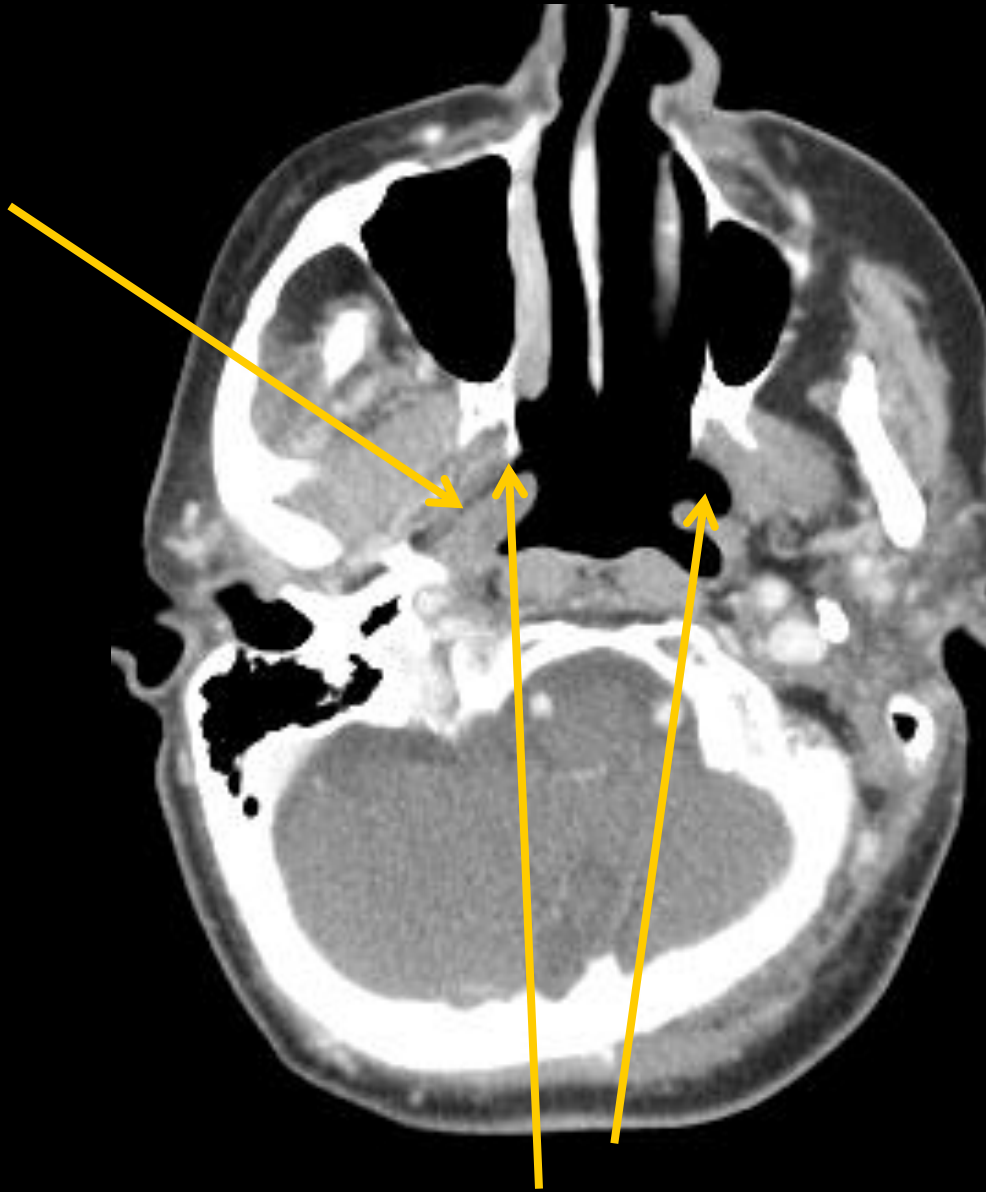
Longus capitis  
kası



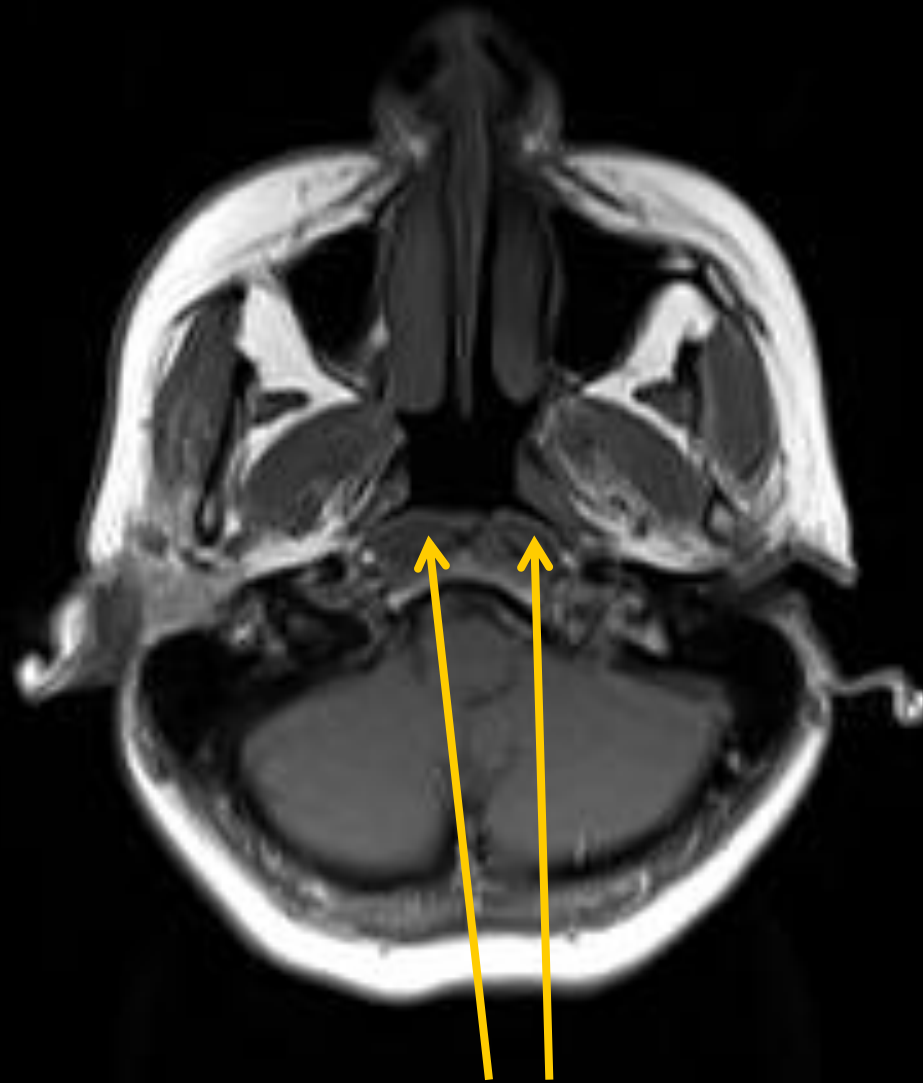
Rosenmuller  
fossa



Torus tubarius

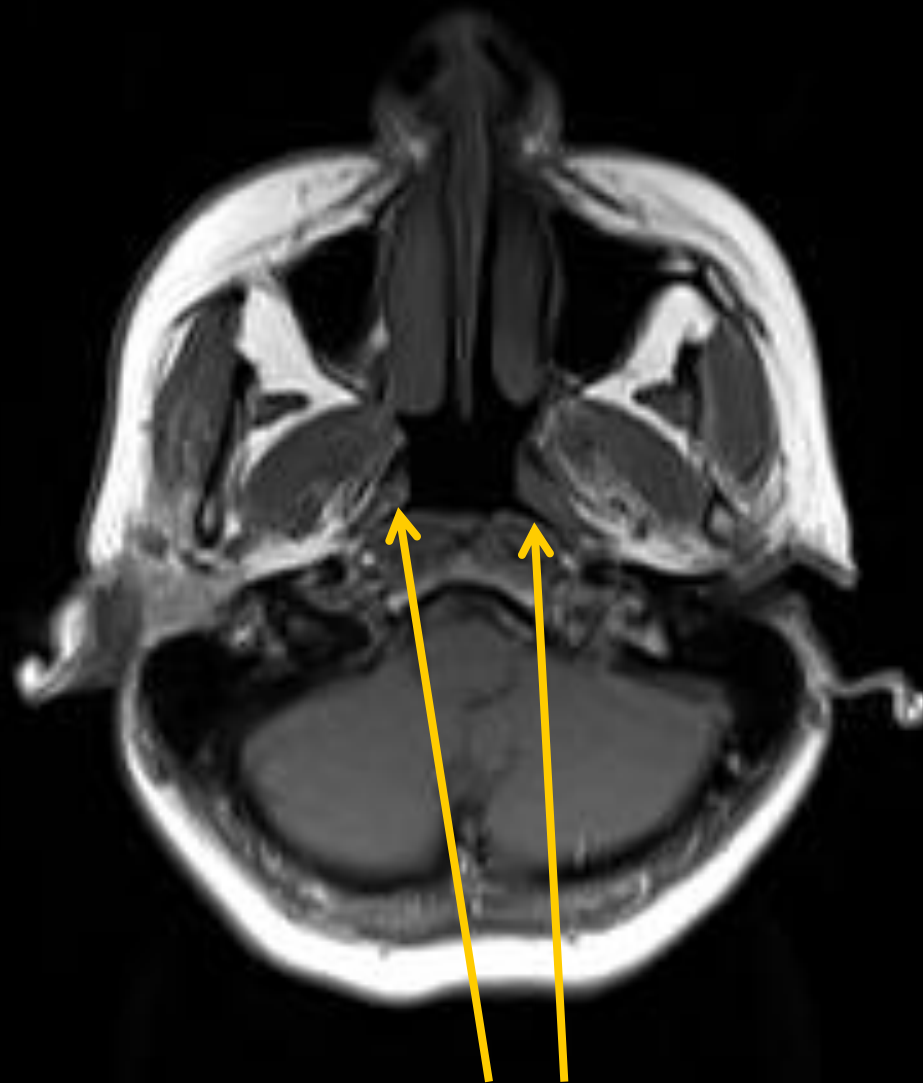


Östaki kanalı  
açılışı

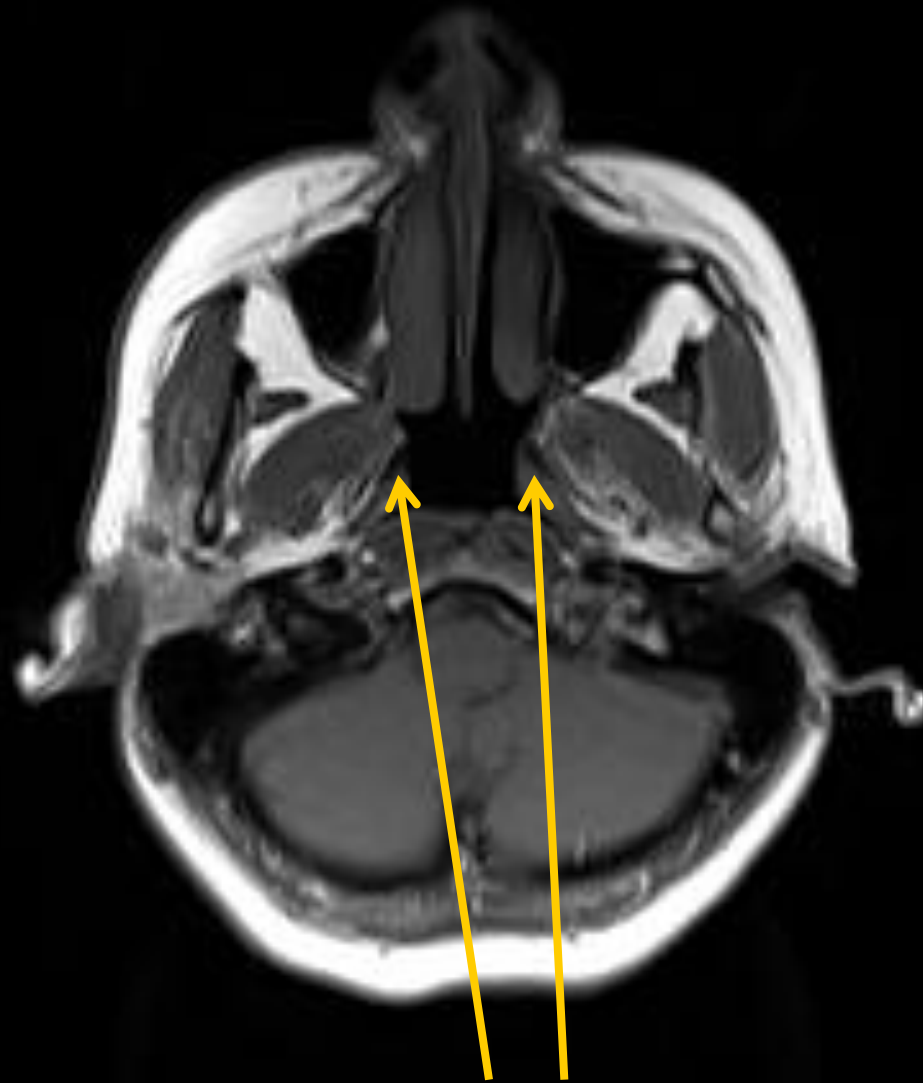


Longus capitis  
kası

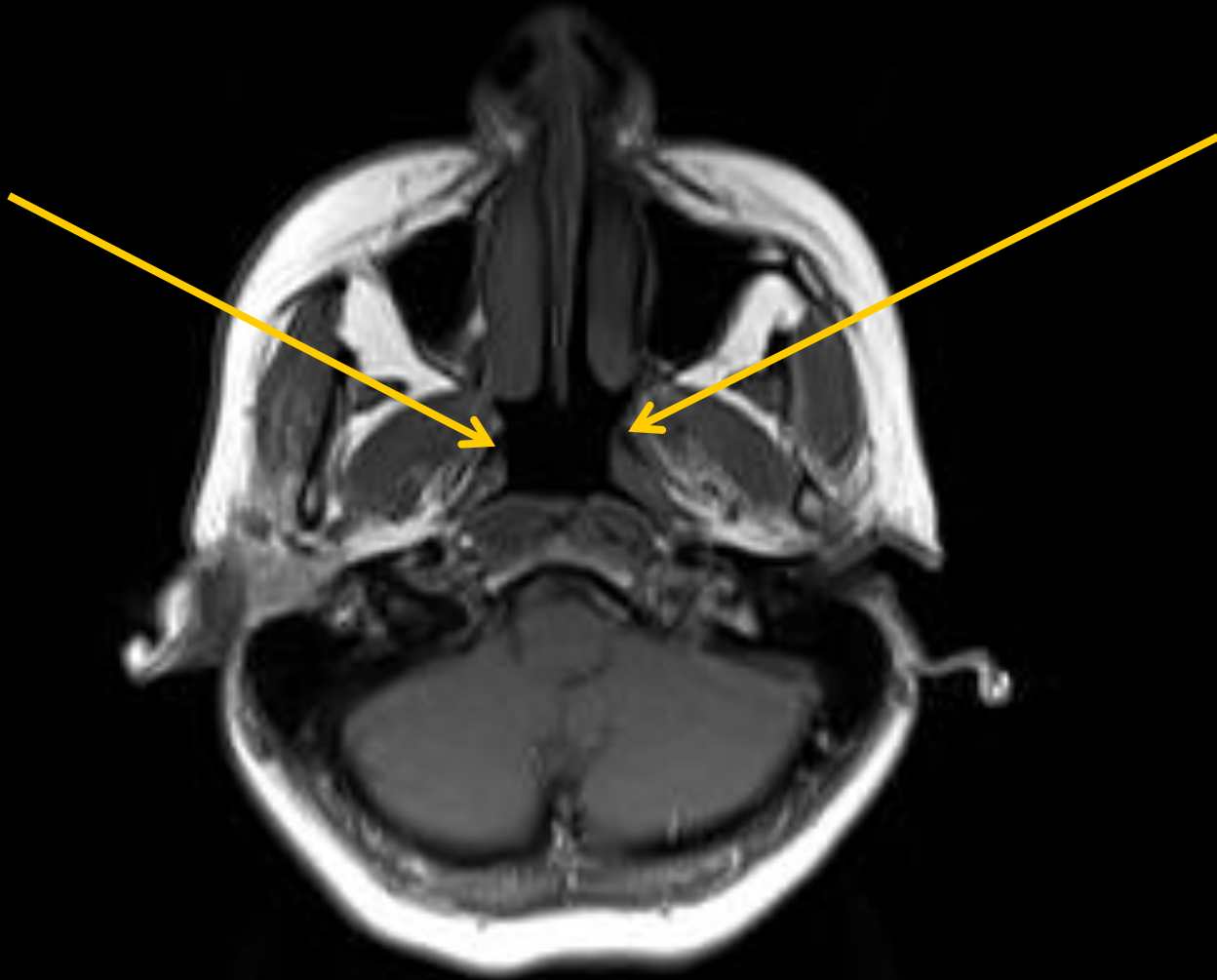




Rosenmüller  
fossa

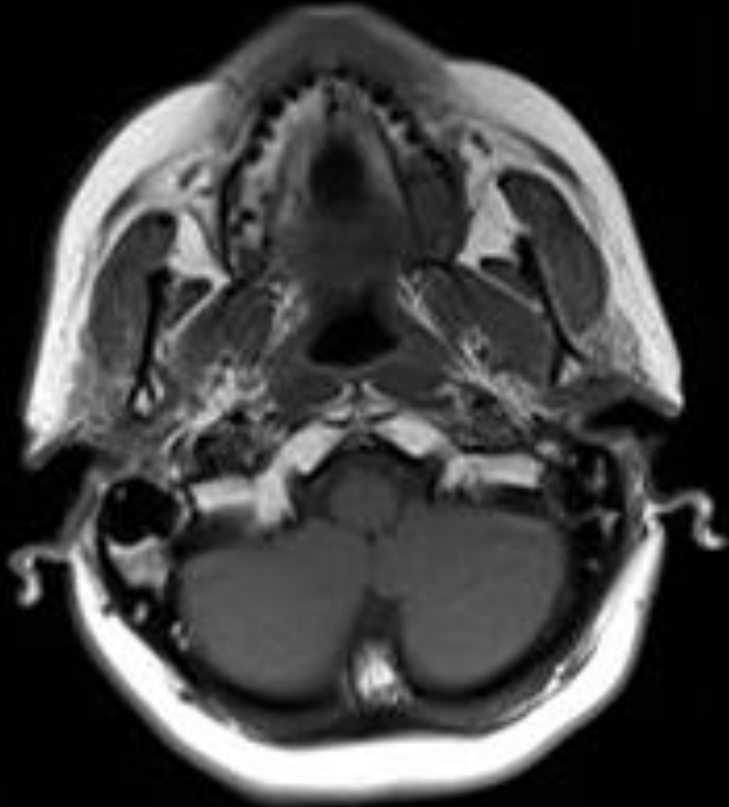

Torus tubarius



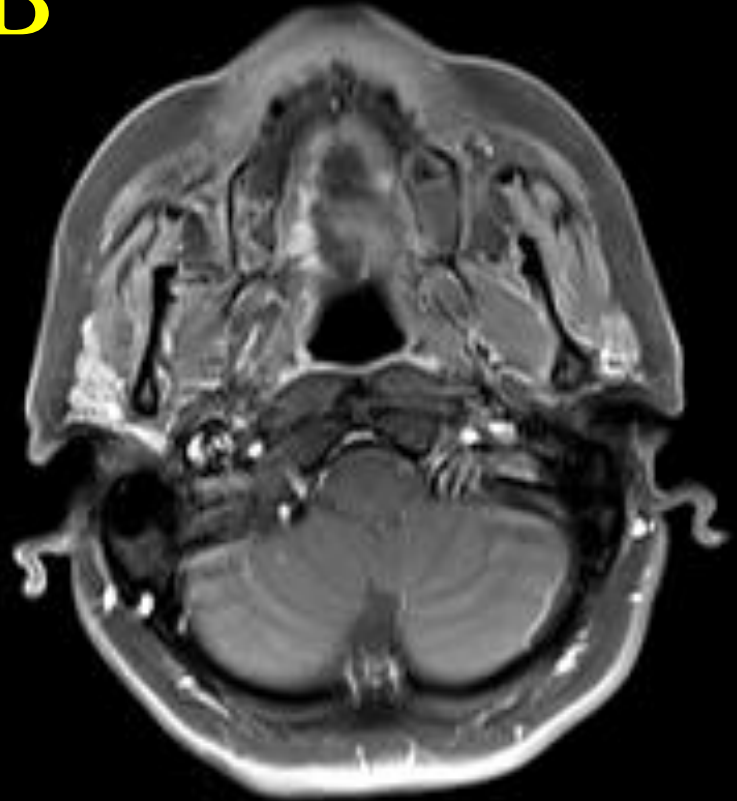Östaki açılışı

T1

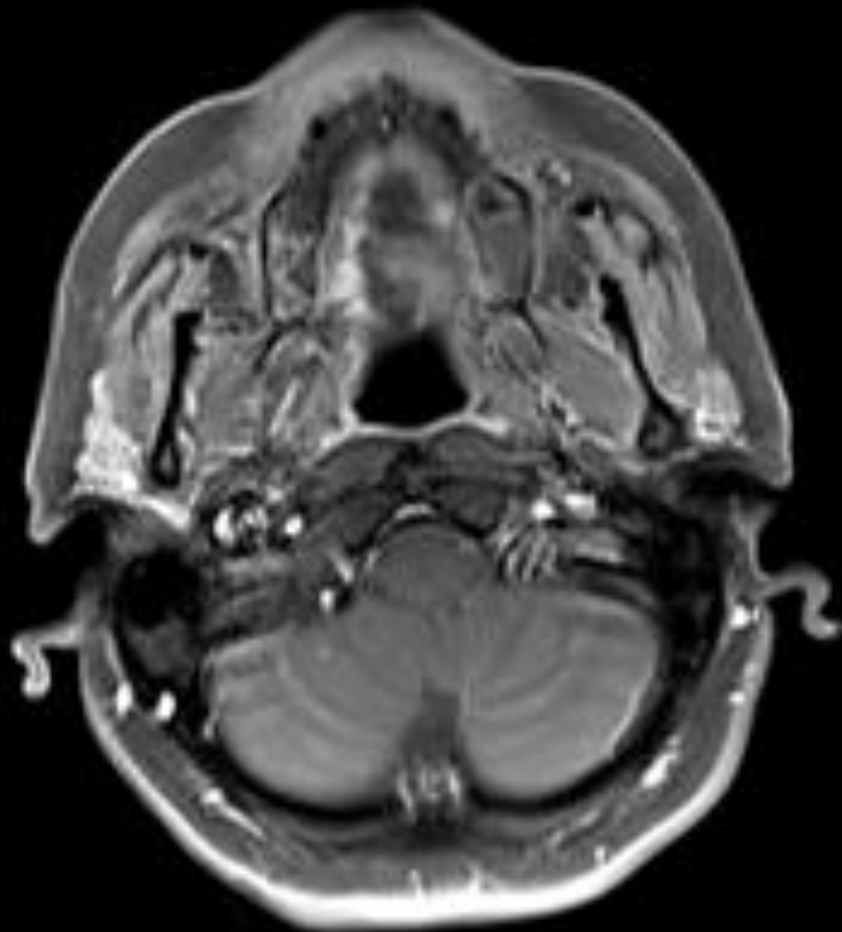

T1 post kontr

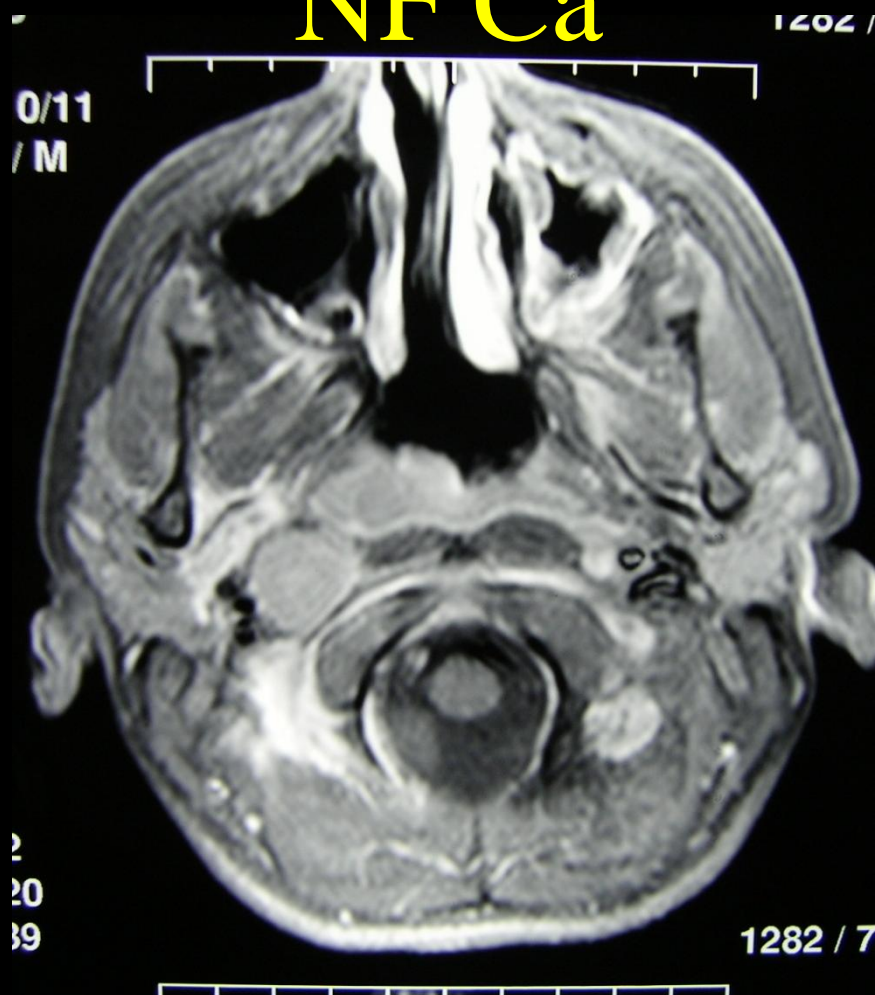
YB



Normal



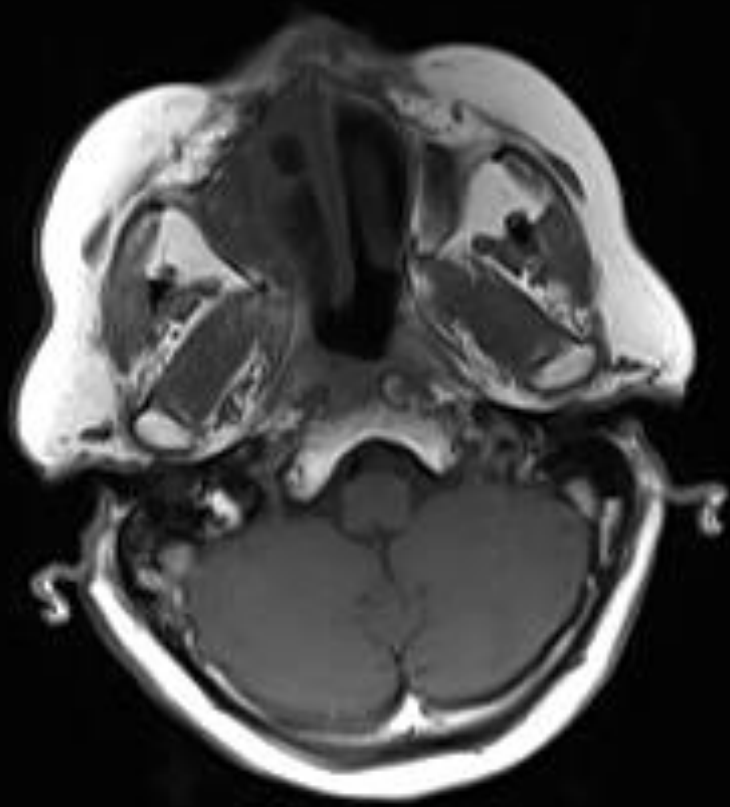
NF Ca



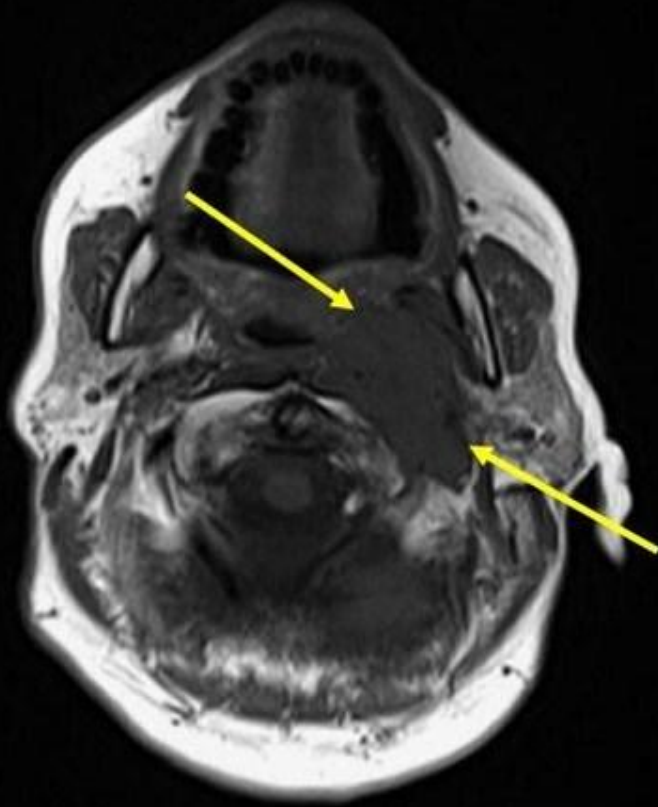
Normal



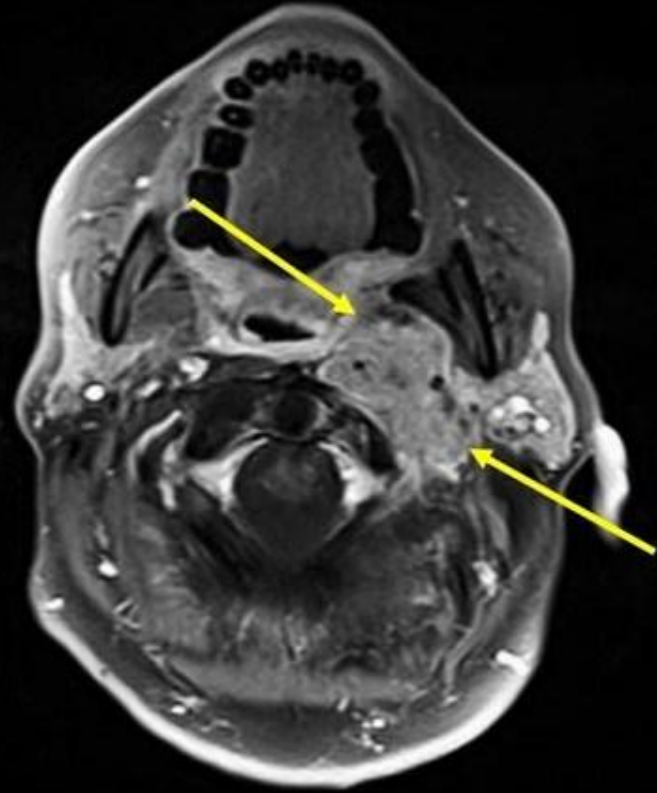
NEO



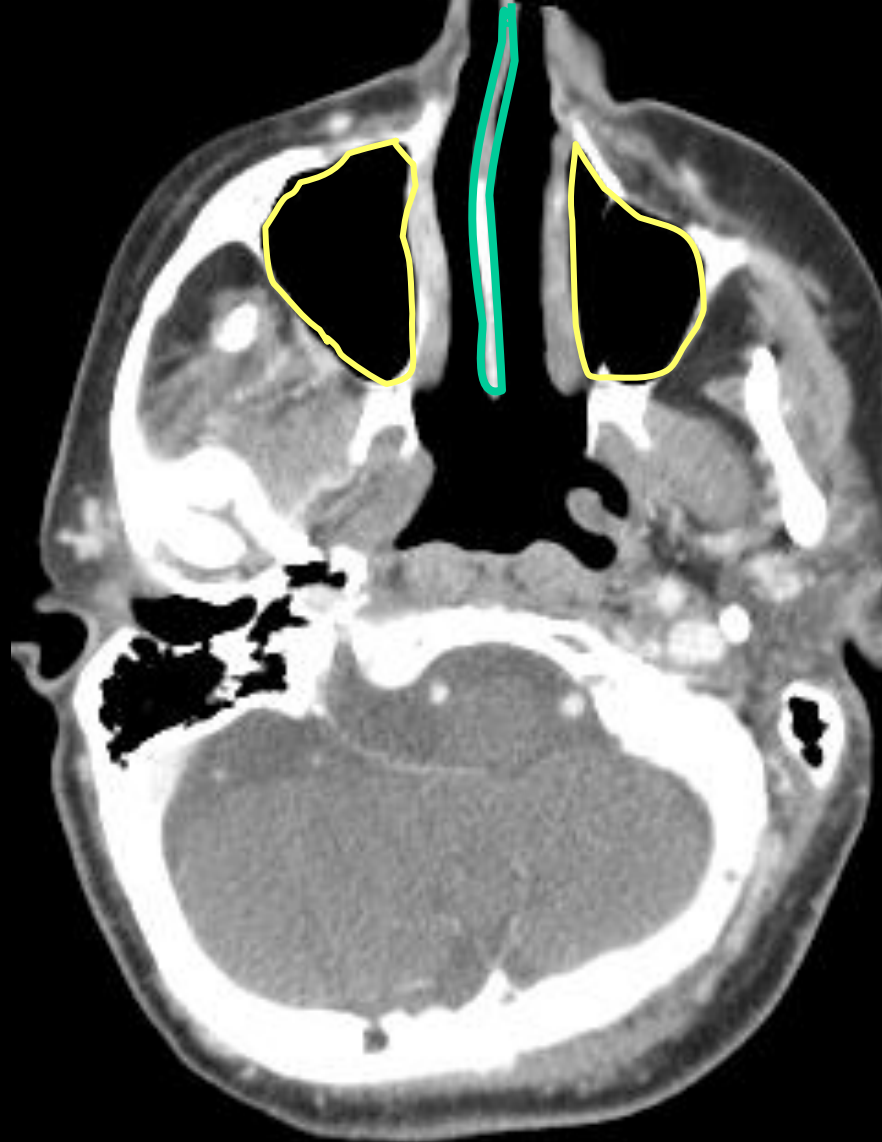
# NF Ca



a



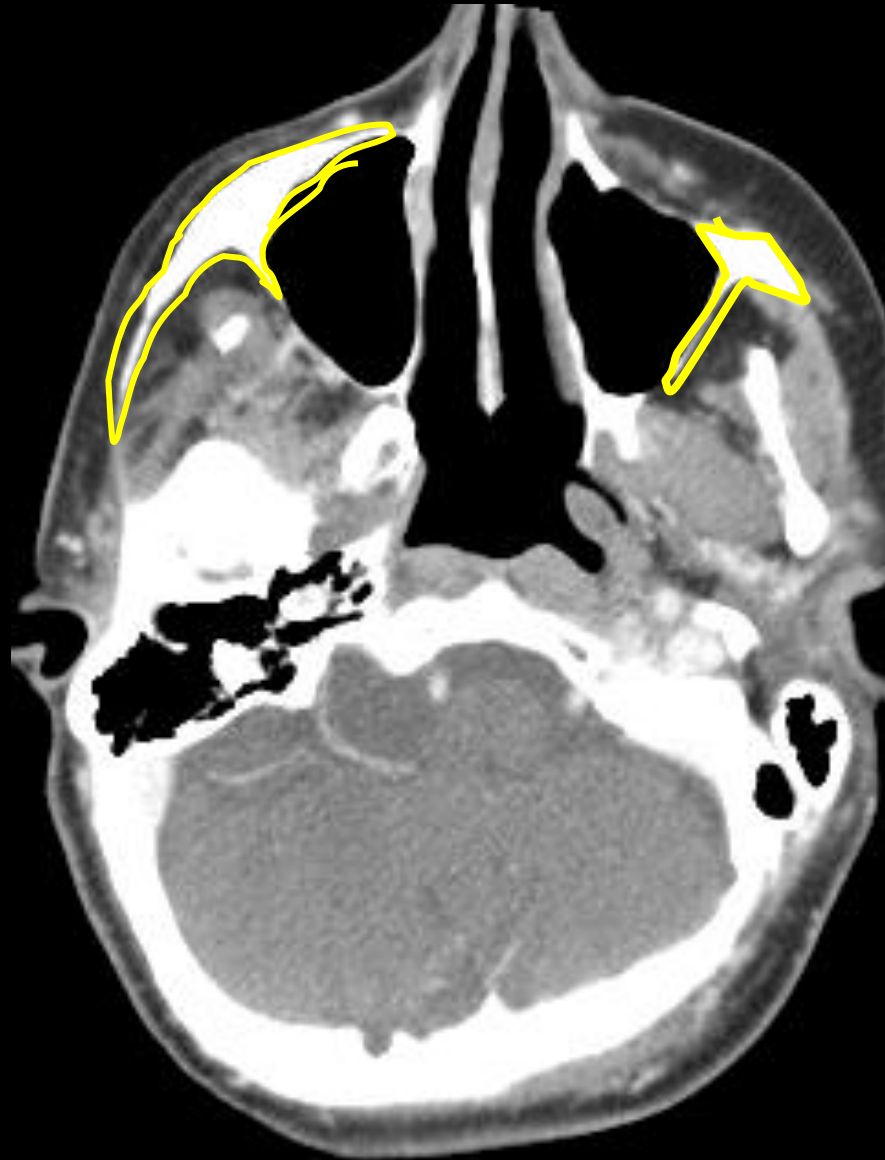b



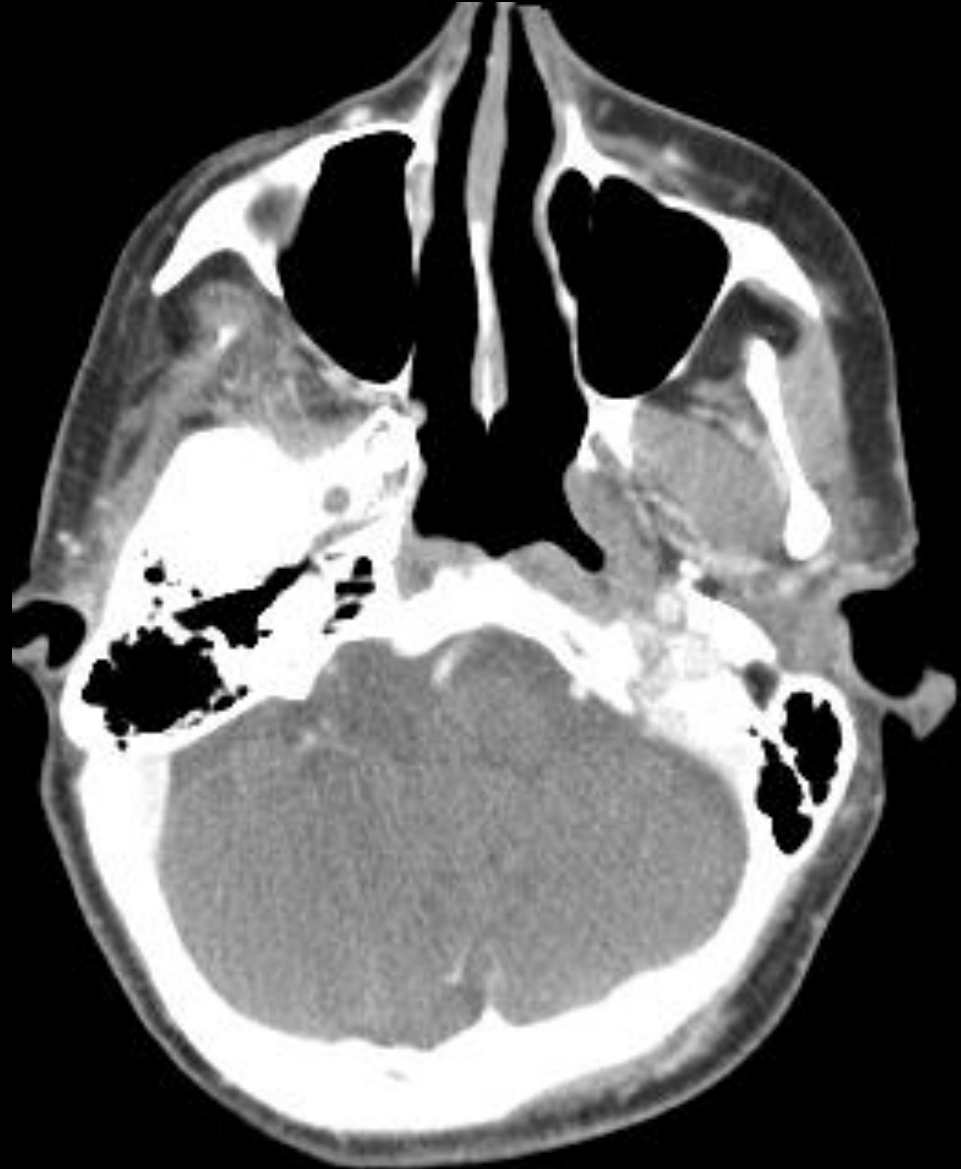Maksiller sinus

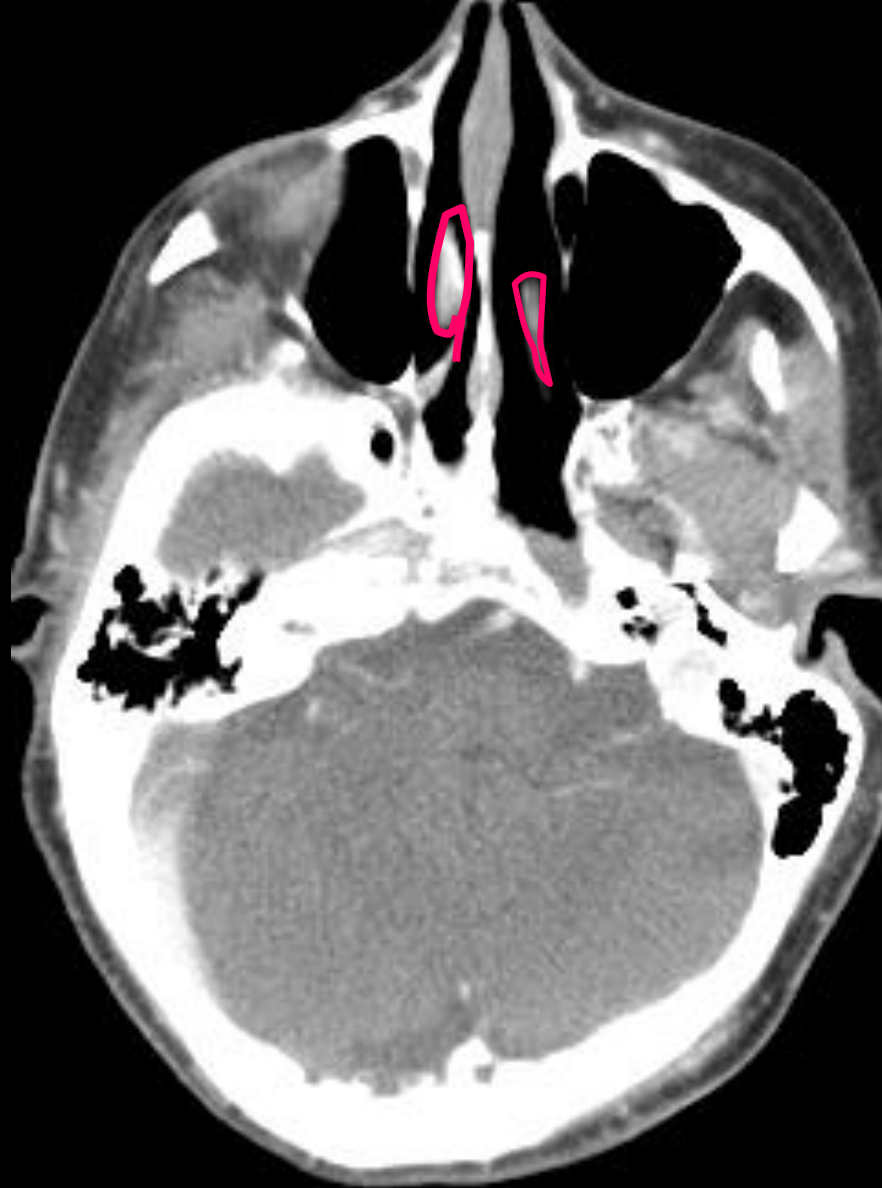
Nazal septum



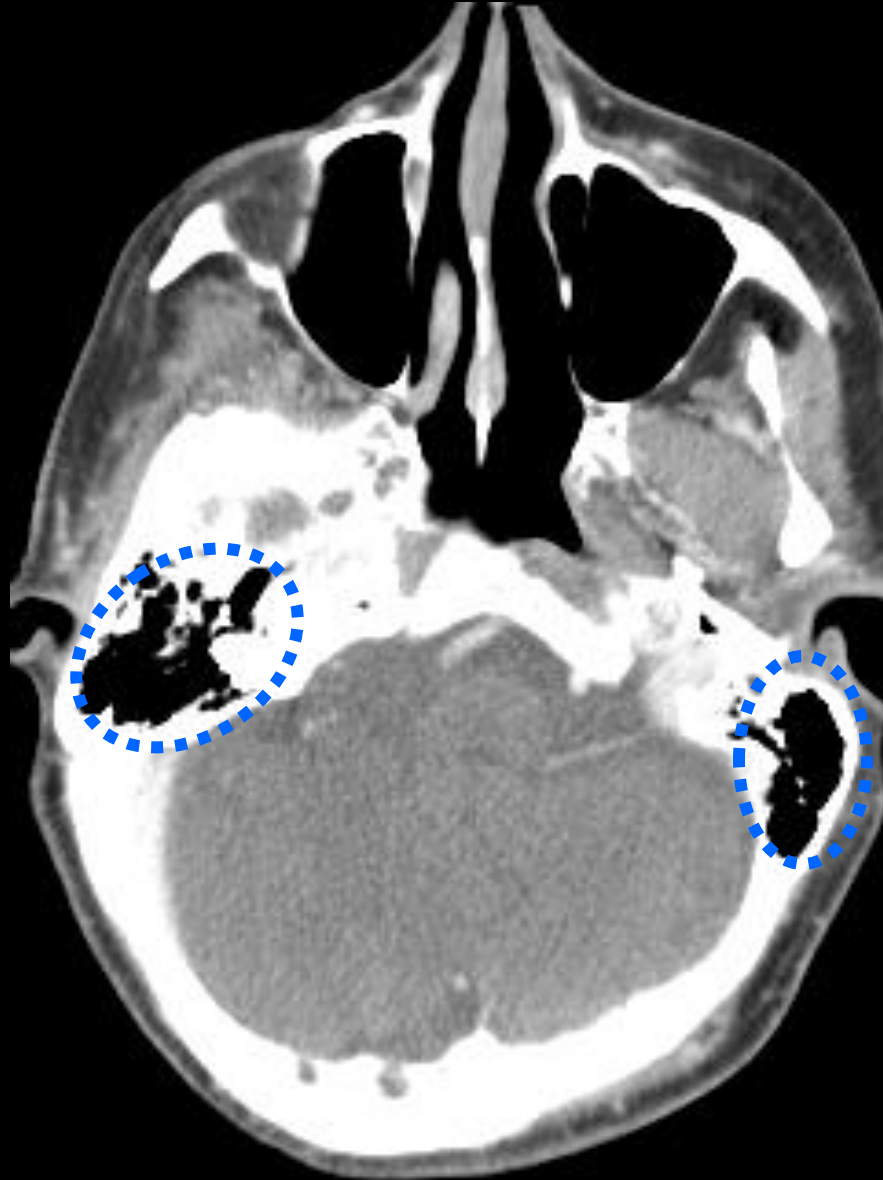

Zygoma

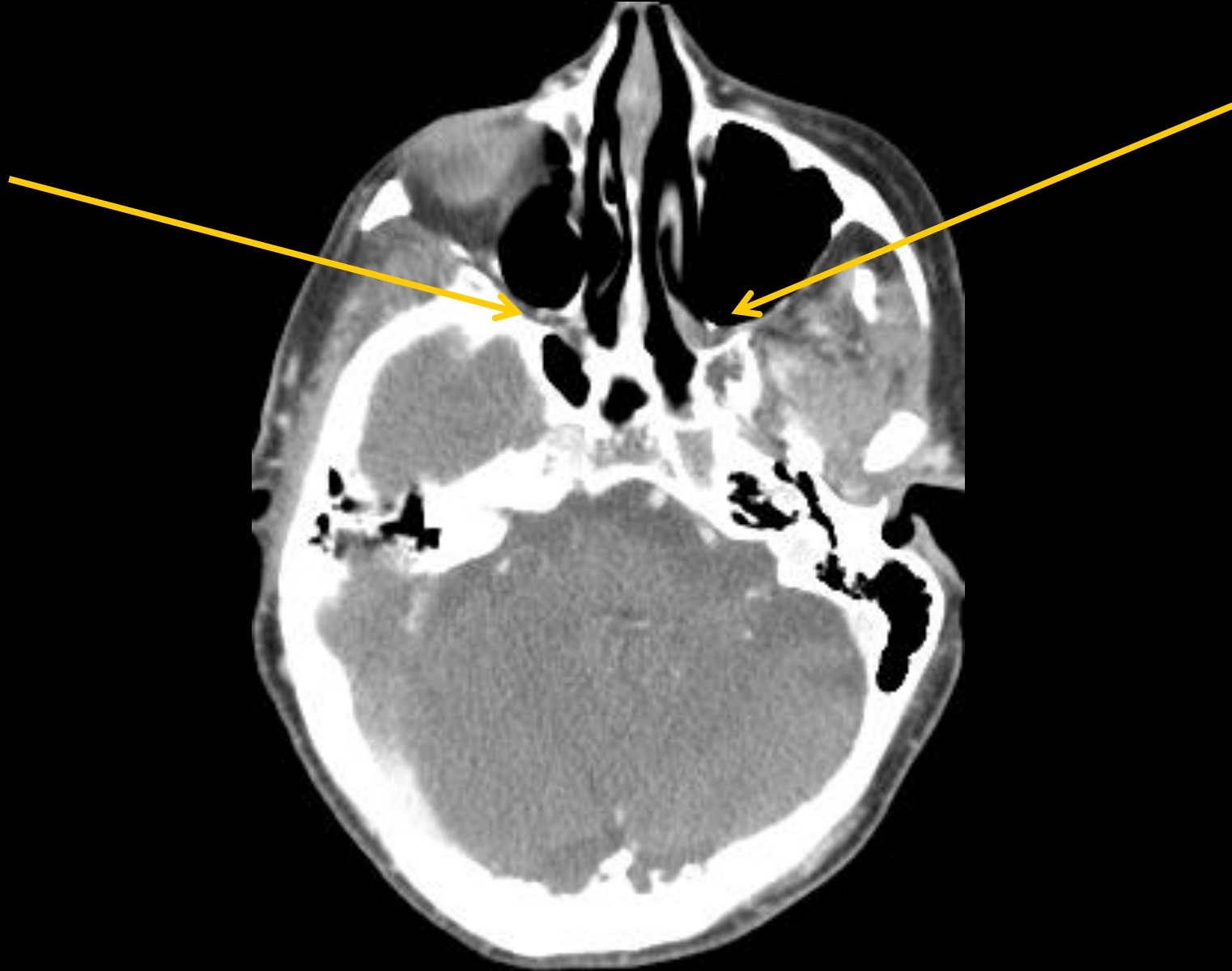




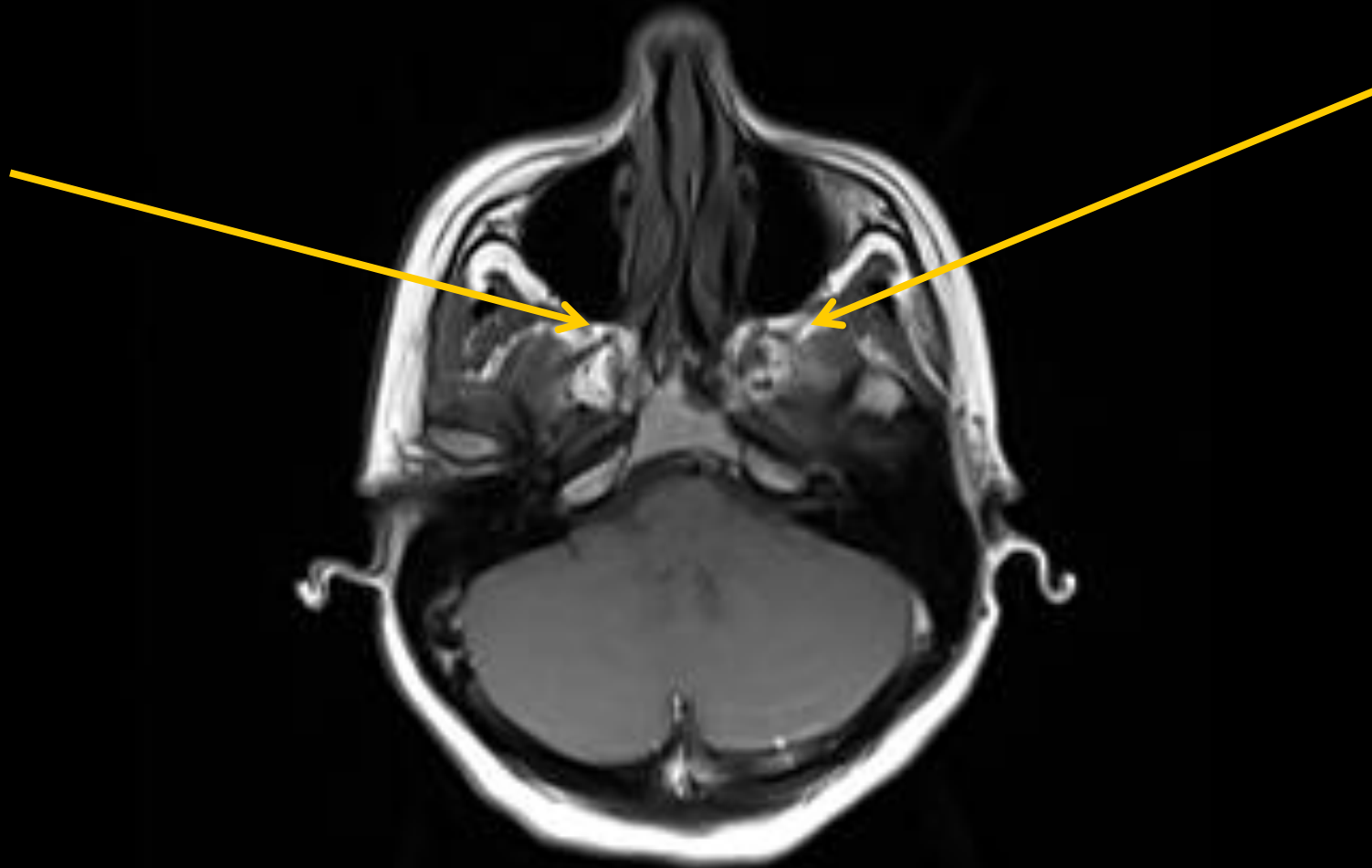
Konkalar



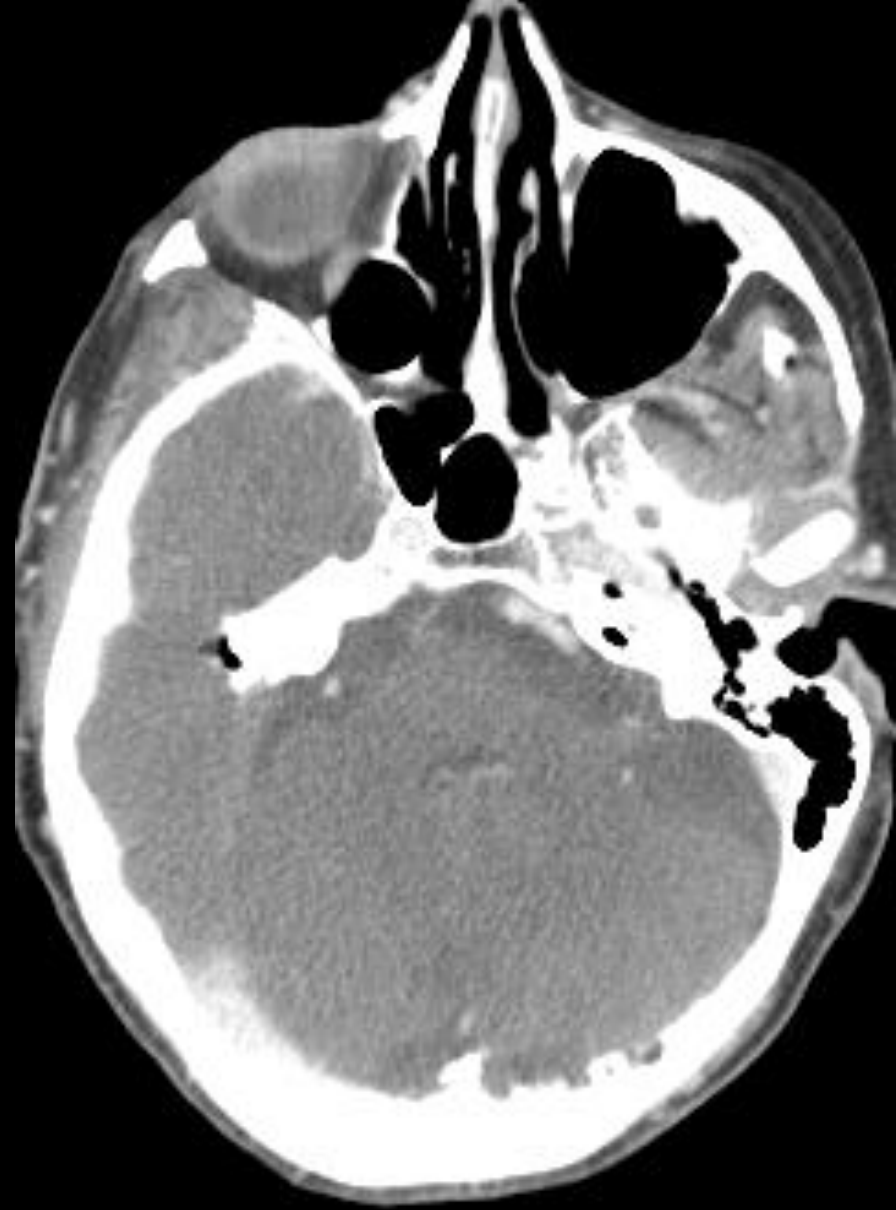Mastoid hücreler

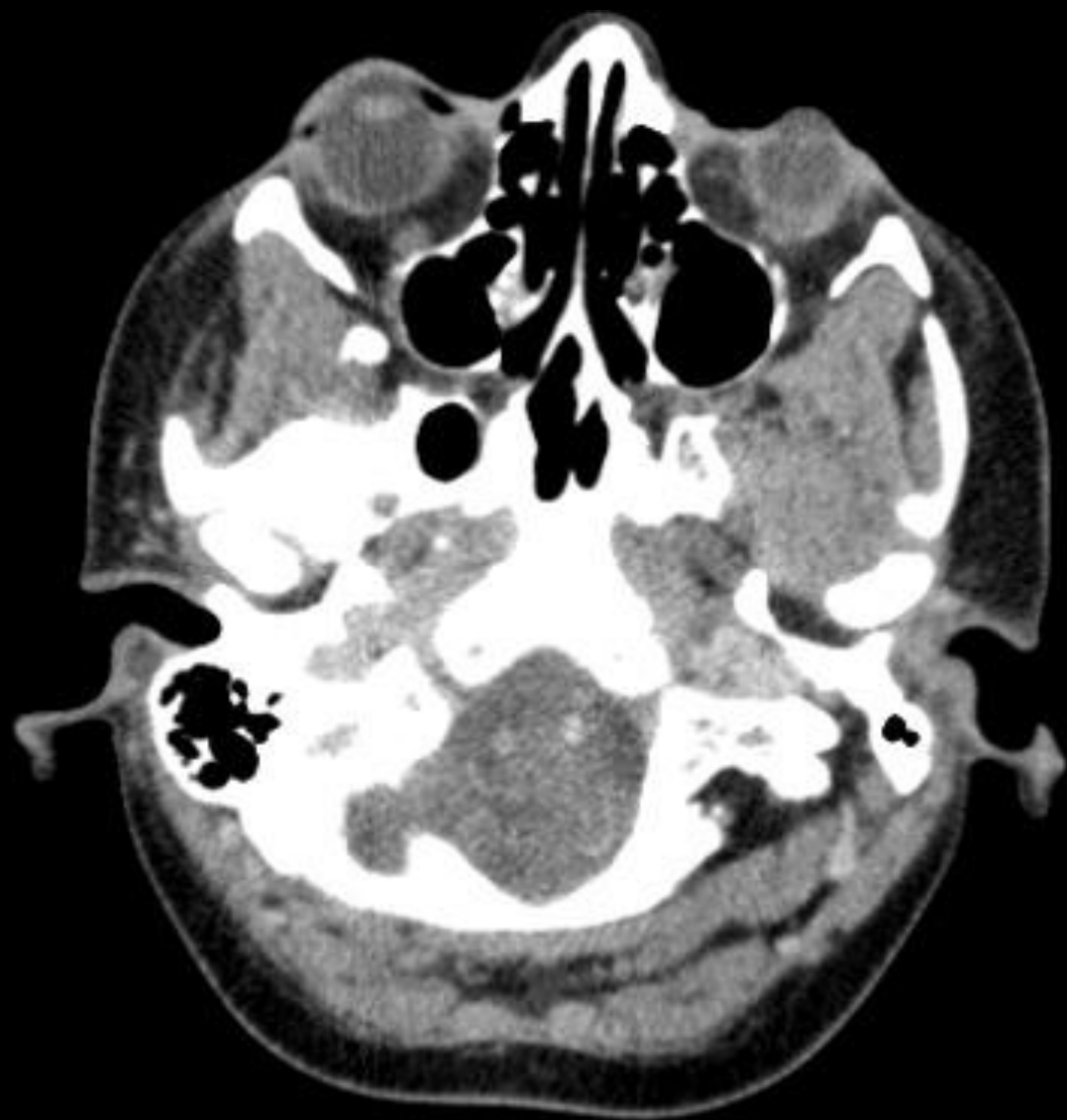

Pterygopalatin fossa

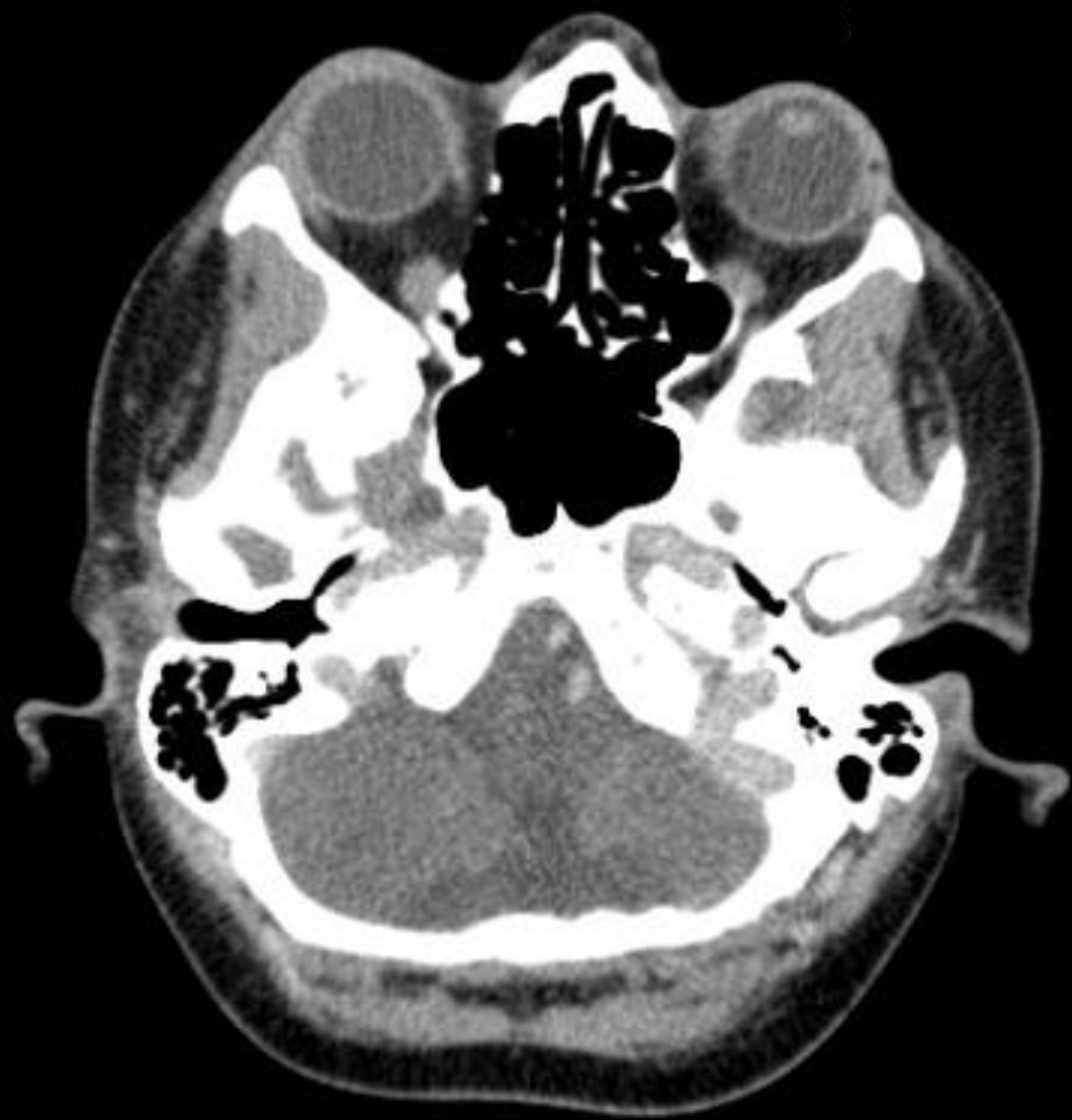


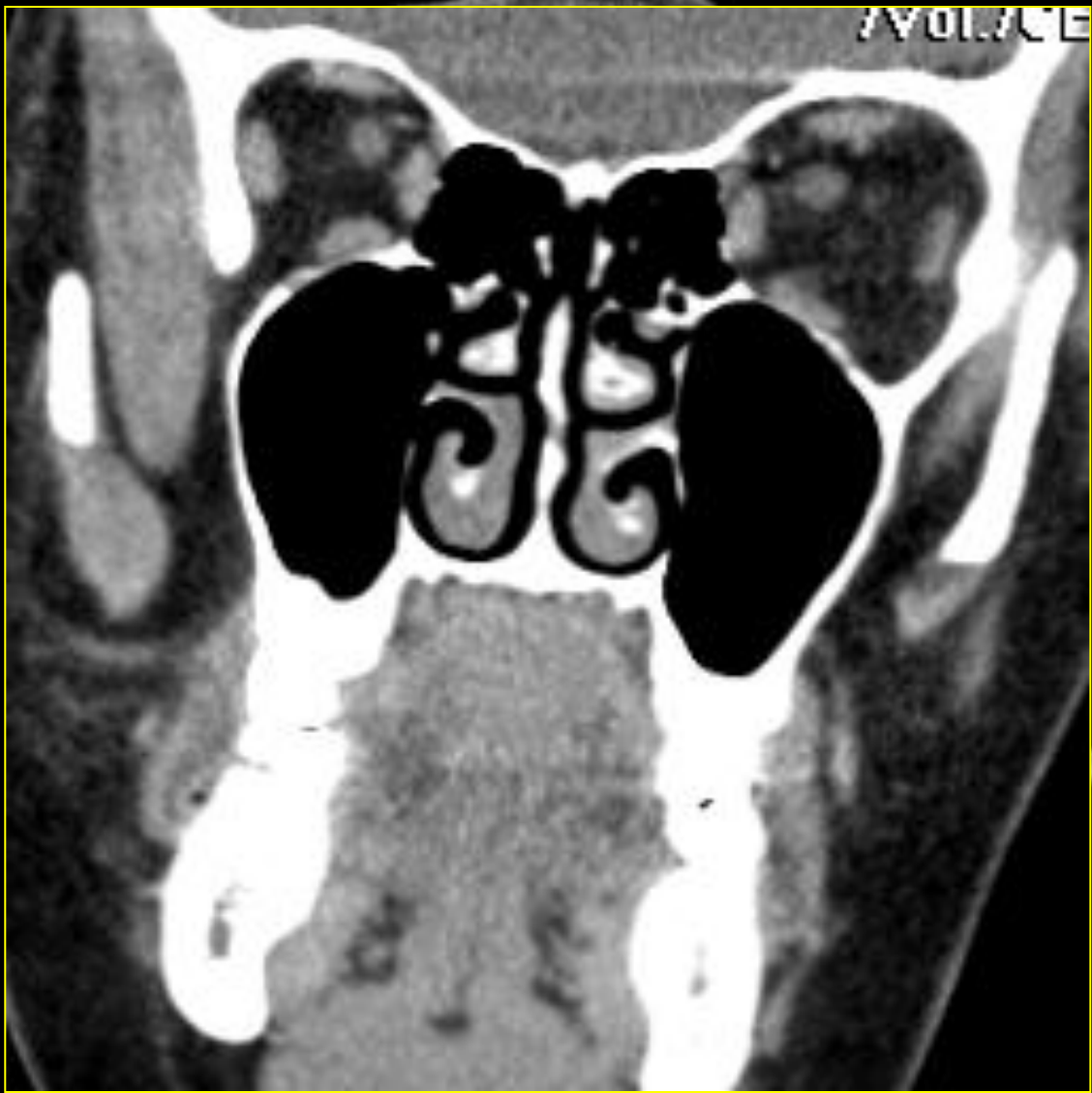Pterygopalatin fossa

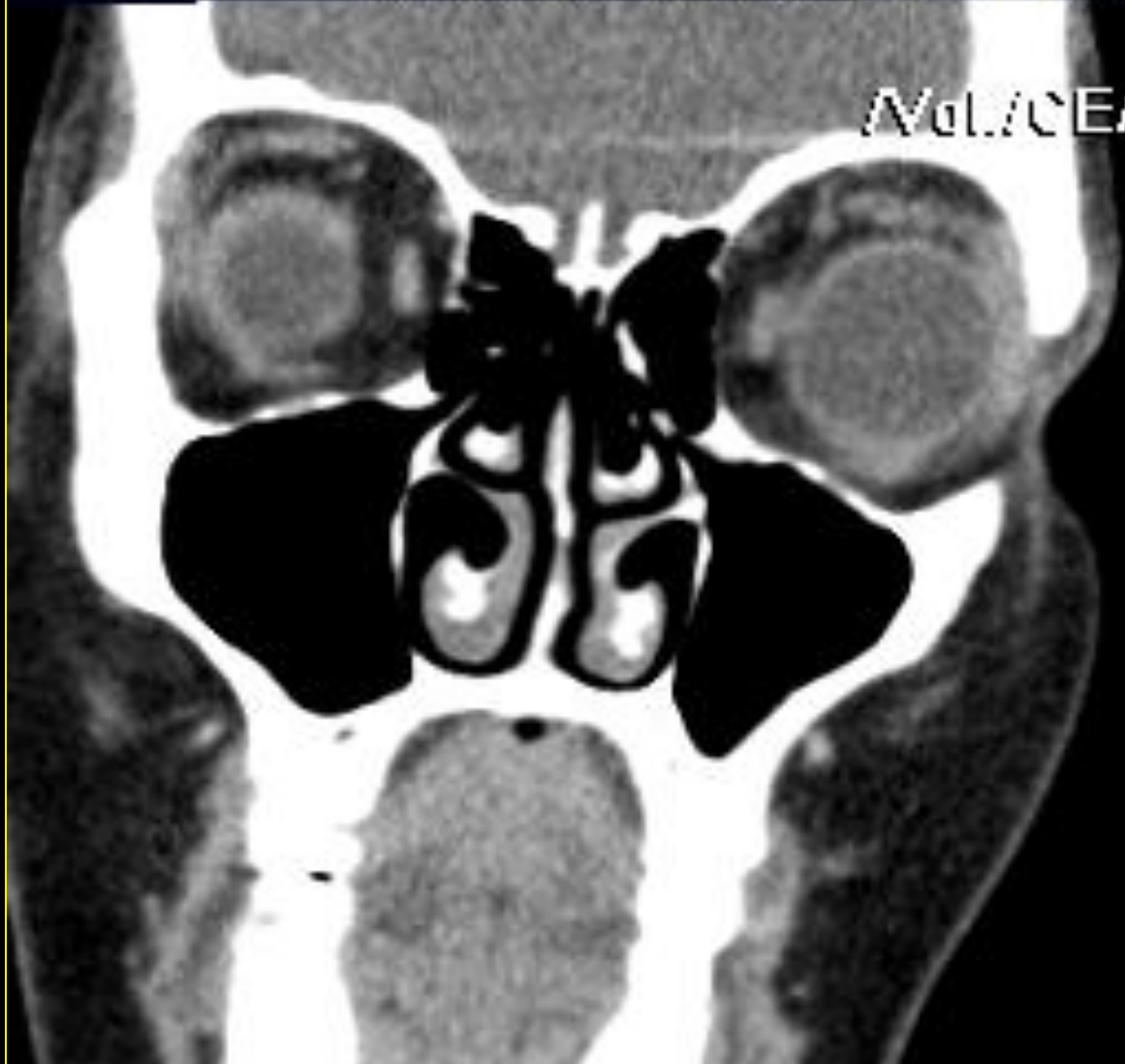












Lakrimal gland

Sc5/5  
SE / M

S  
S

L

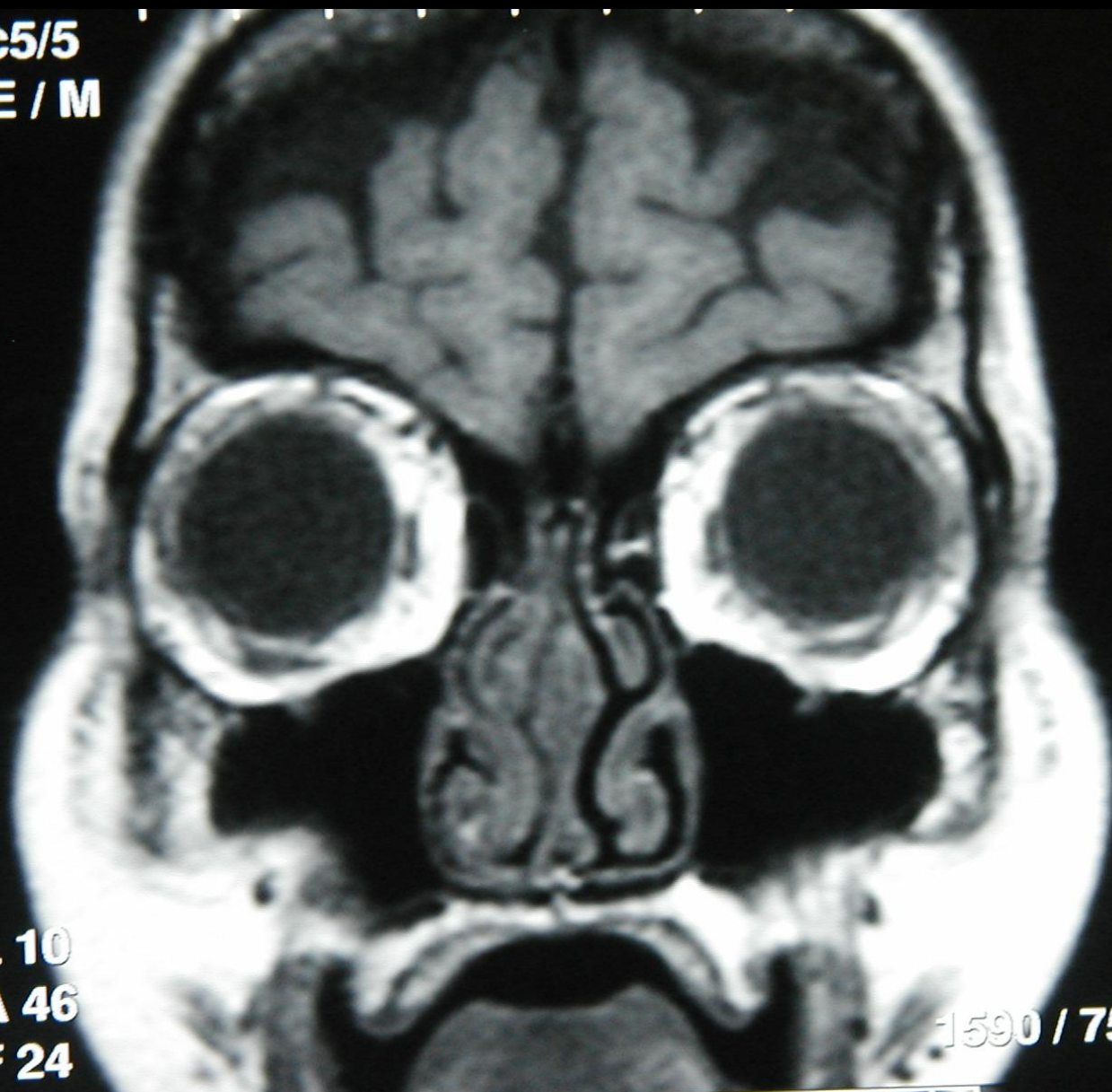
L

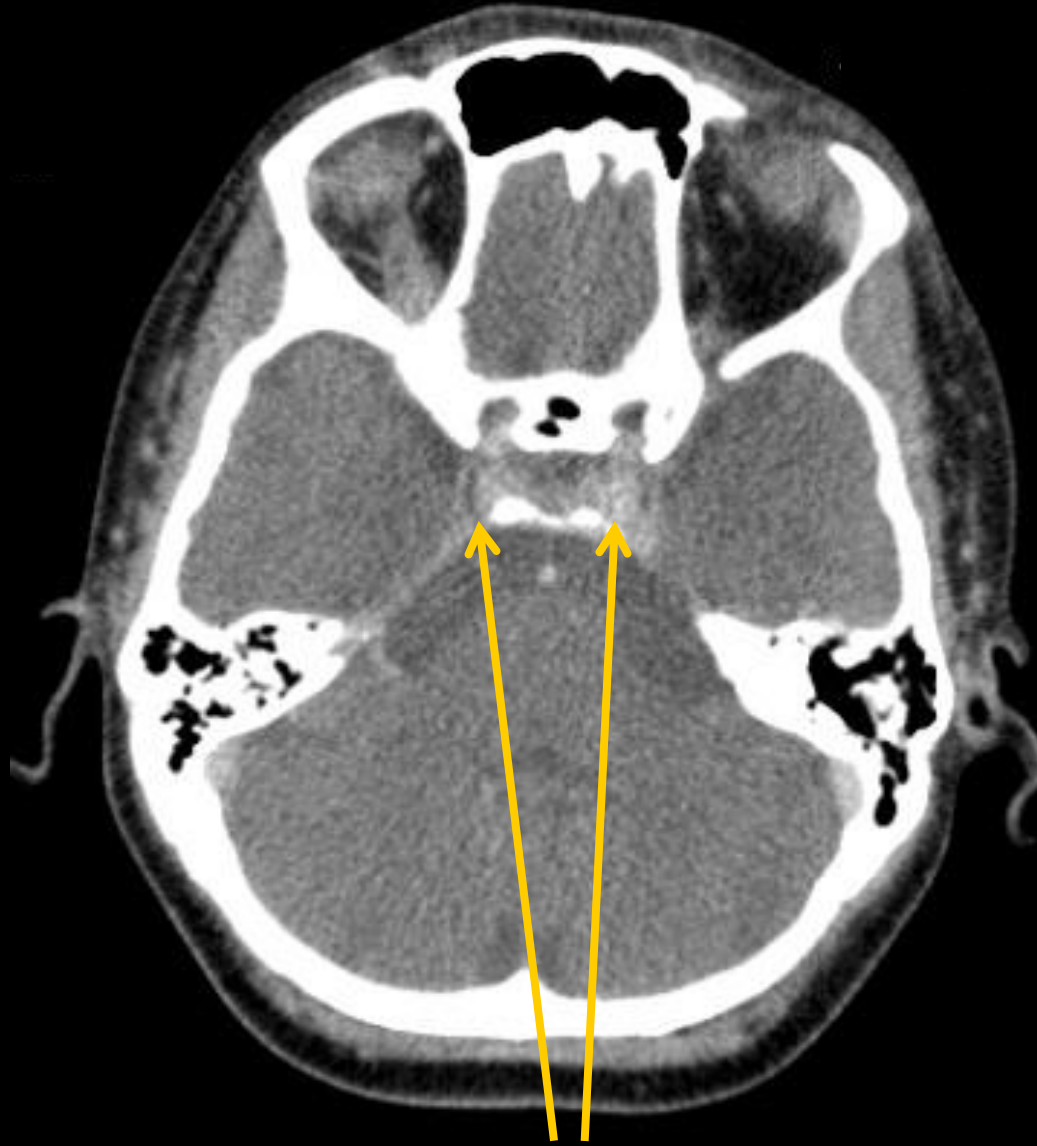
L 10  
A 46  
F 24

L  
A  
F

759

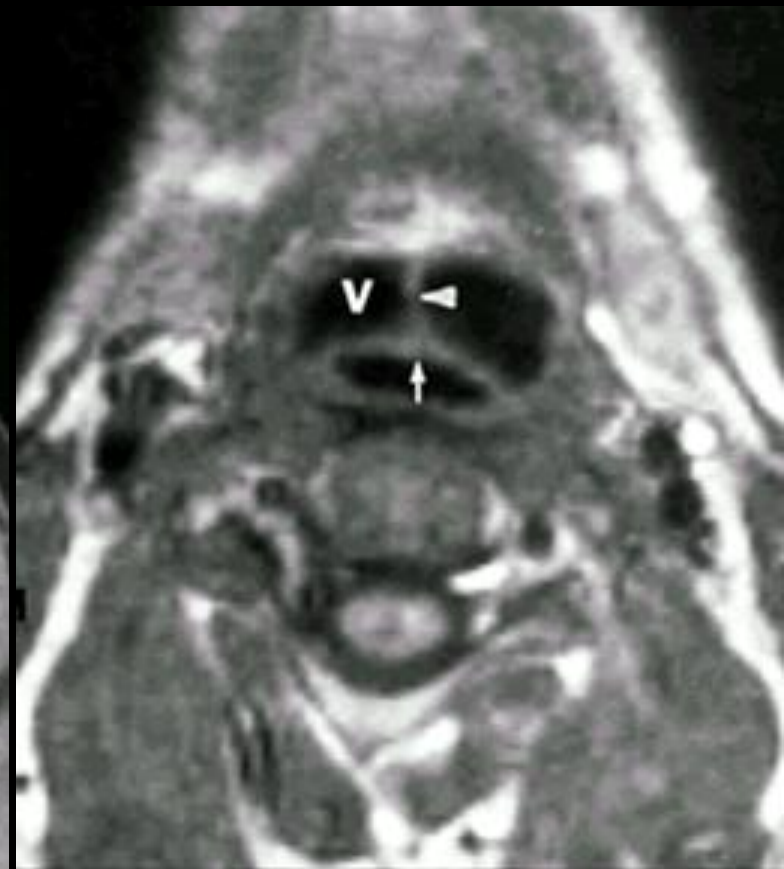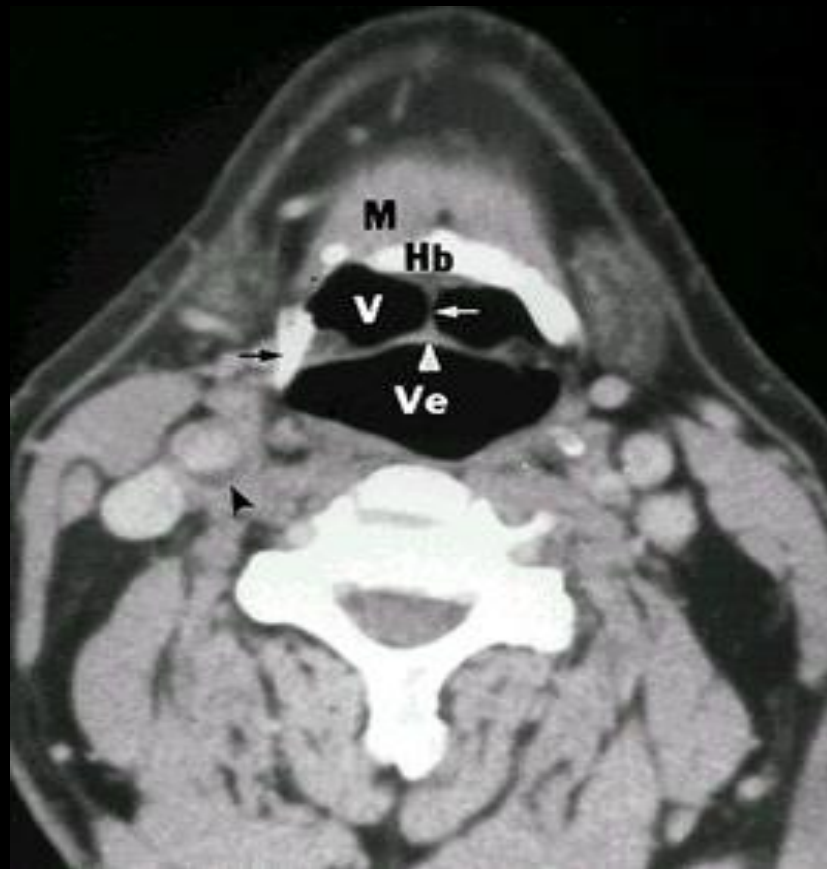
1590 / 759



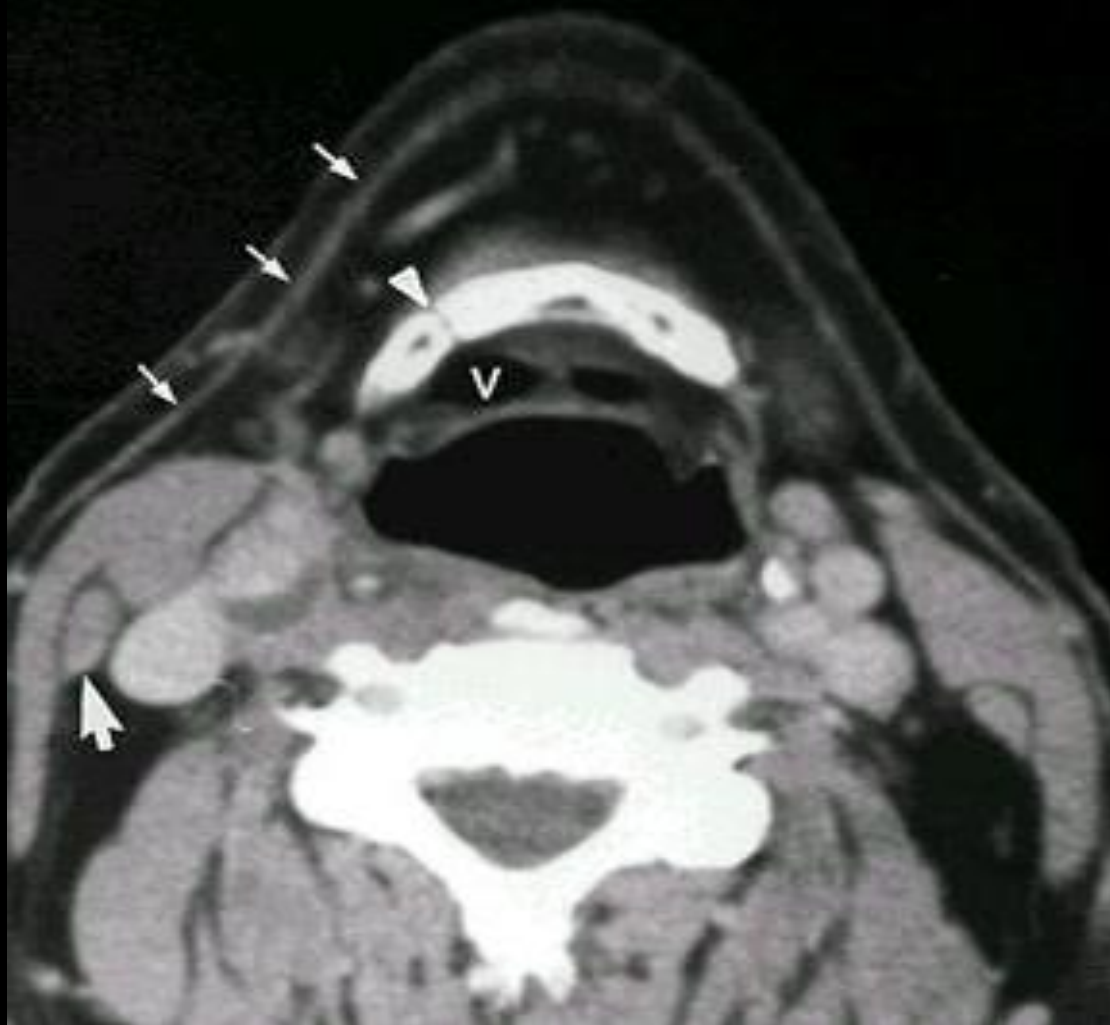

Kavernöz  
sinüsler

- Larinks (BT / MRG)

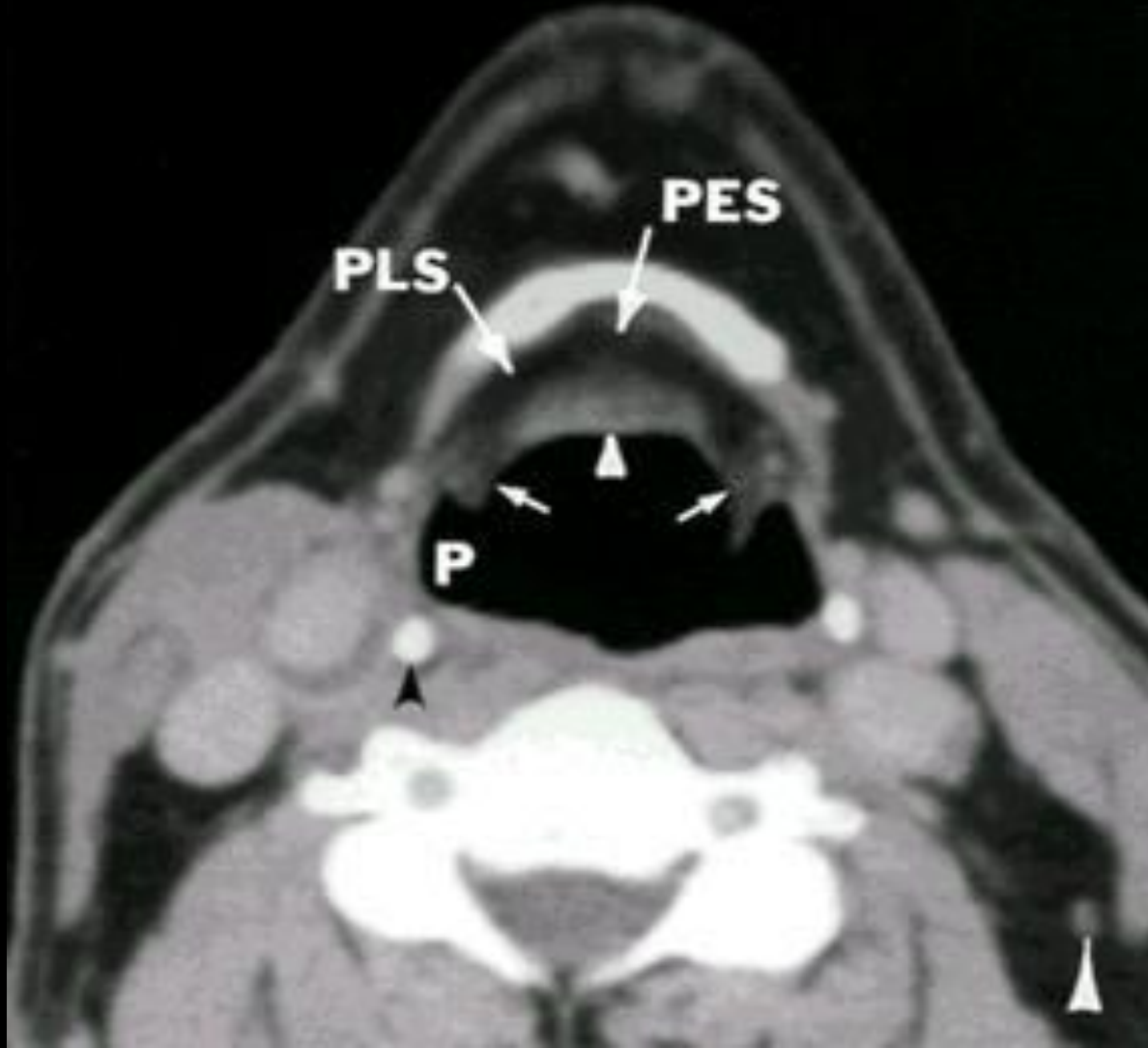


Glossoepiglottik kıvrım, vallekula

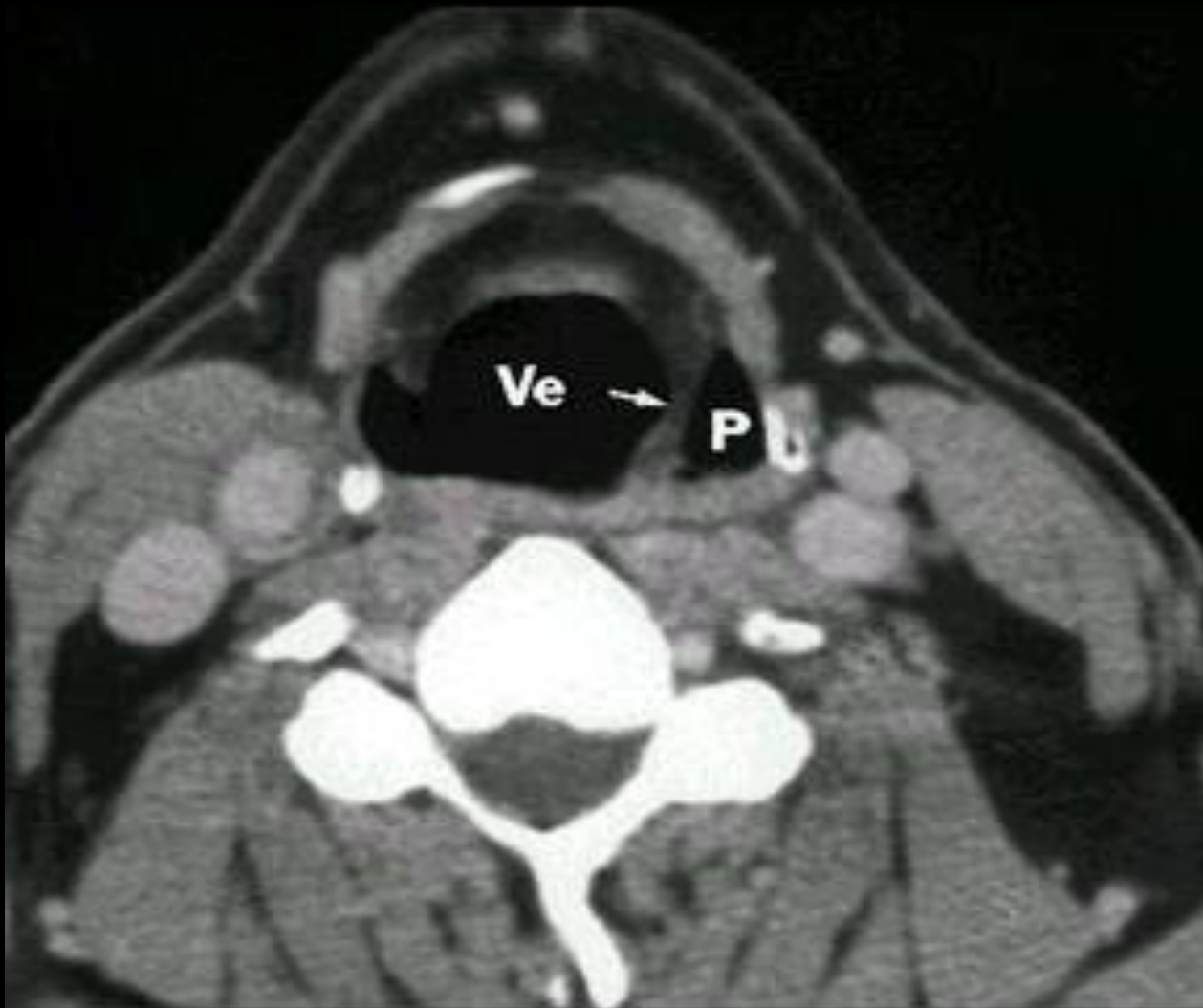


Platysma, omohyoid

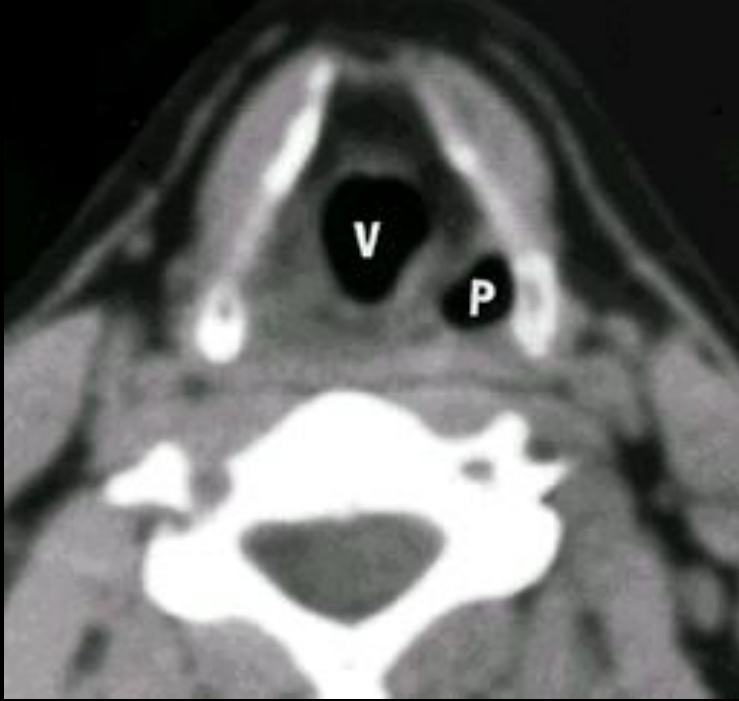



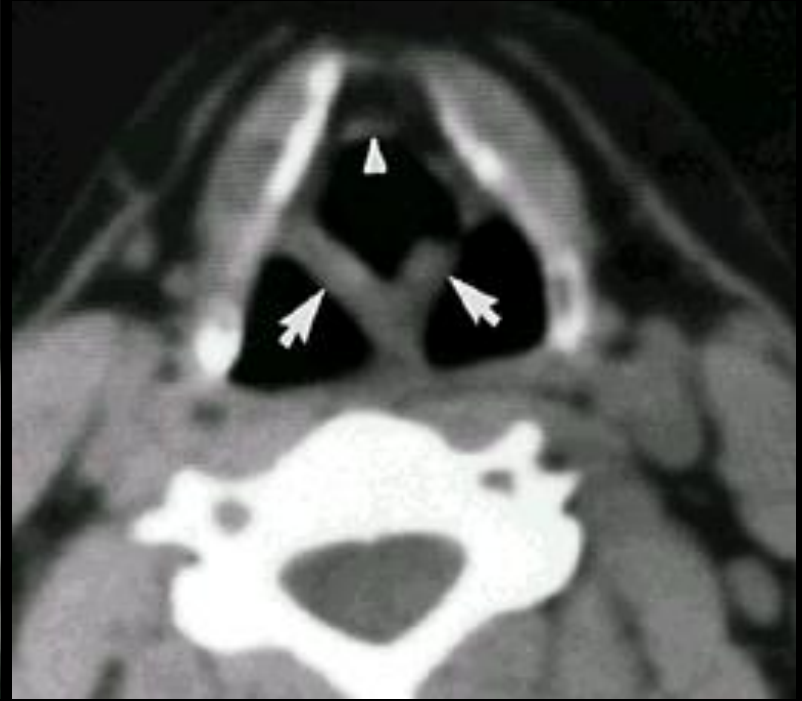
Aryepigottik kıvrım, tiroid kıkırdak üst kornu



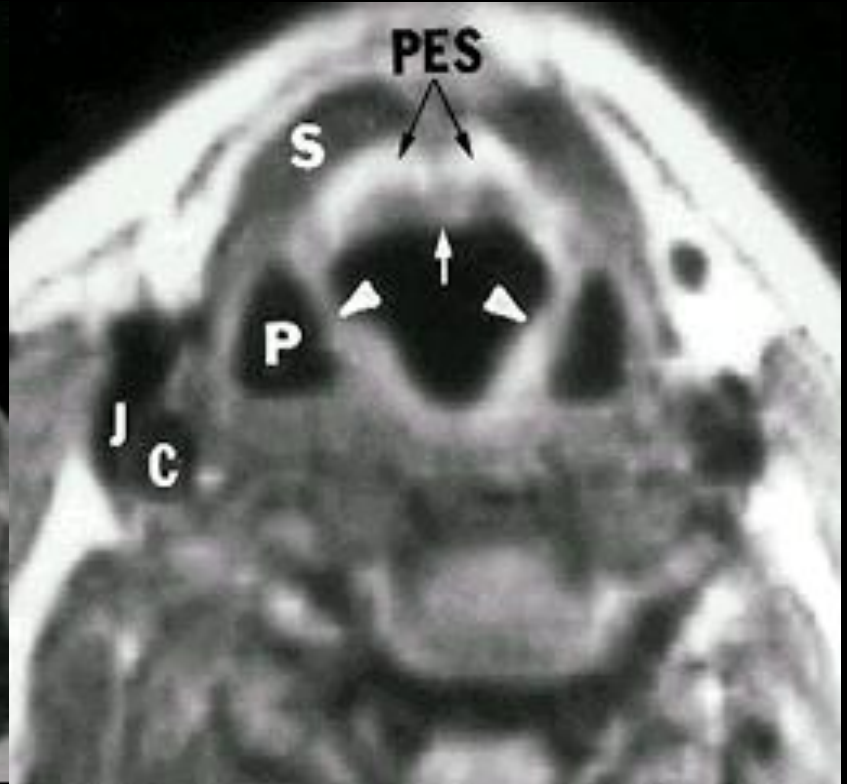
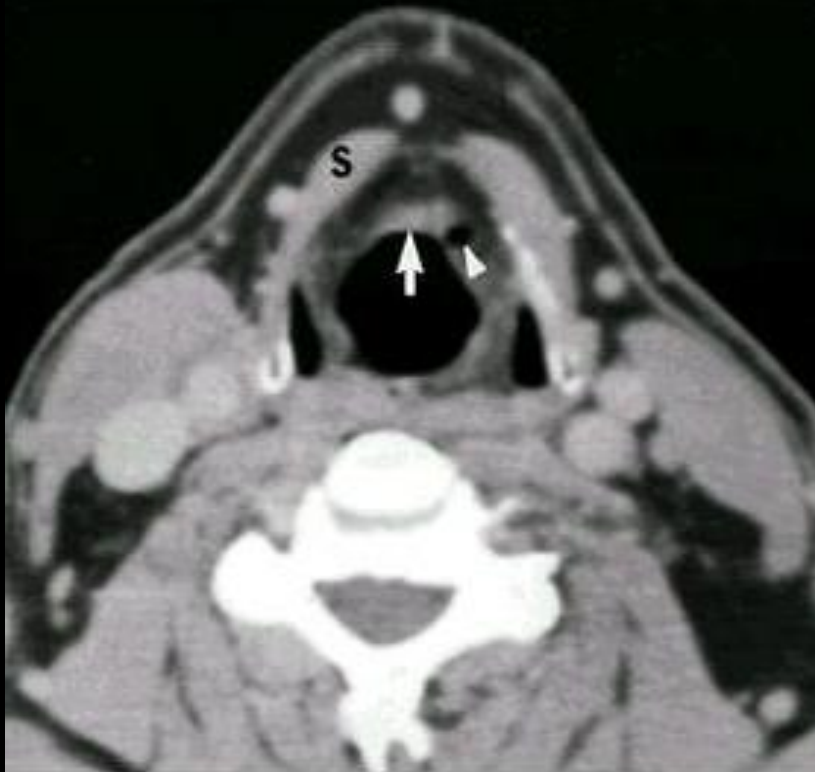Piriform sinüs



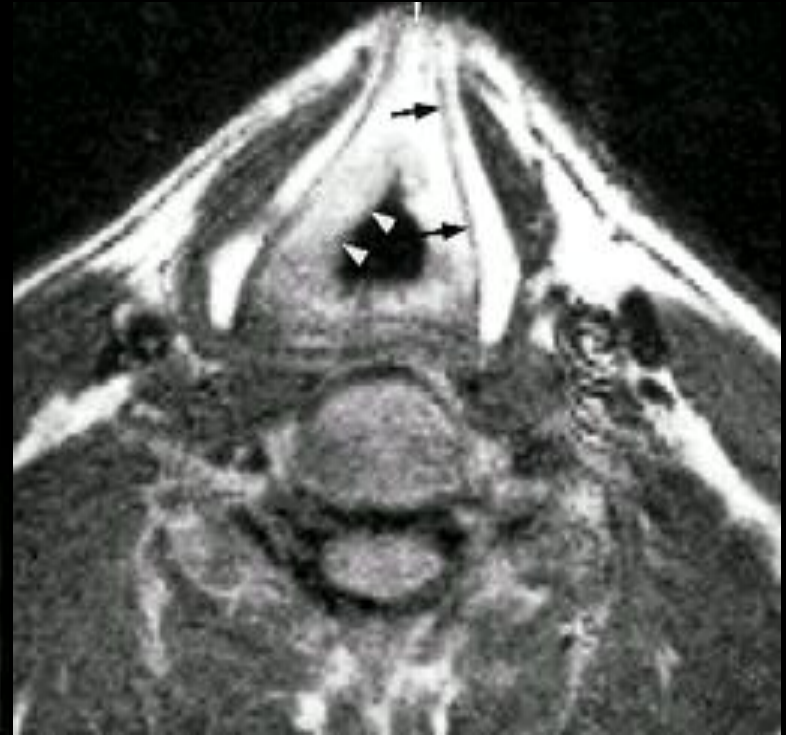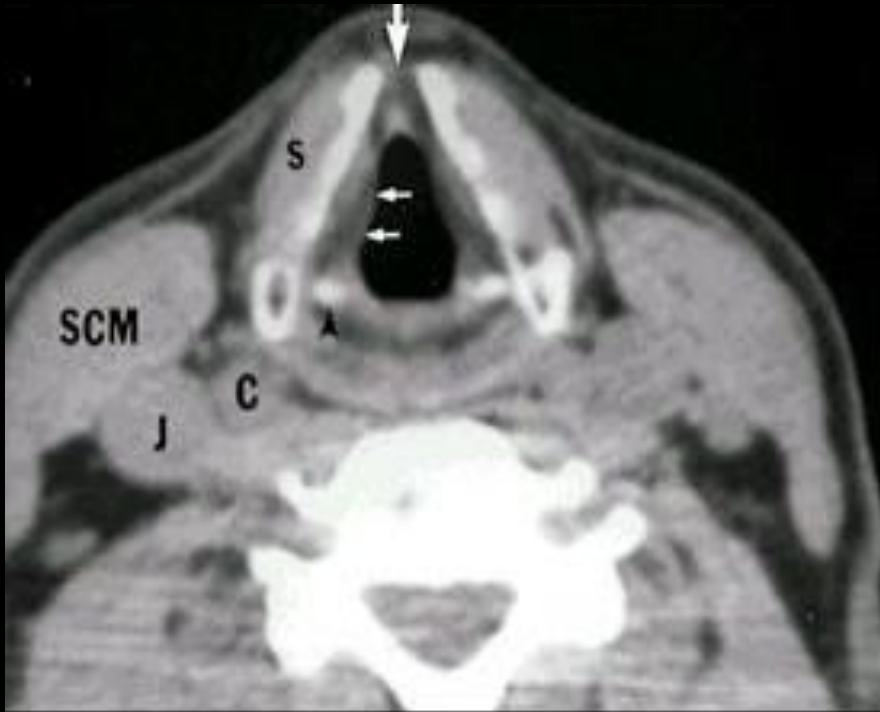
İnspirasyon



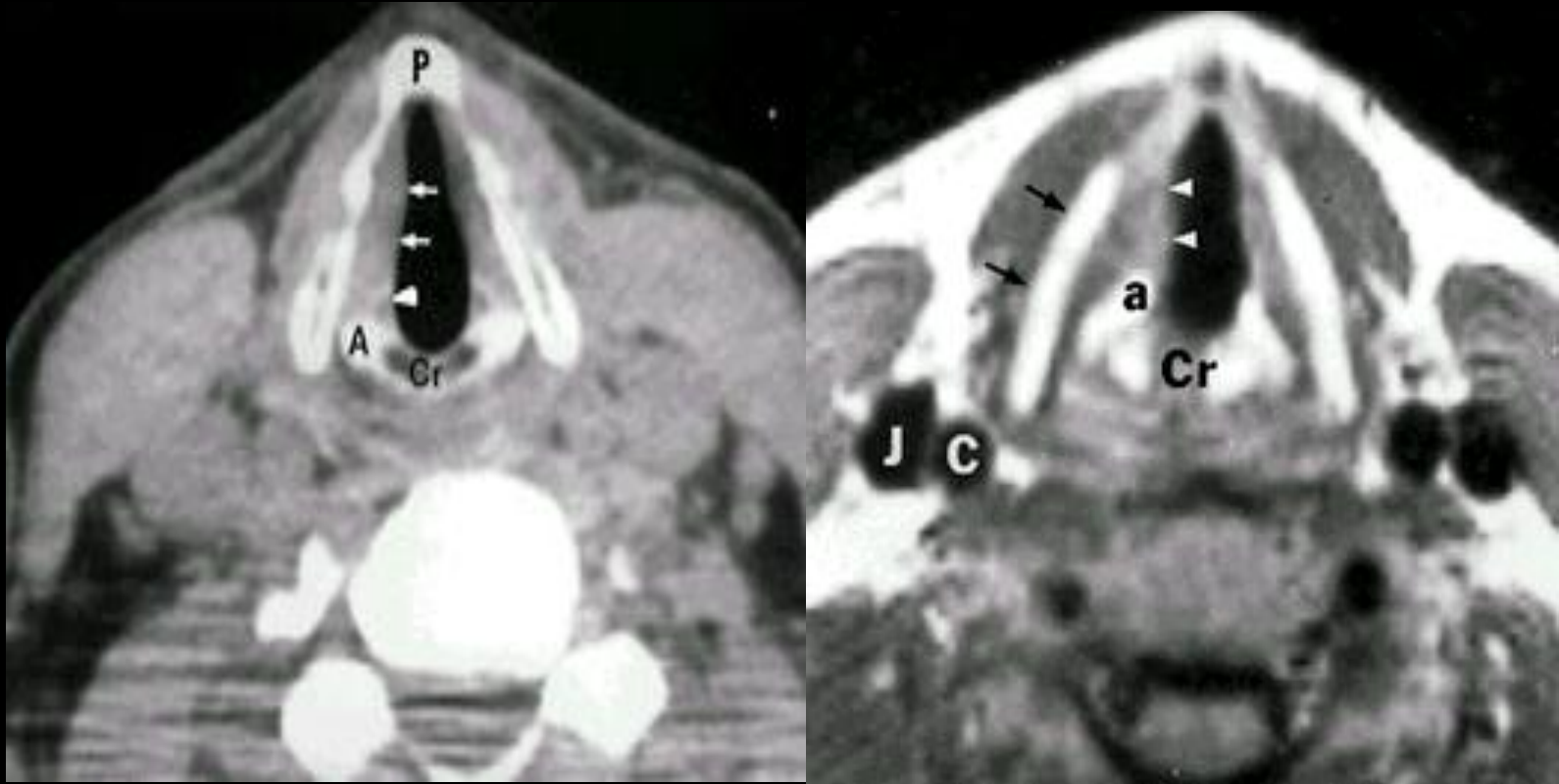
Modifiye Valsalva



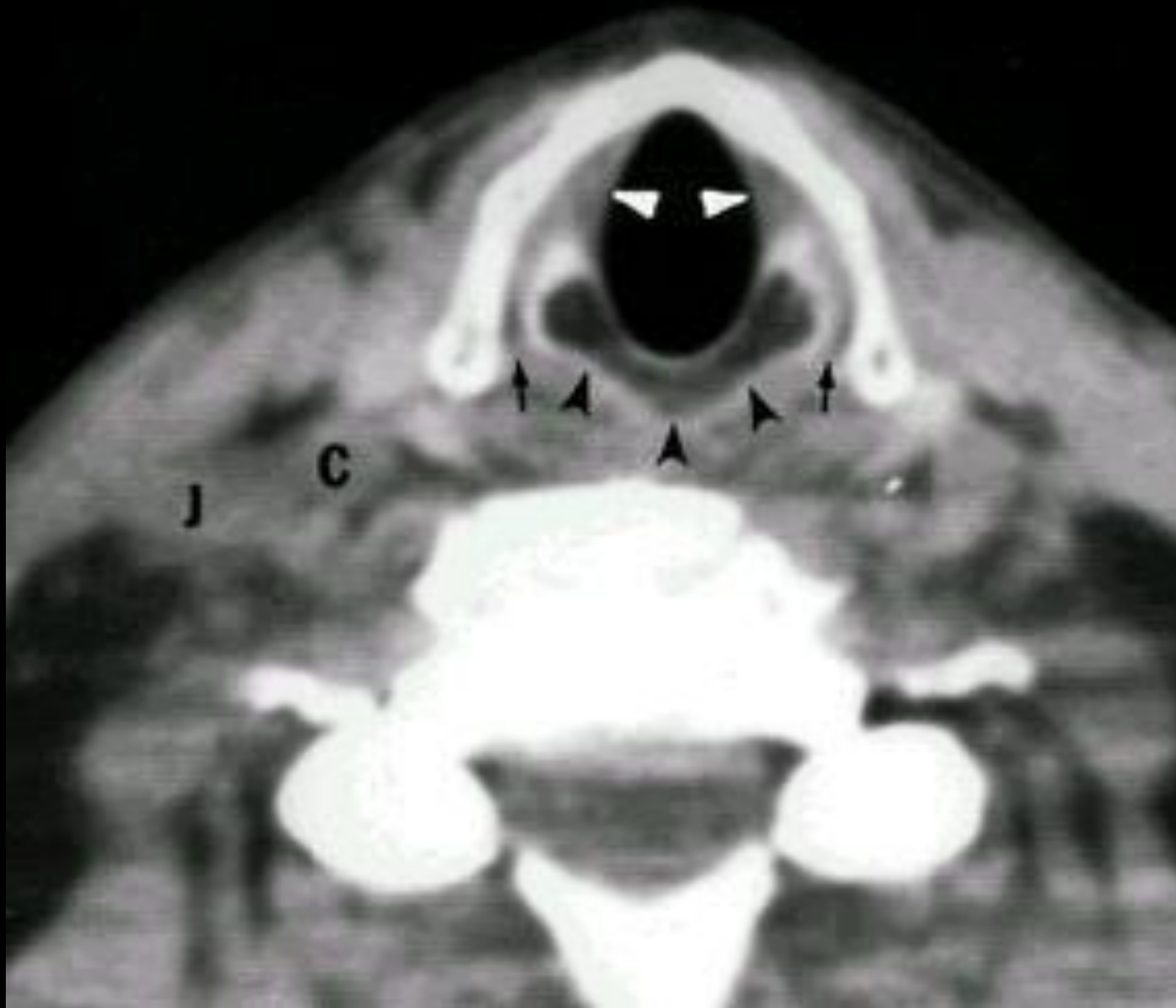
Petiole, Strap kasları, ventrikül



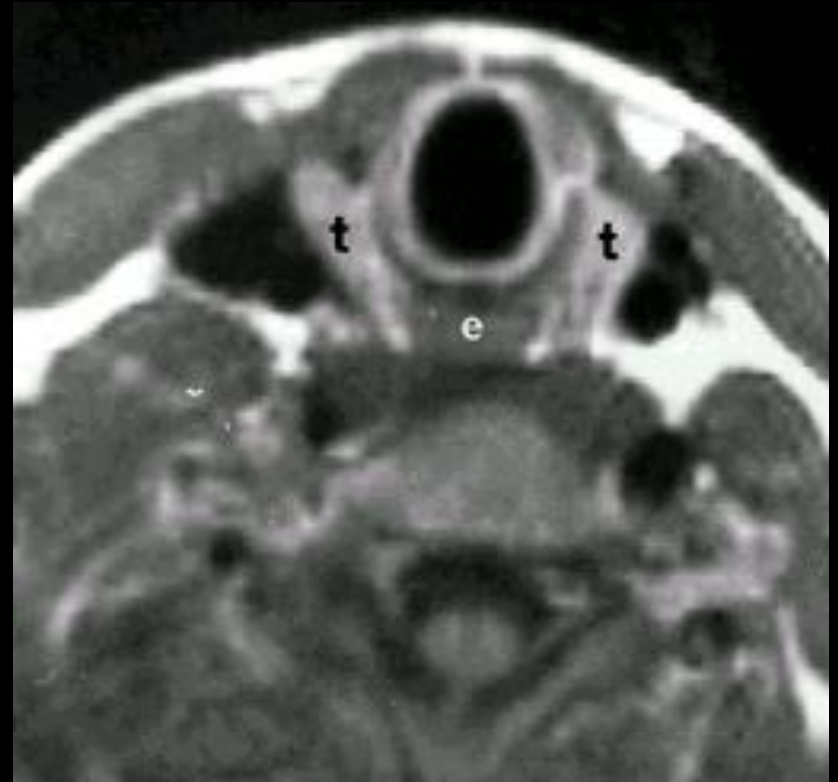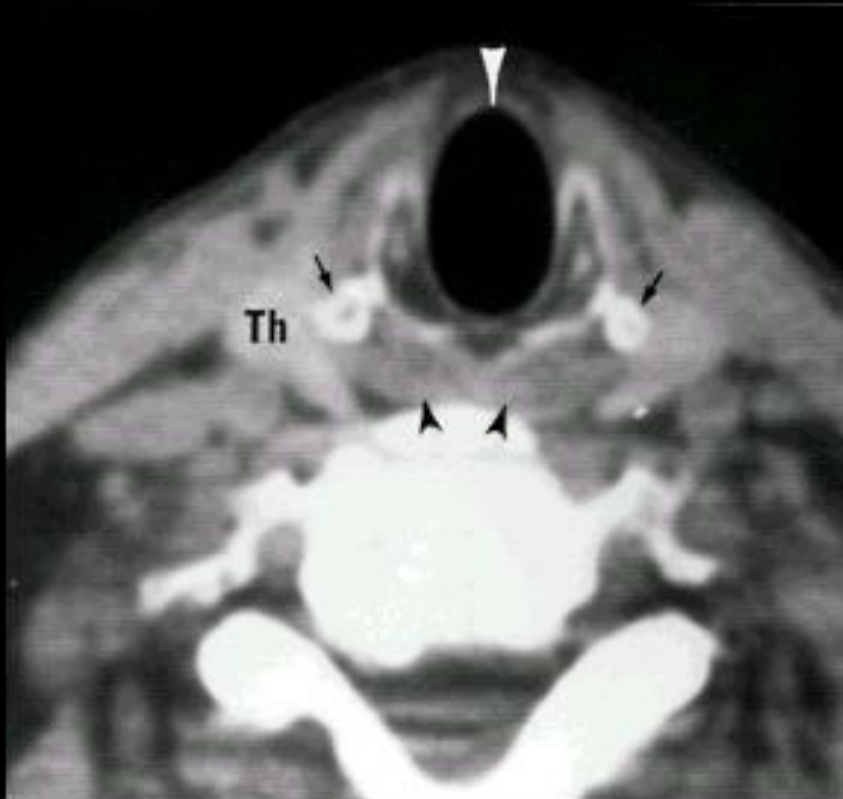
Yalancı vokal kordlar



Vokal prosesler, gerçek vokal kordlar

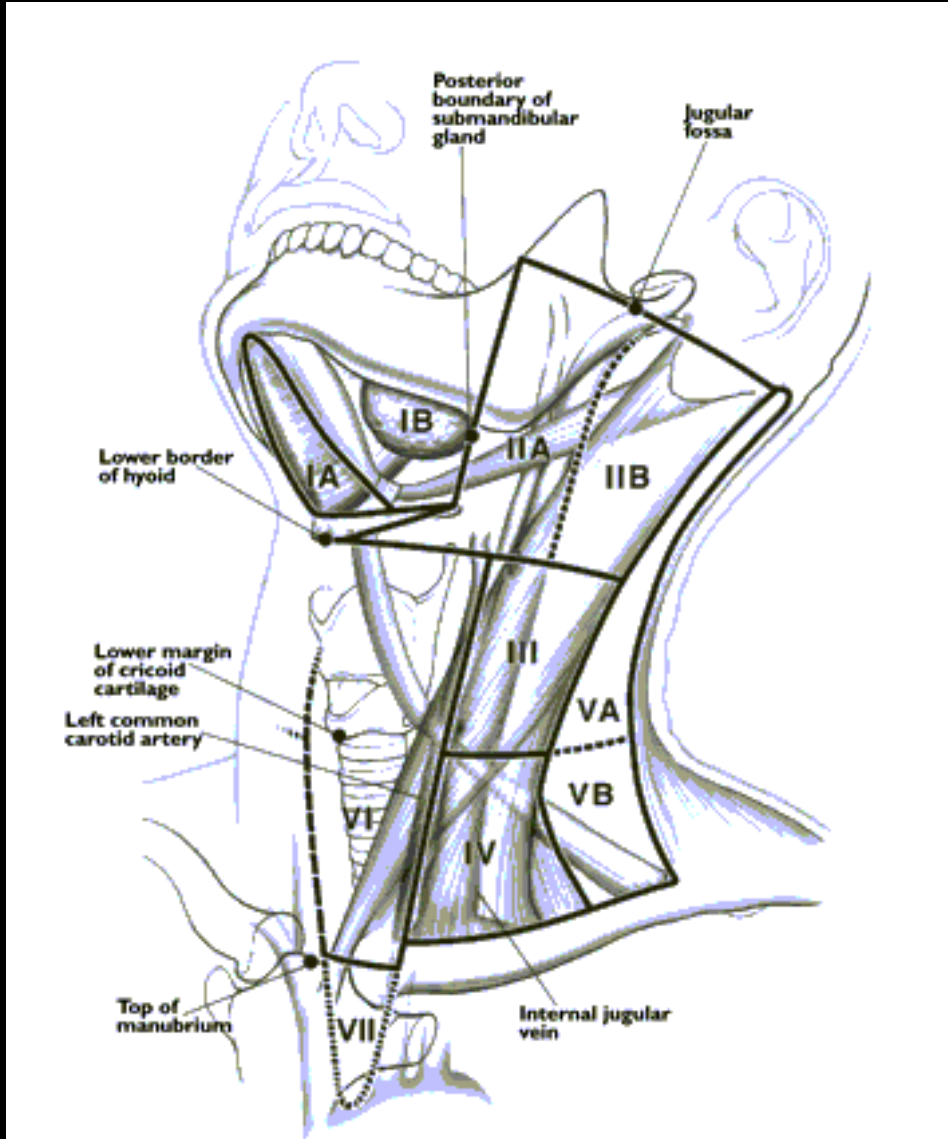


Krikotiroid eklem



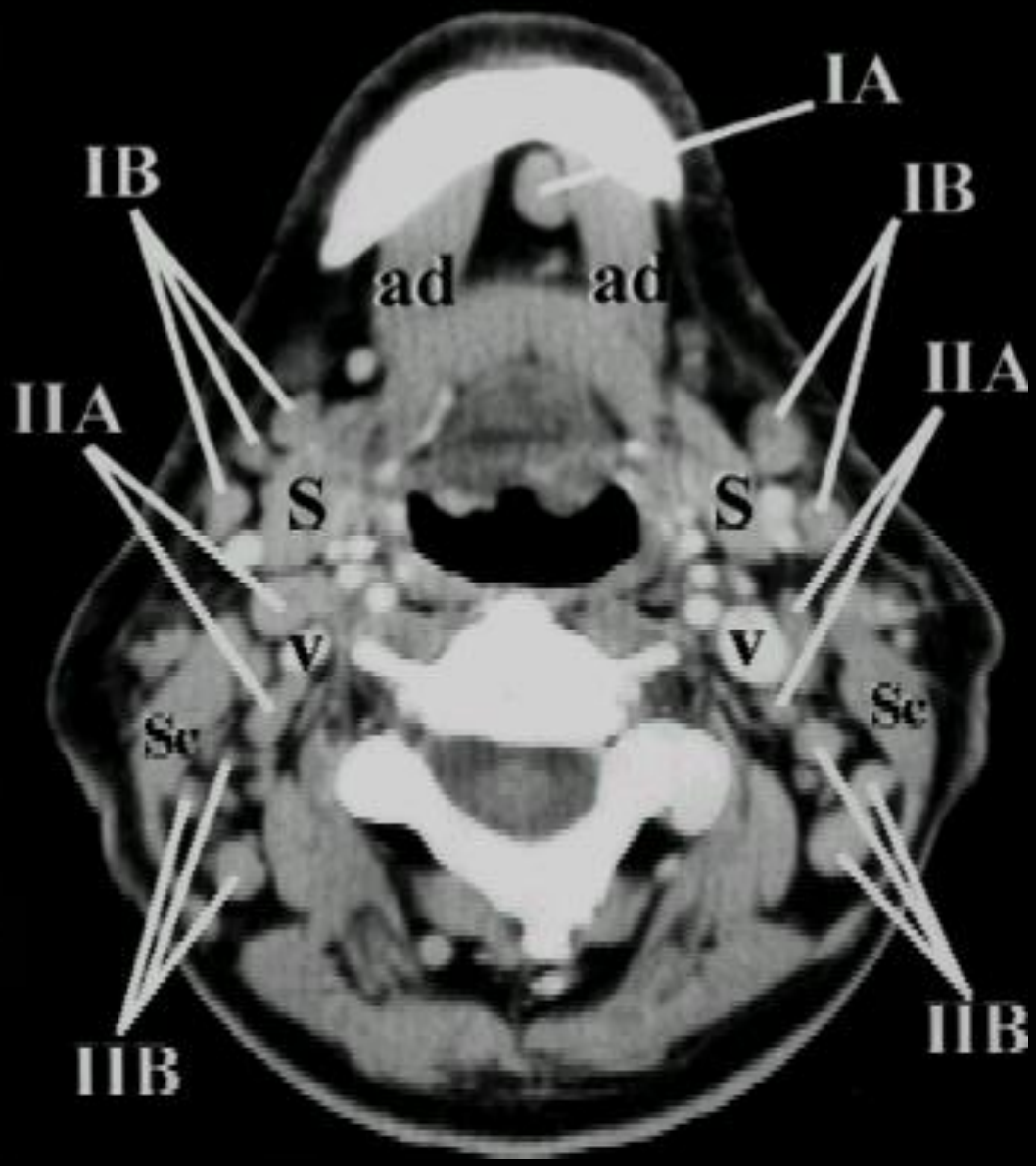
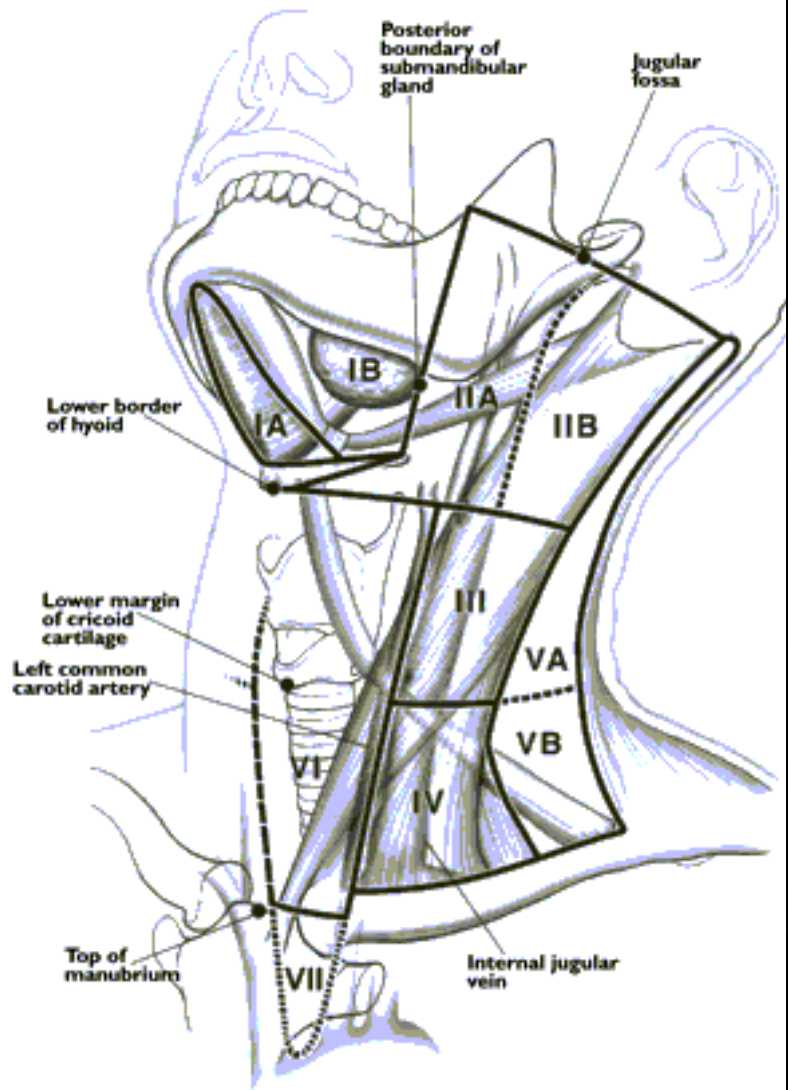
Krikotiroid membran

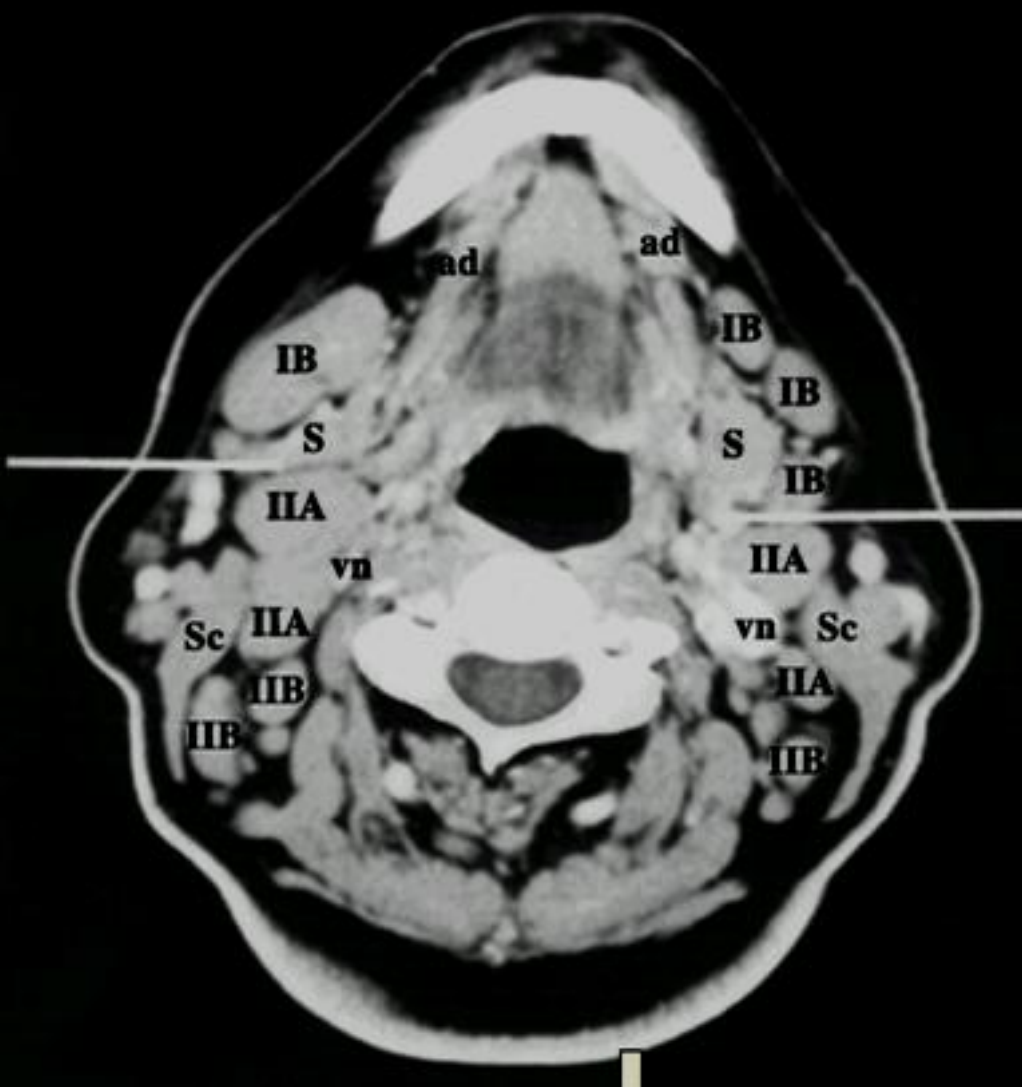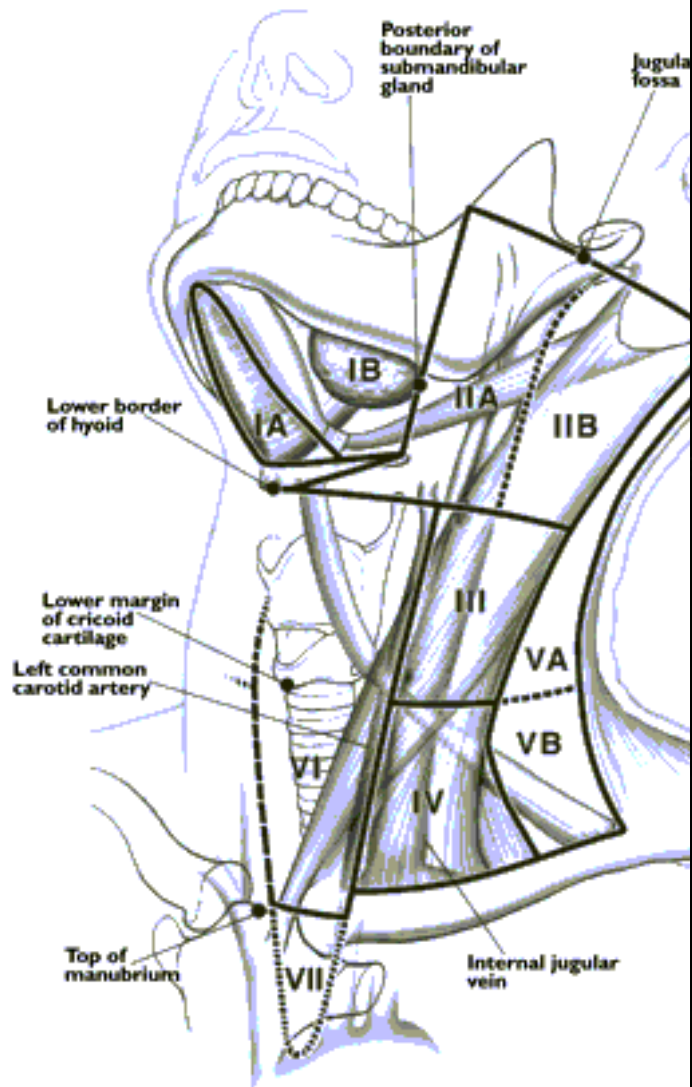


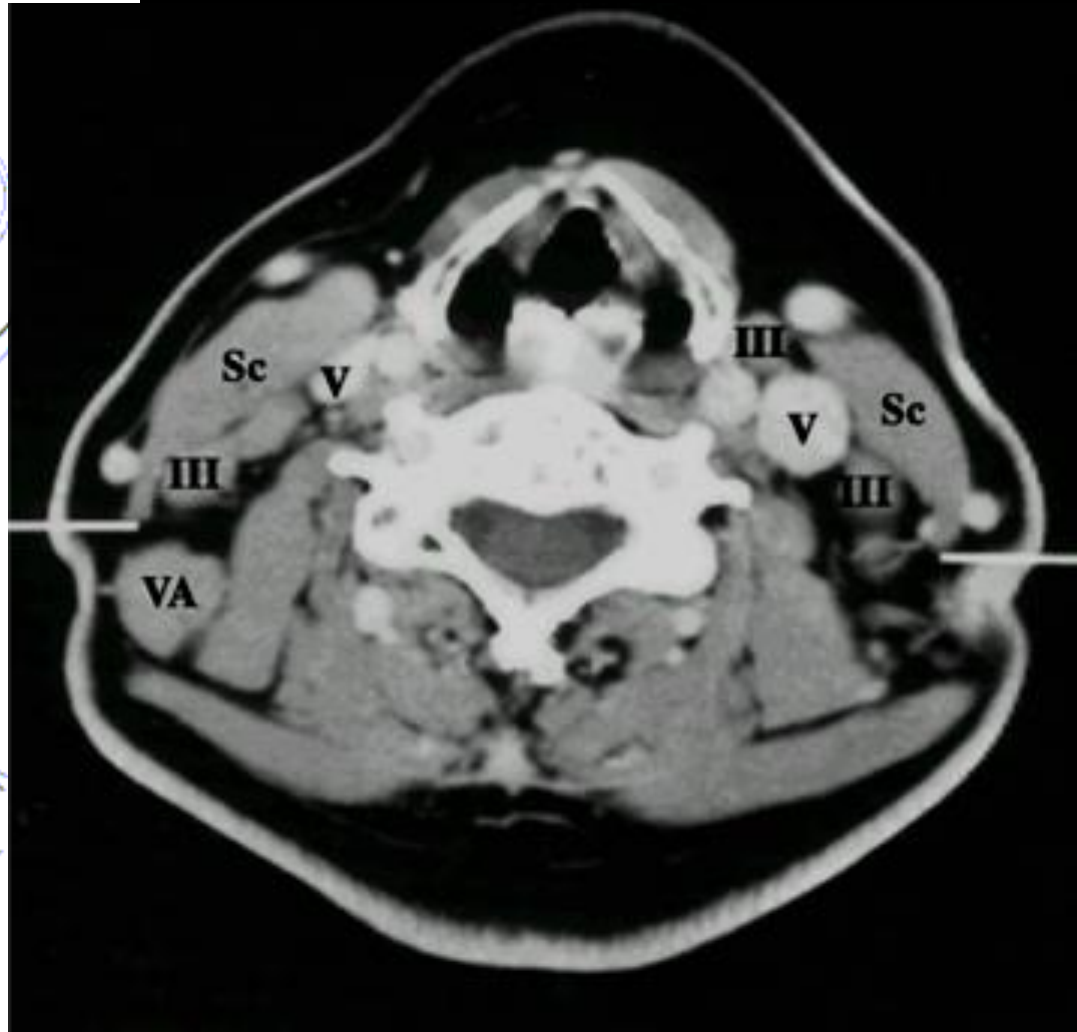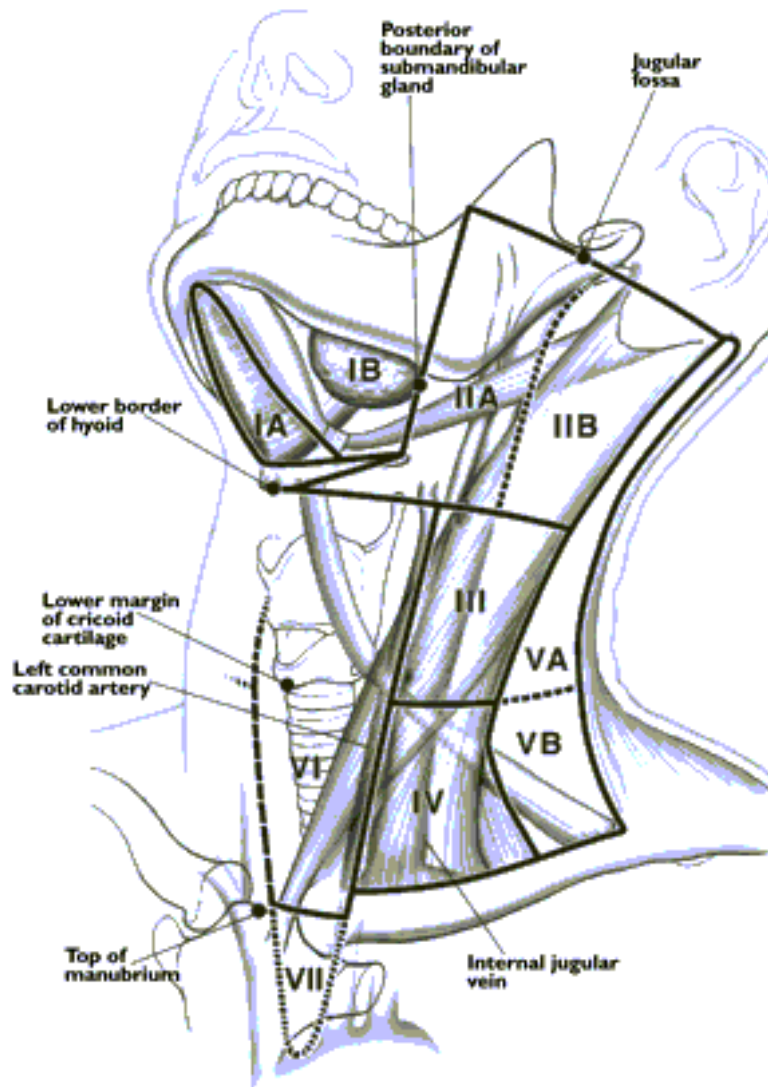


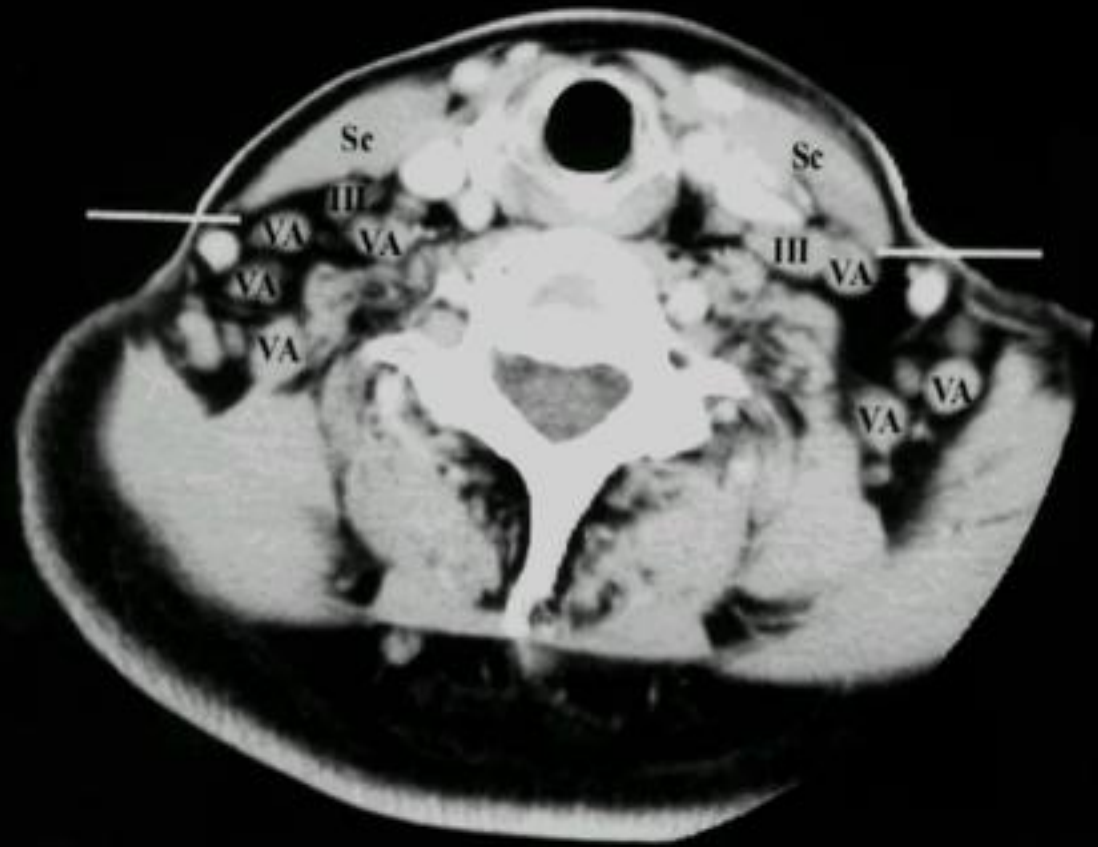
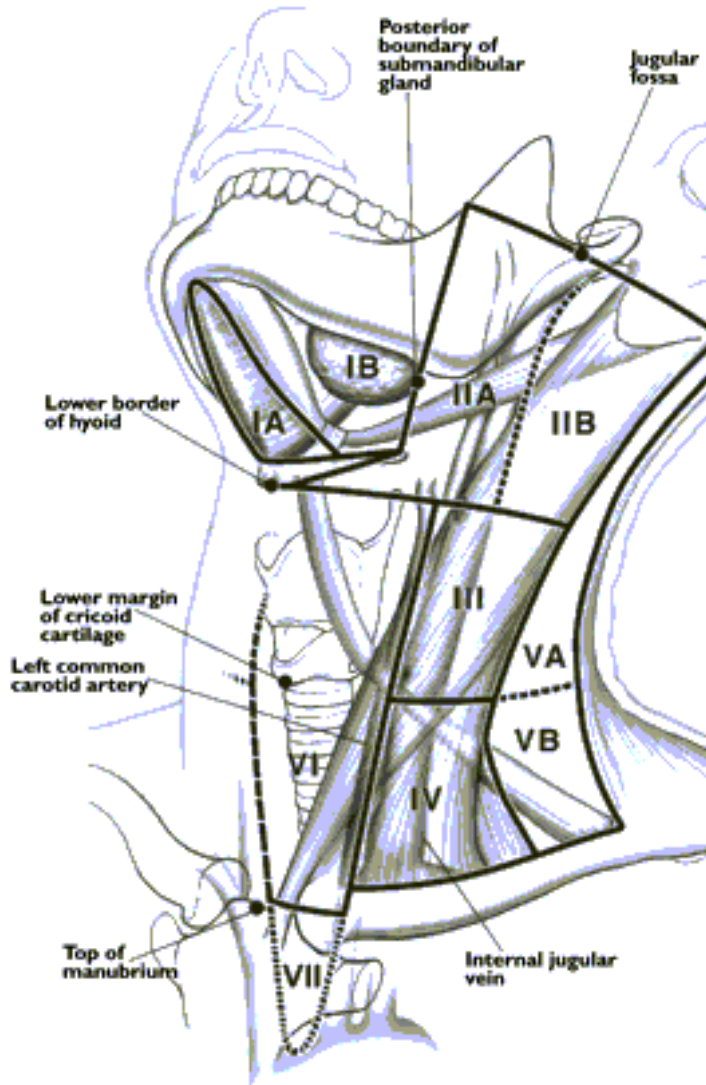
**AJCC 1997, AAO-HNS 1998**

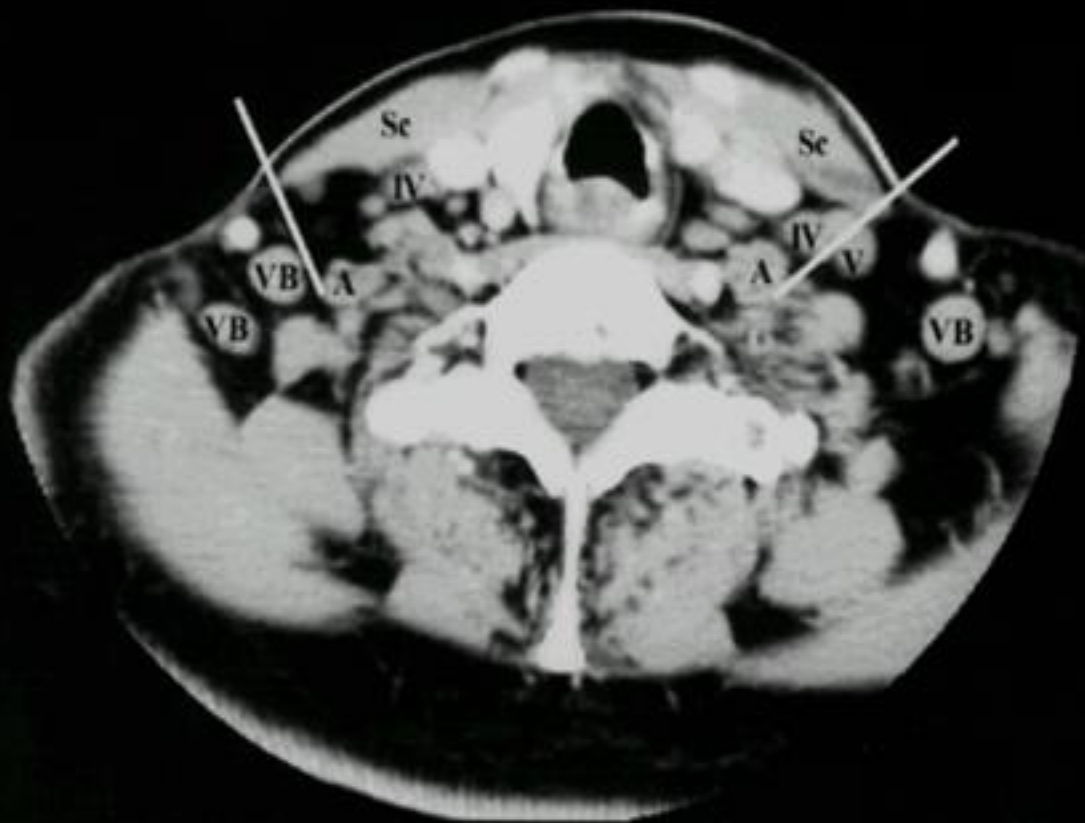
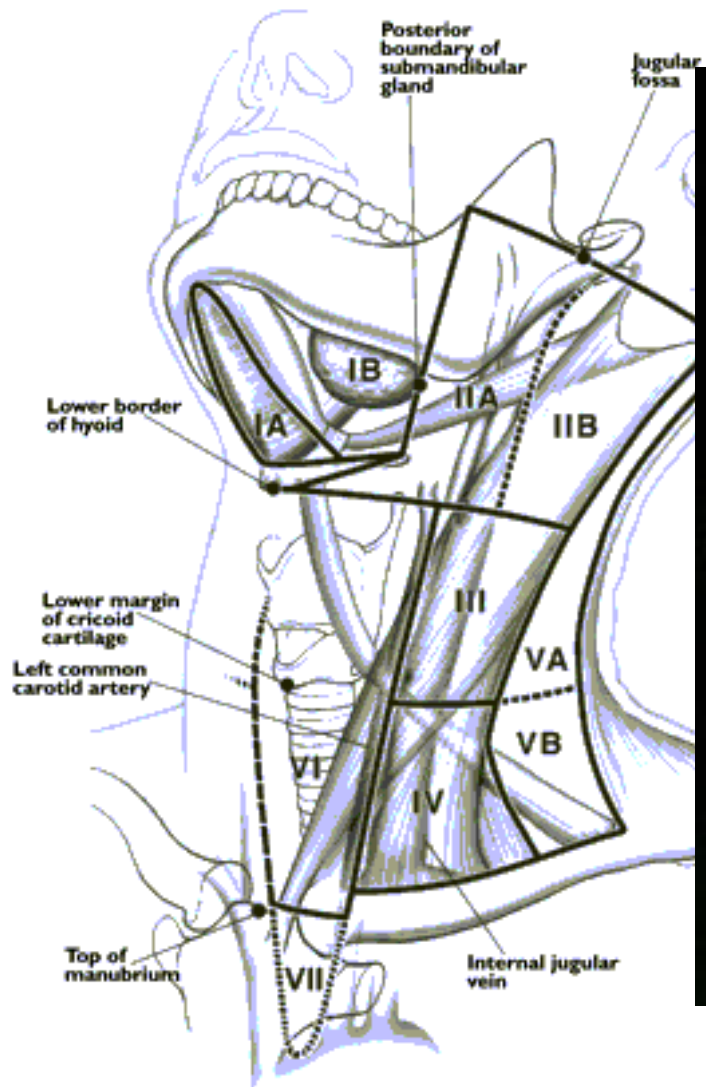
- I:** Submental, submandibuler
- II:** Üst juguler (jugulodigastrik)
- III:** Orta juguler
- IV:** Alt juguler
- V:** Posterior üçgen
- VI:** Anterior kompartman
- VII:** Üst mediastinal





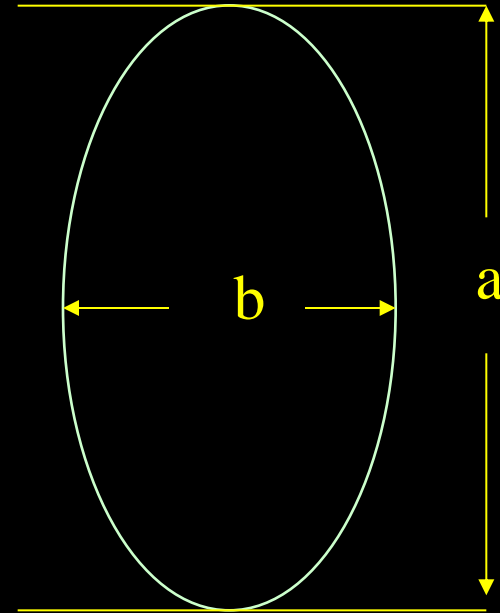






# Patolojik lenf nodu?

- **Boyut**
  - Maksimum çap
  - Minimum aksiyel çap



# Patolojik boyut

- Maksimum çap
- Jugulodigastrik bölge ( seviye II)  $> 15$  mm
- Submandibuler bölge (seviye I)  $> 15$  mm
- Diğer seviyelerde  $> 10$  mm
- (retrofaringeal bölgede  $> 8$  mm)

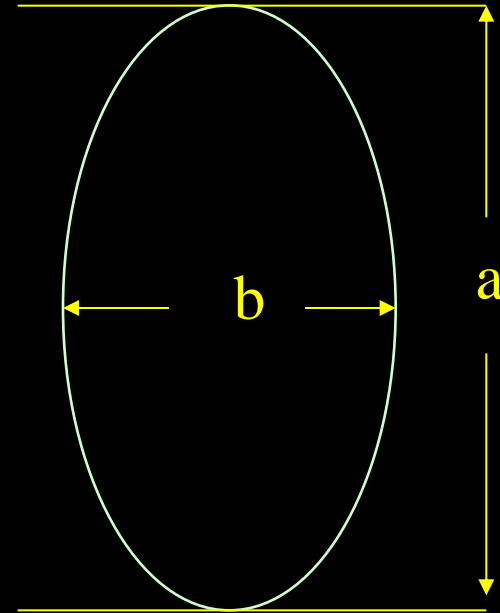


# Patolojik boyut

- Minimum çap
- Jugulodigastrik bölge ( seviye II)  $> 11$  mm
- Submandibuler bölge (seviye I)  $> 10$  mm
- Diğer seviyelerde  $> 10$  mm

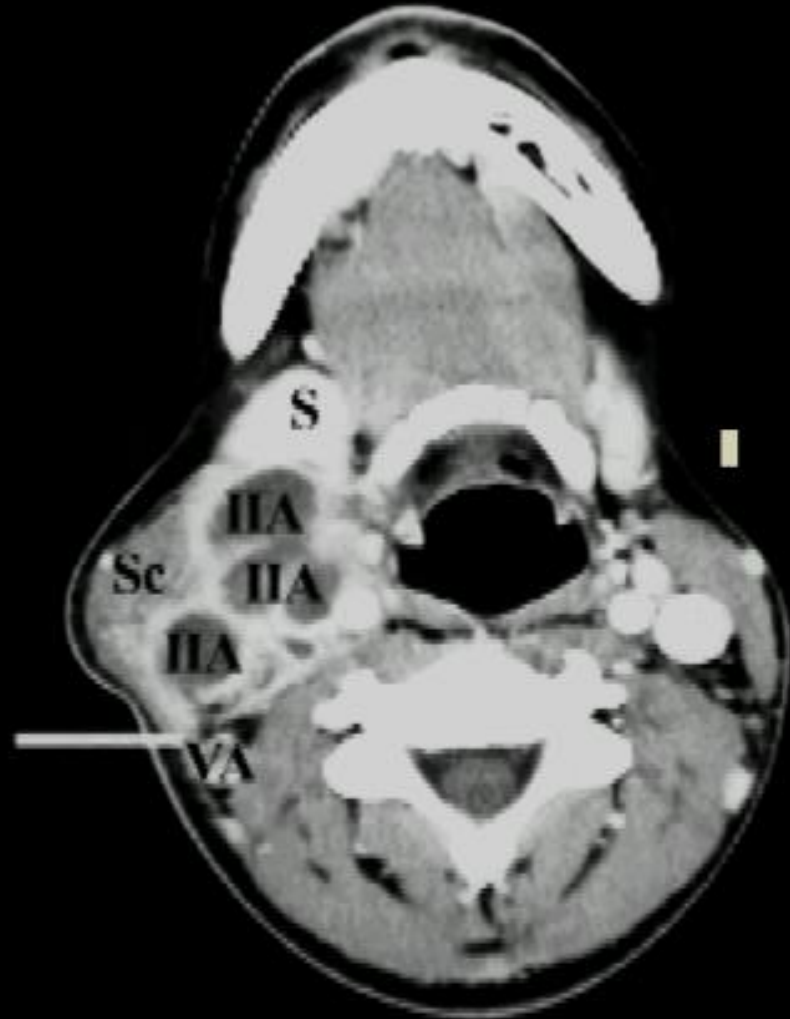# Patolojik lenf nodu?

- Şekil
  - Oval : Benign
  - Sferik: Malign



# Patolojik lenf nodu?

- Santral nekroz





?

